

Some observations from the past year

To the Editor

It is not in the interest of the individual leprosy patient that the WHO is trying to reach the goal of elimination of leprosy as a public health problem by the year 2005. They try to reach it by all means, but the number of new cases does not come down. The technical advisory group on elimination goes as far as blaming the leprosyworkers for this. These leprosyworkers could have inflated the number of new cases due to wrong diagnosis, re-registration of old cases, and even defining non-existing cases as patients'. How far can you go?

An important side effect of their efforts is a decline in knowledge about leprosy. This may lead to large problems for the individual leprosy patient since the specialised leprosy services are being dismantled and experienced leprosyworkers are employed elsewhere within the health service.

Continuing education is therefore adamant. In this respect a few experiences of the author during the past year are reported here.

Leprosy and HIV

Leprosy and HIV are in general not considered interacting, and most authors report that HIV has little or no effect on leprosy'. It was however considered that leprosy in HIV infected patients could be a downgrading form of leprosy, which only will be detected when the CMI (Cells Mediated Immunity), for instance under highly effective anti-retroviral therapy (HAART)³ or when due to the bulk of bacteria, infiltration and nodules appear.

Some authors indeed noticed that HAART therapy precipitated the diagnosis of leprosy and the occurrence of reversal reactions, moreover Mitsuda reactions became positive⁴.

It was assumed that, if there were unrecognised leprosy patients with HIV in the community the detected number in that community among HIV-negative could increase³. From the registers in Moshi area, Tanzania there was an indication that could be the case. But the area still counted as a low endemic area. Using an ELISA to detect antibodies against *M. leprae*'s phenolic glycolipid-1 (PGL-1) among the HIV-negative inhabitants of the Moshi area, it was found that the percentage of antibody positives was higher than expected for a low endemic area. This finding could support the notion that the pool of infective *M. leprae* is growing in Moshi area possibly due to patients with double infection leprosy (undiagnosed) and HIV⁵.

Most of the leprosy patients with a low CMI have MB leprosy. Clinically it is interesting to see how these patients present. The first leprosy patient with AIDS and leprosy that was described from the Netherlands, in 1990, had transitory borderline lesions that disappeared when the immune system further collapsed⁶. In Moshi, patients regular present with a type of leprosy similar to that was seen in Ethiopia in the mid 1970's in long time treated lepromatous patients, who became leprosy resistant and then presented with histoid nodules. Rounded papules and nodules in an area with or without diffuse infiltration (Figures 1A and 1B). It seemed that in that particular area *M. leprae* were multiplying unchecked. These long time treated Lepromatous leprosy (LL) patients had no CMI against *M. leprae*. A similar situation may exist in the pre-AIDS patients that were encountered in Moshi. For years I had not seen a leproma in the eye but they are present in a number of the co-infected leprosy/HIV patients in Moshi (Figure 2).

In 250 patients with AIDS the anti PGL-1 antibody ELISA test was done in order to detect current or past *M. leprae* infection. Contrary initially expected, the number of antibody positive's among the AIDS patients was much lower than among the healthy controls. This could be explained by assuming that when an HIV positive patient with immunodeficiency comes in contact with new antigens he does not respond normally. Hay did a similar observation for mycotic infections (personal communication). These observations show that a PGL-1 antibody test could well be unreliable as an epidemiological tool in HIV endemic areas⁵.

Leprosy like

A pitfall, which is well known, is the diagnosis of a patient with neurofibromatosis as one with leprosy. Usually such patient presents with papules and nodules and is confused with lepromatous leprosy. In the particular patient that was seen in Moshi this year, peripheral nerves were enlarged (Figure 3) and neuropathy with ulnar and median weakness and a beginning of a dropfoot were noticed. What gave the patient away was the slight proximal weakness present in his upper legs and his right shoulder probably due to compression of the motor neurones by Schwannomas in or near the spinal cord.

It is good to realise that the prognosis of a leprosy patient is much better.

HAART

In the Netherlands there were a few remarkable occurrences, the detection of a third co-infection leprosy/HIV patient, detected after the instigation of HAART and a patient induced doctors delay in diagnosing leprosy. Both patients were immigrants from leprosy endemic areas.

The first patient was diagnosed with HIV and started on HAART. After about 2 months when the viral load was declining he developed widespread hypopigmented lesions, some with an erythematous rim. Consequently he was sent to the department of dermatology where the tentative diagnosis BL leprosy was made. This was confirmed by biopsy. This evolution of leprosy in HAART treated HIV patients seems to become a regular occurrence.

Stigma

The second patient a female medical specialist married to a Dutch developed some paresthesia in the left middle finger and later some weakness of the hypothenar and pain at the wrist. She was sent to a neurologist who did an electrophysiological assessment and concluded that the patient suffered from a carpal tunnel syndrome and prescribed rest and a splint. This seemed to help in the beginning but the complaints increased when the patient was towards the end of pregnancy and a release operation was planned. After delivery the patient developed more pain and weakness and an erythematous infiltrated middle finger, with loss of sensation (Figure 4). The attending family practitioner sent her to a dermatologist, who thought of mucinosis. A biopsy was

taken. The pathologist saw a granulomatous infiltrate but could not make a definite diagnosis. Consequently the patient was sent to a specialised university clinic for imported dermatoses. There immediately she was asked: "you are physician coming from a leprosy endemic area, sure you must know what you have". The answer was "I knew it was leprosy, but I was sure I could not have it, since I come from a good family without leprosy". "Why did you go along with all the wrong diagnoses, and did not tell that you thought it was leprosy". "I was so glad that there could be another explanation, and to ashamed to voice my suspicion, I come from a good family!" The diagnosis was easy to make: loss of sensation in the lesion and, moreover, the presence of an even visibly thickened median nerve.

Acknowledgement

Agradeço ao Instituto Lauro de Souza Lima pela habitual hospitalidade e ao Gastmann-Wichers Stichting pelo suporte financeiro anual para traslado.

Naafs B¹

¹ MD. PhD. Dermatovenereologist. IJsselmeerziekenhuisen Emmeloord/Lelystad and Leiden University Medical Center (LUMC Leiden The Netherlands. Regional Dermatology Training Center (RDTC) at IGLimanjaro Christian Medical Center (KCMG) Tumaini University, Moshi, Tanzania and Instituto Lauro de Souza Lima (ILSL) Bauru/SP/Brasil.
Correspondence address: Cracht 15, 8485KN Munnekeburen. The Netherlands. benaafs@dds.nl

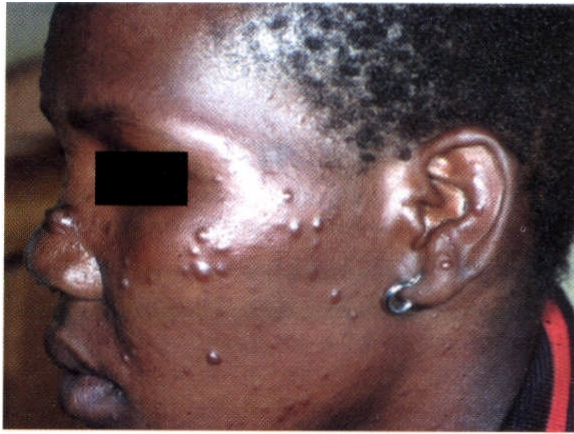

Figure 1A. Histoid leprosy.
Figura 1A. Hanseníase históide.

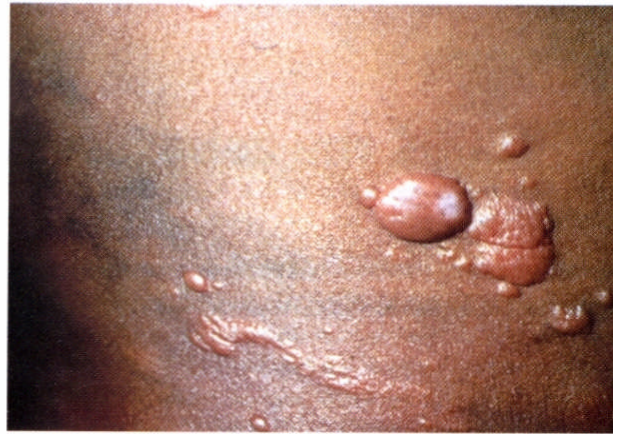

Figure 1 B. Histoid leprosy.
Figura 1B. Hanseníase históide.

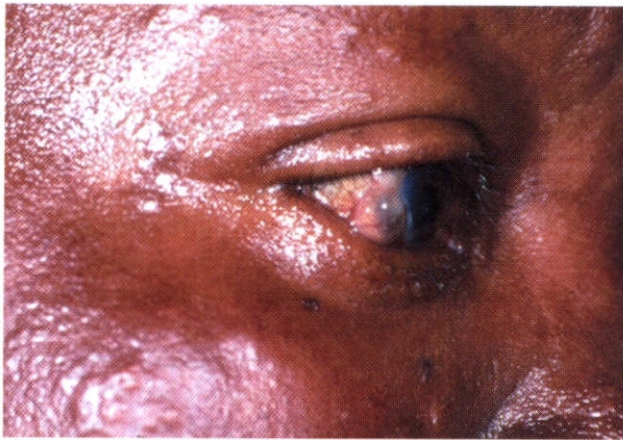


Figure 2. Leproma in the eye.
Figura 2. Hansenoma no olho.

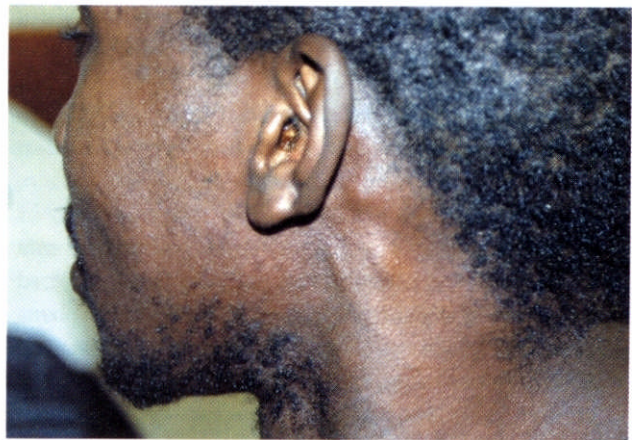

Figure 3. Enlarged cervical nerves.
Figura 3. Espessamento de nervo cervical.

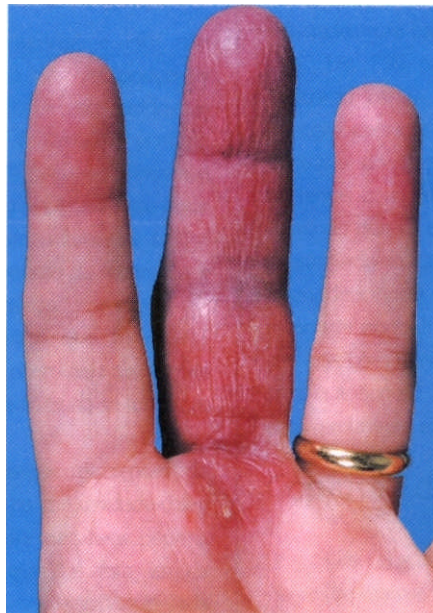

Figure 4. Erythematous infiltrated middle finger.
Figura 4. Dedo médio infiltrado e eritematoso.

References

- 1 World Health Organization. Report on sixth meeting of the WHO technical advisory group on the elimination of leprosy. WHO/CDS/CPE/CEE 2004; 41:23.
- 2 Nery JAC, Sampaio ER Galhardo MCG, Perissé ARS, Vieira LMM, Salles AM, Sarno ENM. Leprae-HIV co-infection: Patterns of immune response in vivo and in vitro. *Indian J Leprosy* 2000; 72:155-167.
- 3 Naafs B. Leprosy and HIV: an analysis. *Hansenfase e HIV: uma análise. Hansen int* 2000; 25:60-66.
- 4 Trindade MAB, Penteadó MM, Masetti JH, Leite MA, Takahashi MDF, Naafs B. Leprosy and HIV co-infection in five patients: a retrospective study. Submitted for publication.
- 5 Zewde A, Masenga J, Grossmann H, Oskam L, Naafs B. Influence of the HIV epidemic on Leprosy prevalence. Paper at the 2nd Scientific Meeting of United Streams, May, Amsterdam, the Netherlands, 2004
- 6 Kennedy C, Chin-A-Lien RAM, Stolz E, Van Joost TH, Naafs B. Leprosy and immunodeficiency virus (HM) infection. A closer look at the lesions. *Int J Dermatol* 1990; 29:685-688.