

# INTERNATIONAL JOURNAL OF LEPROSY

## And Other Mycobacterial Diseases

VOLUME 46, NUMBER 1

JANUARY-MARCH 1978

### Liver Lesions in Experimental Lepromatoid Leprosy of the Armadillo. A Histopathologic Study<sup>1</sup>

C. K. Job, W. F. Kirchheimer and R. M. Sanchez<sup>2</sup>

It is well known that experimental infection of nine-banded armadillos (*Dasypus novemcinctus* Linn.) with *M. leprae* causes disseminated leprosy in a variable proportion of animals depending on the size and route of injection of the inoculum (<sup>3</sup>).

The histopathologic and bacteriologic autopsy findings are similar to those in lepromatous human beings but involve a greater variety of organs which, in addition, carry a greater bacterial load (<sup>4</sup>).

In this paper a retrospective study of liver lesions was made in seven male and six female armadillos infected intracutaneously and simultaneously with  $10^7$  *M. leprae* H (derived from human lepromas) from the same inoculum, to evaluate the pathogenesis of the experimental disease.

#### MATERIALS AND METHODS

Liver sections of the 13 autopsied armadillos, stained with hematoxylin and eosin and acid-fast stain, were studied. All 13 armadillos were mature wild-caught animals of unknown age. The autopsies were made within 55 months after experimental infection. Six of the thirteen armadillos died spontaneously and seven were sacrificed because they appeared to be in terminal condition.

For the purposes of this study the animals were divided into two groups. In one group the lesions due to *M. leprae* were not so extensive that death could be attributed to the lesions. In the second group the lepromatoid lesions were so widespread that it was reasonable to assume that the disease contributed to the death or the serious illness in these animals.

#### RESULTS

**Group I.** There were seven animals in the first group, three females and four males. The period of survival following inoculation with *M. leprae* varied from as short a period as 13 months to 55 months.

The histopathologic appearances of all seven animals except number 31 had a close

<sup>1</sup>Received for publication 12 December 1977.

<sup>2</sup>C. K. Job, B.Sc., M.D., F.A.M.S., F.R.C.Path., Professor and Head, Department of Pathology, Christian Medical College-Hospital, Vellore 632004, Tamil Nadu, India and Consultant Pathologist, Schieffelin Leprosy Research and Training Center, Karigiri, North Arcot District, Tamil Nadu, South India; W. F. Kirchheimer, M.D., Ph.D., Chief, Laboratory Research Branch, and R. M. Sanchez, B.S. (Microbiol.), Research Microbiologist, Microbiology Research Department, Laboratory Research Branch, USPHS Hospital, Carville, LA 70721.

resemblance. The architecture of the liver was normal. The liver cells showed no fatty degeneration or other obvious pathologic changes. There were scattered infiltrations of the liver tissue by lymphocytes, a few plasma cells and macrophages, and in some there were small focal collections of these cells (Fig. 1). Well marked congestion, mostly in the center of the lobule, was seen in three animals.

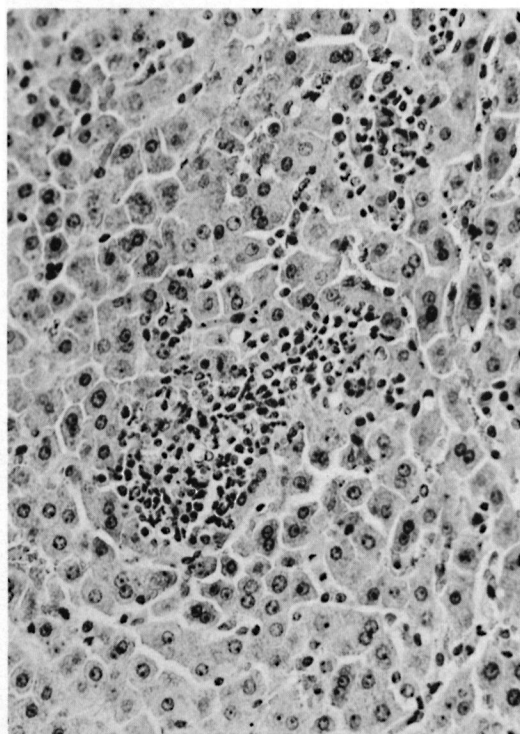


FIG. 1. Liver tissues showing small focal collections of round cells, most of which are lymphocytes. (H & E,  $\times 200$ )

Acid-fast stain showed bacilli inside Kupfer cells (Fig. 2) and macrophages. Many of the liver cells also contained bacilli; in most there were only a few organisms but in a few there were large numbers (Figs. 3, 4).

In animal 31 there was a marked increase in the inflammatory reaction. Several lobules were infiltrated by numerous lymphocytes (Fig. 5). Individual liver cells and small groups of them were surrounded and infiltrated by several lymphocytes (Fig. 6). There were periportal areas of hemorrhagic necrosis infiltrated by neutrophil polymorphs. Acid-fast bacilli were present in many of the liver cells.

**Group II.** There were six animals in Group II, of these three were females and three males. The period of survival following inoculation with *M. leprae* varied from 17 to 55 months.

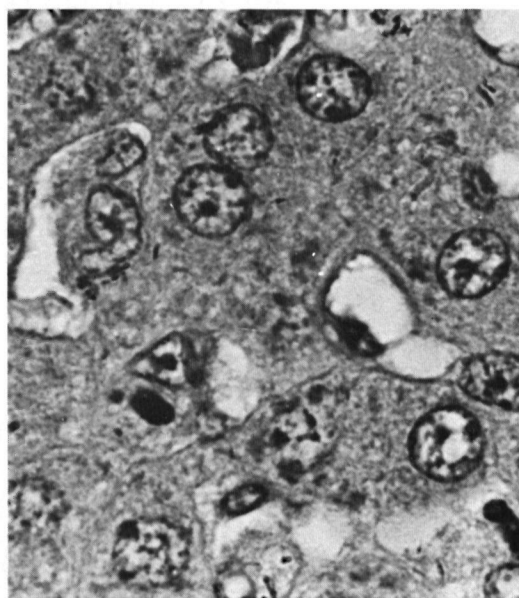


FIG. 2. Kupffer cells containing many acid-fast organisms. (Acid-fast stain counterstained with hematoxylin,  $\times 1250$ .)

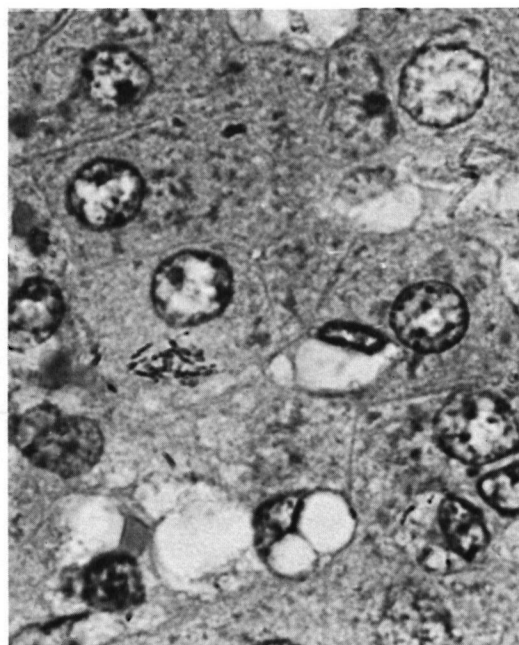


FIG. 3. A liver cell containing a small clump of acid-fast bacilli. (Acid-fast stain counterstained with hematoxylin,  $\times 1250$ .)

TABLE 1. *Period of survival in Group I.*

Armadillo no.	Sex	Period of survival after inoculation (months)	Dead or sacrificed
39	F	13	Found dead
16C	F	26	Found sick & sacrificed
31	F	33	Found dying & sacrificed
27	M	36	Found sick & sacrificed
30	M	39	Found dead
43C	M	40	Found dead
28	M	55	Found sick & sacrificed

TABLE 2. *Period of survival in Group II.*

Armadillo no.	Sex	Period of survival after inoculation (months)	Dead or sacrificed
38	F	17	Found dead
15C	M	27	Found dead
29	M	36	Found sick & sacrificed
18	F	37	Found dead
25	F	37	Found sick & sacrificed
5	M	55	Found sick & sacrificed

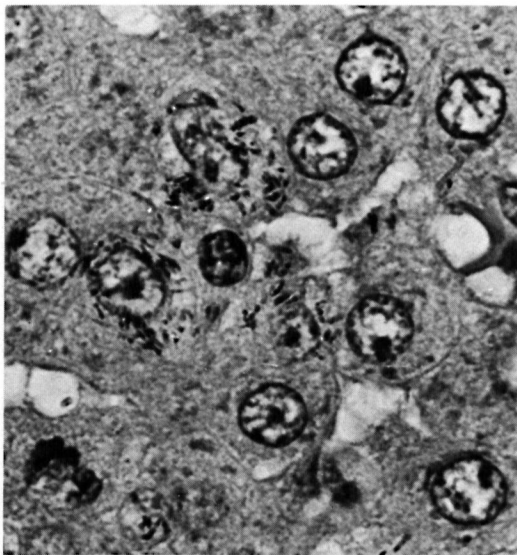


FIG. 4. Many liver cells packed with acid-fast organisms. (Acid-fast stain counterstained with hematoxylin,  $\times 1250$ .)

The architecture of the liver was essentially normal in all animals. Many liver cells were swollen and the cytoplasm of some of them were pale and granular (Fig. 7). Kupfer cells were prominent throughout the section (Fig. 8). Numerous collections of macro-

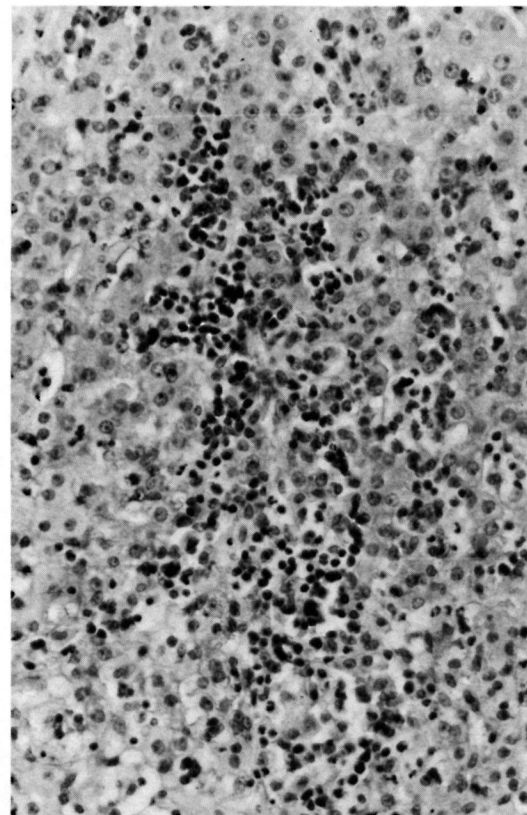


FIG. 5. Liver lobule infiltrated by large collections of lymphocytes. (H & E,  $\times 200$ )

phages infiltrated the liver lobules without any special site of predilection. The liver cells surrounding these collections showed evidence of pressure atrophy. The macrophages had a pale granular cytoplasm and were indistinguishable from some of the liver cells (Fig. 9). Foamy degeneration of macrophages and liver cells was also seen (Fig. 10).

The lesions in the animal at 55 months were obviously more extensive than in the one at 17 months. However, there was no significant difference between the extent of lesions at 27 months and 55 months. Foamy change of the affected cells was noticed as early as 17 months and was well marked at 55 months. In some animals few liver cells were binucleated and variation in size of the nuclei was also seen. However, there was no nodular regeneration or fibrosis.

Acid-fast stain showed that the macrophages, Kupffer cells and the swollen, pale, granular liver cells were packed with bacilli.

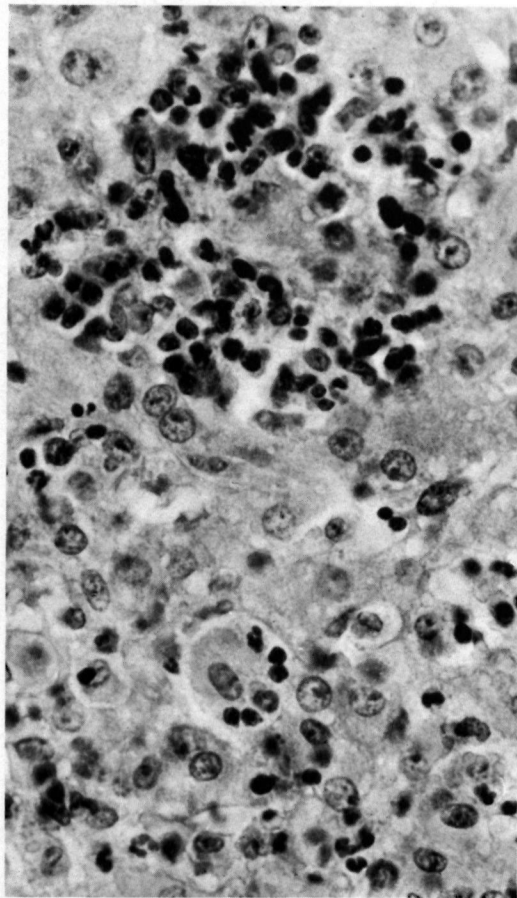


FIG. 6. Individual liver cells and groups of them are infiltrated by numerous lymphocytes. (H & E,  $\times 500$ )

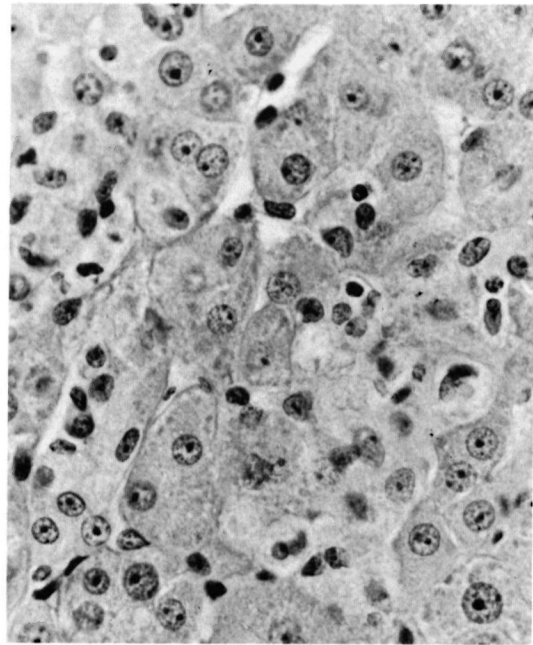


FIG. 7. Liver tissue showing a small group of cells with pale granular cytoplasm. (H & E,  $\times 500$ )

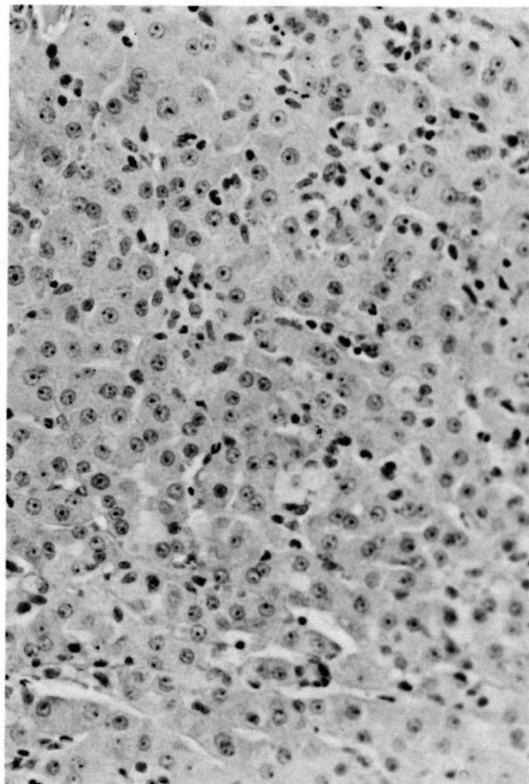


FIG. 8. Liver section showing prominent Kupfer cells throughout the tissue. (H & E,  $\times 200$ )

Many of the other liver cells also contained bacilli but in much smaller numbers.

In three animals there were focal collections of neutrophil polymorphs situated in areas where there were collections of macrophages. Some of these were very small and others were large enough to form microabscesses. In animal 29, there was well marked vasculitis of several hepatic veins with deposition of protein in the vessel wall and infiltration by numerous neutrophil polymorphs (Fig. 11). In some instances there was destruction of the vessel wall itself (Fig. 12) with extravasation of red blood cells. Acid-fast stain showed bacilli inside macrophages, Kupffer cells and liver cells, but they were fewer at the sites of microabscesses.

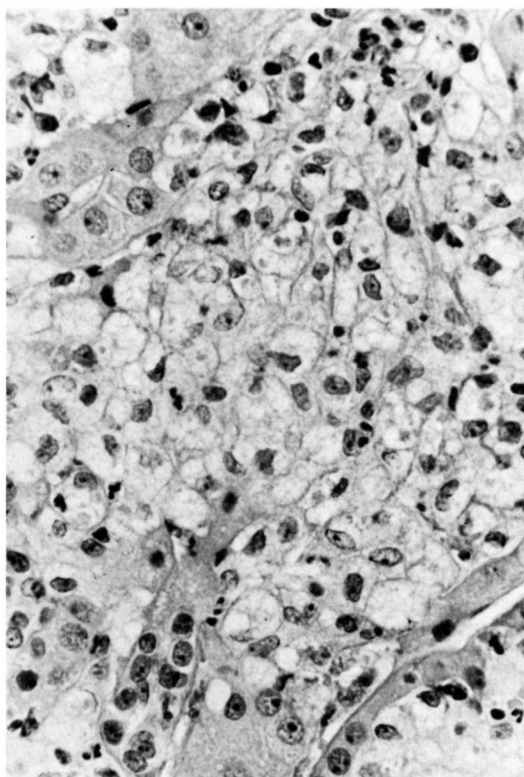


FIG. 9. Liver tissue with extensive areas of foamy degeneration of liver cells and macrophages. (H & E,  $\times 500$ )

### DISCUSSION

Several interesting observations emerge from this study. All the 13 animals infected intracutaneously with  $10^7$  *M. leprae* and examined at autopsy showed definite evidence of generalized infection with proliferation of *M. leprae* in liver cells.

The reaction of the animals to the infection varied considerably. The extent of the disease in the liver did not depend on the length of time after the infection. Two distinctive groups were identified; one in which the infection was less evident and the number of bacilli in macrophages and in liver cells was smaller. There was no obvious change in the liver tissue except for the round cell infiltration and prominent Kupffer cells which contained *M. leprae*. This picture remained the same whether the period of infection was 13 months or 55 months. These lesions can be compared to indeterminate leprosy in humans.

In the other group of animals there was swelling of a number of liver cells which developed as a pale granular cytoplasm. There were also increasing numbers of macrophages infiltrating the liver tissue. As the period of infection advanced a significant portion of the normal liver tissue was replaced by bacilliferous macrophages and liver cells. Their bacillary content was considerable. Although there was an increase in the number of cells containing bacilli from the 17th month to the 27th month, there was not much change from the 27th month to the 55th month. Foamy change was seen as early as 27 months but was well marked at 55 months. Since there was so much difference in the number of bacilliferous cells in the

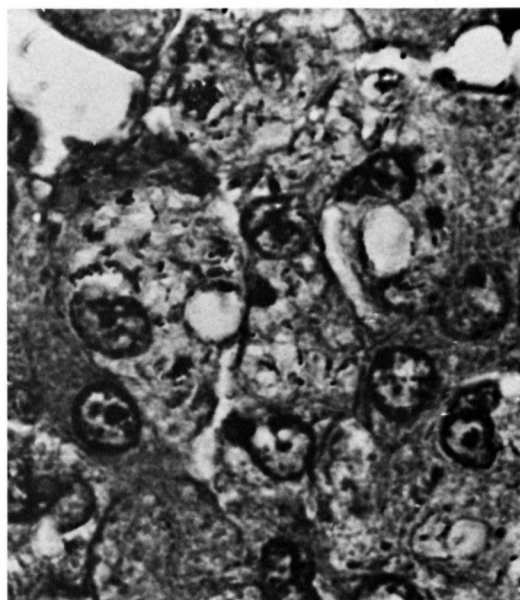


FIG. 10. Liver cells with acid-fast bacilli showing foamy degeneration. (Acid-fast stain counterstained with hematoxylin,  $\times 1250$ .)

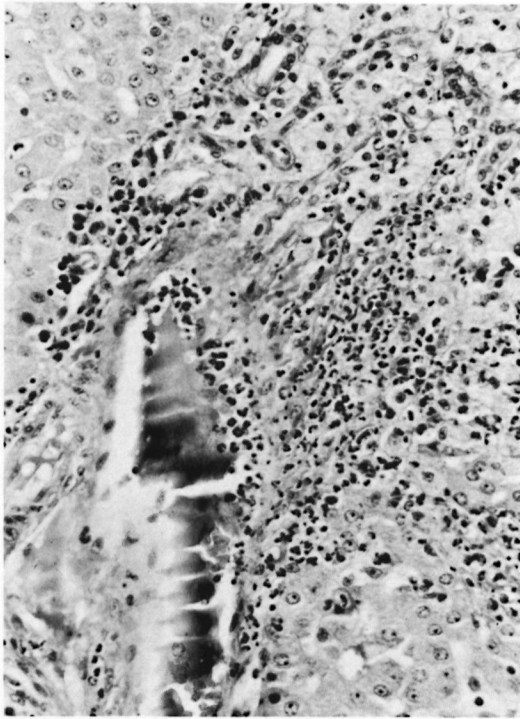


FIG. 11. Vasculitis involving a hepatic vein. Note the infiltration of the vessel wall from both sides by neutrophils. (H & E,  $\times 200$ )

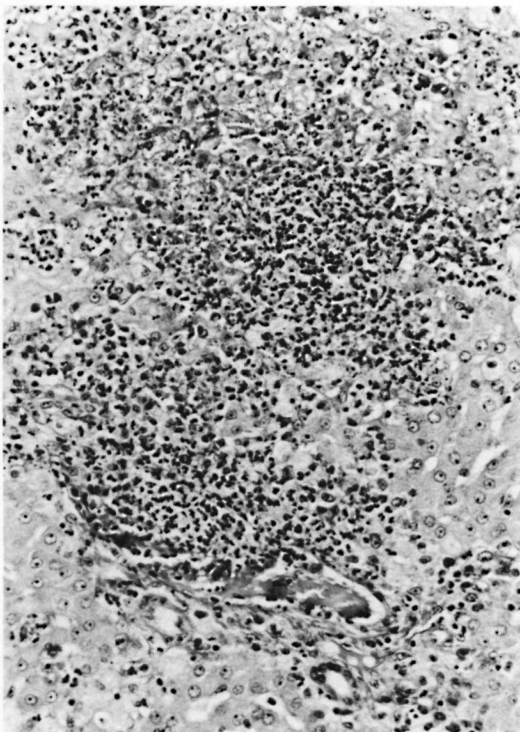


FIG. 12. Hepatic vein is seen almost completely destroyed by polymorphs and an adjacent microabscess. (H & E,  $\times 200$ )

livers of these two groups of animals it is reasonable to state that one group of animals was much more susceptible to the leprosy bacillus than the other group. This confirms an earlier report by Kirchheimer and Sanchez (2). The 13 autopsied armadillos belonged to a group of 16 animals infected simultaneously with the same number of *M. leprae* and by the same route. Three of these animals are still alive after more than five years. One of the survivors has signs of disseminated leprosy and the other two have no detectable sign of leprosy. Such observations in other groups of armadillos have been reported by Kirchheimer *et al* (3), and are thought to reflect differences in susceptibility.

The lesion in the lepromatoid armadillo liver was initiated in Kupffer cells. Later, large collections of bacillated macrophages infiltrated the liver lobules. In addition, liver cells were invaded by the organism and they developed a pale granular cytoplasm which became foamy in the late lesions. This picture is quite different from that seen in humans where the organism does not invade the liver cells. In the human liver lesion there are focal collections of infected macrophages containing varying numbers of bacilli. These granulomata never become larger than 1-2 mm in size. Foamy degeneration is a very prominent change in the cytoplasm of these macrophages. Perhaps because of the higher temperature of the liver cells in humans, *M. leprae* do not invade and grow in these cells in man. It should be pointed out here that *M. leprae* grow in spermatogonia, the parenchymatous cell of the testis in humans where the temperature is lower than that of the body. Foamy change of any infected cell which supports the growth of *M. leprae*, as pointed out by Binford *et al* (1), depends on the duration of the infection.

Neutrophil polymorphs are seen to infiltrate lepromatous granulomas in *erythema nodosum leprosum* (ENL) in humans and ENL lesions have been described in skin, lymph nodes, nerves, eyes and joints. In three of the six lepromatoid armadillo liver lesions studied, there were neutrophils infiltrating areas of bacillated macrophages and liver cells, producing microabscesses. In one, there was well marked vasculitis as described in ENL in humans. Although a pyogenic infection may produce infiltration by polymorphs, the histopathology of the liver

lesion is what one expects in an Arthus reaction. Therefore, we would like to suggest that ENL lesions occur in the lepromatoid armadillo just as in lepromatous humans and the pathogenesis of the lesions in both could be the same. It is also interesting to suggest that the target organ in experimental armadillo leprosy is the liver as compared to the skin in human leprosy.

In animal 31, there was hemorrhagic necrosis of the liver cells and infiltration by many lymphocytes and some neutrophil polymorphs. The lymphocytes are seen to infiltrate individual or groups of liver cells which contain *M. leprae*. This pathologic reaction could be an attempt on the part of the body to control the progress of the disease described as "reversal reaction."

In this study there were six females and seven males and there were no differences in the intensity and the extent of the disease between the two sexes.

It is interesting to note that the period of survival in both groups of animals, those with the indeterminate form of the disease and those with the lepromatoid type of the disease, was similar. The ages of these animals at the time of infection were not known. Although the lepromatoid disease would certainly have shortened their life span, the indeterminate lesion may not have. Therefore, the leprosy of the armadillos may not be the sole cause of death. It is quite possible that leprosy in armadillos, as in man, shortens life but may not be the primary cause of death.

### SUMMARY

A retrospective study of liver lesions was made in 13 armadillos infected intracutaneously with  $10^7$  *M. leprae* from the same inoculum, to evaluate the pathogenesis of the experimental disease. Survival times ranged from 13 to 55 months. In seven armadillos the liver lesions were markedly less severe than in six of these animals. The extent of the lesions was unrelated to the duration of the infection and was interpreted as reflecting individual differences in resistance. In contrast to man, leprosy bacilli were found in the liver cells of both groups of armadillos but to a lesser extent in those of the more resistant armadillos. The latter also had no obvious changes in the liver tissue except for round cell infiltration and promi-

nent Kupffer's cells which contained *M. leprae*. These lesions can be compared to indeterminate leprosy in humans.

The lesions in the more susceptible (lepromatoid) armadillos were initiated in Kupffer's cells. Later, large collections of bacillated macrophages infiltrated the liver lobules. The liver cells heavily loaded with *M. leprae* developed a pale granular cytoplasm which became foamy in the late lesions. In three of the lepromatoid livers, lesions compatible with *erythema nodosum leprosum* were seen.

### RESUMEN

Se hizo un estudio retrospectivo de las lesiones hepáticas en 13 armadillos infectados simultáneamente por la vía subcutánea con  $10^7$  *M. leprae*. Los tiempos de supervivencia variaron de 13 a 55 meses. Seis armadillos tuvieron lesiones hepáticas muy severas. El grado de severidad no estuvo relacionado con el tiempo de infección y se interpretó como el reflejo de las diferencias individuales en resistencia. En contraste a lo que sucede en el humano, se encontraron bacilos de la lepra en las células hepáticas de ambos grupos de armadillos aunque los bacilos fueron menos frecuentes en los armadillos más resistentes. Estos últimos tampoco mostraron cambios obvios en el tejido hepático excepto por una infiltración de células redondas y por la presencia de células de Kupffer prominentes infectadas con bacilos de la lepra. Estas lesiones pueden compararse a las de la lepra indeterminada de los humanos.

Las lesiones en los armadillos más susceptibles (lepromatoides) se iniciaron en las células de Kupffer. Después, los lóbulos hepáticos aparecieron infiltrados por grandes colecciones de macrófagos parasitados. Las células hepáticas infectadas masivamente con *M. leprae*, desarrollaron un citoplasma granular pálido el cual se hizo espumoso en las lesiones tardías. En 3 de los hígados lepromatoides se observaron lesiones semejantes al *eritema nodoso leproso*.

### RÉSUMÉ

En vue d'évaluer la pathogénèse de la maladie expérimentale chez l'armadillo, on a procédé à une étude rétrospective des lésions hépatiques chez 13 armadillos infectés par voie intra-cutanée et simultanément par  $10^7$  *M. leprae* provenant du même inoculat. Les temps du survie ont varié de 13 à 55 mois. Chez 7 armadillos, les lésions hépatiques étaient nettement moins prononcées que chez les 6 autres. L'étendue des lésions n'était pas en relation avec la durée de l'infection, ce que l'on interprète comme le résultat de différences individuelles dans la résistance. Contrairement à ce

que l'on observe chez l'homme, des bacilles de la lèpre ont été trouvés dans les cellules hépatiques des deux groupes d'armadillos, mais cependant beaucoup moins abondants chez ceux qui étaient plus résistants. Ce dernier groupe ne présentait également aucune modification manifeste dans le tissu hépatique, si ce n'est la présence d'une infiltration par cellules arrondies, de même que la présence prédominante de cellules de Kupffer contenant *M. leprae*. Ces lésions peuvent être comparées à ce que l'on trouve dans la lèpre indéterminée chez l'homme.

Les lésions observées chez les armadillos les plus susceptibles (lépromatoides) ont débuté dans les cellules de Kupffer. Plus tard, de larges rassemblements de macrophages contenant des bacilles ont infiltré les lobules hépatiques. Les cellules hépatiques remplies de *M. leprae* présentaient un cytoplasme granulaire pâle, qui est devenu spumeux dans les lésions tardives. Dans trois de ces foies lépromatoides, on a observé des lésions compatibles avec *erythema nodosum leprosum*.

#### REFERENCES

1. BINFORD, C. H., STORRS, E. E. and WALSH, G. P. Disseminated infection in the nine-banded armadillo (*Dasypus novemcinctus*) resulting from inoculation with *M. leprae*. Int. J. Lepr. **44** (1976) 80-83.
2. KIRCHHEIMER, W. F. and SANCHEZ, R. M. Leprosy-susceptibility testing of armadillos. I. Cellular responses to intradermally inoculated heat-killed leprosy bacilli. Microbios **7** (1973) 31-35.
3. KIRCHHEIMER, W. F. and SANCHEZ, R. M. Quantitative aspects of leprosy in armadillos. Lepr. India **49** (1977) 48-53.
4. KIRCHHEIMER, W. F., STORRS, E. E. and BINFORD, C. H. Attempts to establish the armadillo (*Dasypus novemcinctus* Linn.) as a model for the study of leprosy. II. Histologic and bacteriologic post-mortem findings in lepromatoid leprosy in an armadillo. Int. J. Lepr. **40** (1972) 229-242.