

## Hepatic Lesions in Asymptomatic Children of Leprosy Patients<sup>1</sup>

M. M. Mittal, H. B. Maheshwari, K. Saha and R. Sharma<sup>2</sup>

Even with the increase of knowledge in the various facets of leprosy, the studies on asymptomatic infection in leprosy are very few. As early as 1949, Figueredo and Desai (4) reported for the first time that asymptomatic leprosy contacts were positive for acid-fast bacilli. The findings of these workers have been confirmed by Taylor *et al* (11), and Chatterjee *et al* (3). Leprosy is a systemic disease and hepatic involvement in all types of leprosy cases is well documented (1,7). There is no report available in literature whereby tissues other than the skin have been studied in cases of asymptomatic leprosy infection. This caused us to investigate changes in the liver in leprosy contact cases, even without any evidence of bacteriological positivity in skin smears, to make an attempt to demonstrate whether systemic involvement occurs prior to or with the development of skin positivity.

### MATERIALS AND METHODS

Fifty male children of leprosy patients living separately from their parents in the Children's Home Wazirabad at New Delhi were studied. All of them were clinically normal with ages ranging from 7 to 18 years. They either met with their parents and/or friends of parents (both tuberculoid and lepromatous) mostly once within 10 or 15 days and remained with them for about a month during the year in the summer vacations.

All of the children underwent x-ray examination of the chest and were carefully screened to exclude those in whom tuberculosis, poor dietary history, cachexia or steroid therapy might have affected the skin

test procedures. The history of prior BCG vaccination was also noted for each child.

Dharmendra lepromin 0.1 ml was injected on the flexor surface of the forearm and induration was measured after 48 hours (Fernandez type reaction) and 21 days (Wade-Mitsuda type reaction). An average diameter of firm induration (after three weeks of lepromin injection) of 3 mm or more was taken as a positive Mitsuda reaction. All children were also injected with 10 IU of old tuberculin in 0.1 ml of saline on the flexor surface of the forearm with a tuberculin syringe through a 26 gauge needle. All readings were made 48 hours after the injection.

Punch biopsy of the skin was done in every child either from the ear lobule or from a most suspected skin lesion. On another day, on each case a percutaneous liver biopsy was performed under aseptic technics with a Silverman's needle. The tissues were fixed in 10% neutral formalin, embedded in paraffin, sectioned at 5 microns and stained with hematoxylin and eosin. Sections of the liver tissue were also stained with methyl-violet for amyloid. Reticulin was demonstrated by the method of Wilder (8). A special staining for acid-fast bacilli was carried out employing the Wade-Fite formaldehyde new fuchsin method (8). The intensity of tissue infiltration by bacteria was graded according to the criteria laid down by Ridley in 1958 (10), while the skin histology was especially studied after the technic described by Ridley in 1973 (9).

### RESULTS

Out of the 50 children, adequate liver biopsies (measuring 0.5 to 2 cm in length) were obtained in 43 patients. In one of these 43 children the skin biopsy showed evidence of indeterminate leprosy. Excluding this case, the results of the present study are finally based on the observations made on 42 children.

On the basis of microscopic examinations of the liver, histological changes were present in 20 contacts (47%) which were divided

<sup>1</sup> Received for publication 11 June 1977.

<sup>2</sup> M. M. Mittal, M.D., Hon. Consultant in Medicine, Tirath Ram Shah Hospital, New Delhi; H. B. Maheshwari, M.D., Ph.D., F.A.C.P., M.A.M.S., Associate Professor in Pathology, Lady Hardinge Medical College, New Delhi; K. Saha, M.Sc., M.B.B.S., Ph.D., Associate Professor in Microbiology, G.B. Pant Hospital, New Delhi; R. Sharma, M.Sc., I.C.M.R. Research Scholar, G.B. Pant Hospital, New Delhi, India. Request reprints to Dr. H. B. Maheshwari.

TABLE I. Incidence of various hepatic lesions in asymptomatic children of leprosy patients.

Serial no.	Type of lesion	Changes observed in number of cases <sup>a</sup>	%
1.	Granuloma	4	9.5
2.	Focal necrosis	6	14.0
3.	Kupffer cell proliferation	14	17.0
4.	Portal triaditis	27	33.0

<sup>a</sup> Occasionally more than one lesion was seen in a biopsy. Total number of cases studied was 42.

into two major groups. The findings are tabulated in Table I.

**Granuloma.** Granulomatous lesions were seen in four cases. Along with these granulomatous lesions, the liver sinusoids showed prominent Kupffer cells in two and focal areas of necrosis in three. The granuloma consisted of circumscribed collections of histiocytes admixed with lymphocytes and occasional epithelioid cells (Fig. 1). Neither

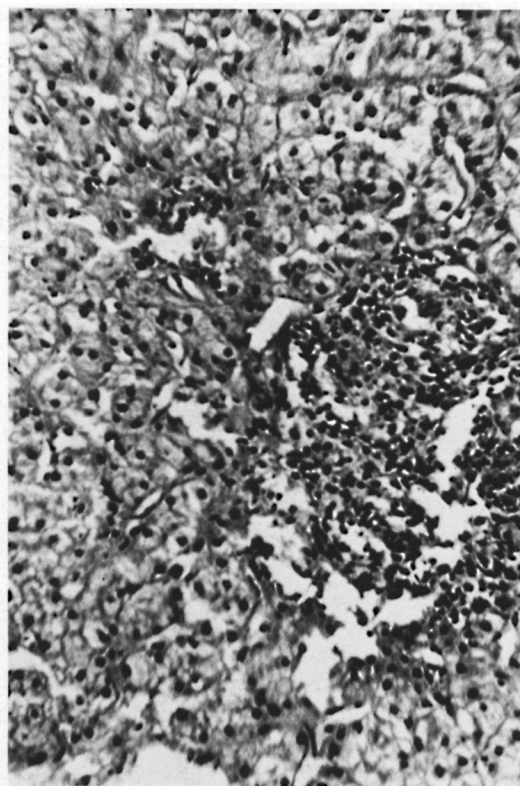


FIG. 1. Granuloma formation is seen in the liver parenchyma. Note circumscribed collection of histiocytes mixed with lymphocytes and occasional epithelioid cells. Hematoxylin & eosin,  $\times 240$ .

caseation necrosis nor lepra cells were seen in any. Two of the four cases showed solid acid-fast bacilli (++)

**Nonspecific changes.** These were further subdivided into three subgroups: focal necrosis, Kupffer cell proliferation, and portal triaditis. Nonspecific changes were observed in 19 biopsies including three of the previous group which showed granuloma formation. The changes consisted of focal areas of necrosis in 6, portal triaditis in 7, and Kupffer cell hyperplasia in 14 cases. At times more than one change was observed in a biopsy.

The focal areas of necrosis were characterized by lytic type of necrosis with collection of a few mononuclear cells in these areas. Kupffer cell prominence was comprised of a collection of three to five Kupffer cells in the form of small groups without any other inflammatory cells or necrosis (Fig. 2). Wide portal triads with diffuse infiltration of lymphocytes, mononuclear cells and occasional neutrophils characterized the triaditis (Fig. 3). These infiltrates were of moderate degree without any granuloma formation or any increase in connective tissue in these areas. In two of seven cases where triaditis and Kupffer cell hyperplasia were noted, solid acid-fast bacilli (++) were also seen.

Table 2 shows the correlation of various hepatic lesions with the history of BCG and the results of skin tests done with tuberculin and lepromin. It is evident from this table that there was no correlation between the incidence and nature of various hepatic lesions and the results of the various tests, except that in all four cases with demonstrable lepra bacilli, the skin tests with lepromin were also positive. But the latter observation does not lead towards any definite correlation as the lepromin test was also positive where no lepra bacilli were demonstra-

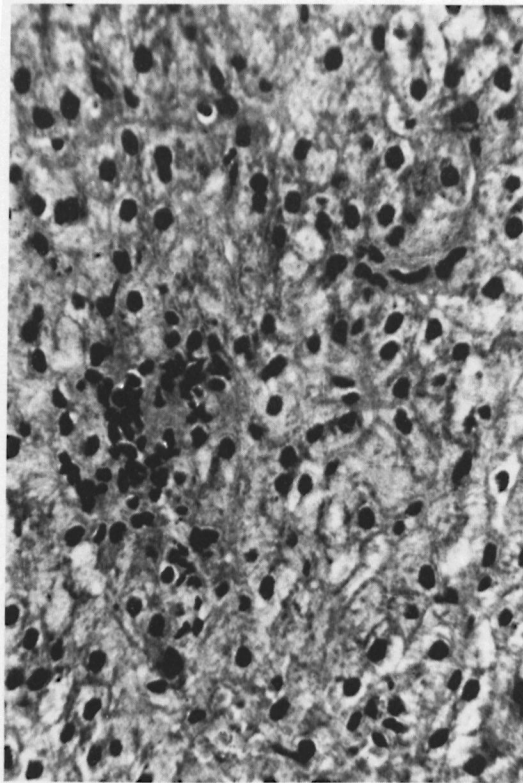


FIG. 2. Liver parenchyma shows nodular collection of Kupffer cells. No other change is seen in the surrounding liver cells. Hematoxylin & eosin,  $\times 240$ .

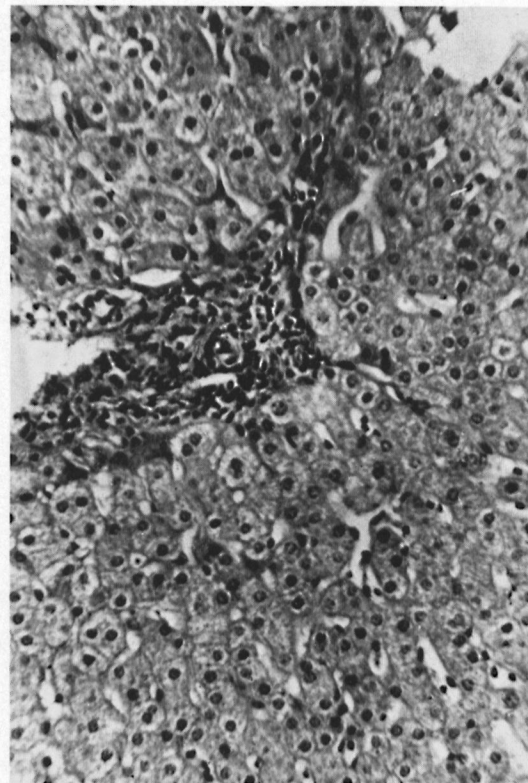


FIG. 3. Liver parenchyma shows a widened portal triad with infiltration of lymphocytes and mononuclear cells. Hematoxylin & eosin,  $\times 240$ .

ble in the hepatic histology, and the skin tests with lepromin were negative in two cases with definite granulomatous type of lesions in the liver.

#### DISCUSSION

The results of the present study revealed a 42% incidence of pathologic lesions of liver in asymptomatic leprosy contacts. Two types of lesions were encountered. These were either the occurrence of granulomatous type of lesion or nonspecific collection of lymphocytes and mononuclear cells in the hepatic parenchyma or around the portal regions. In four of these cases solid acid-fast bacilli were also observed. The results thus obtained provide a considerable amount of new evidence that bacillemia also occurs in cases of leprosy contacts even prior to the development of skin positivity. The results further support the existing views that subclinical infection occurs frequently in leprosy (5).

Godal (5) suggested that as in most infec-

tious diseases, the contacts of leprosy are also prone to the stage of subclinical infection. The methods available for putting a patient under a subclinical infective group can generally be divided under three headings: 1) detection of the infectious agent, 2) detection of immune response to *M. leprae*, 3) search for minor pathologic changes in the target organs.

In leprosy all three types of approaches have been applied. In 1949 Figueredo and Desai (4) for the first time reported that leprosy contacts are positive for acid-fast bacilli. By 1955 the same authors screened 1,852 contacts and showed positivity in 32.9%. Up to 38% of these cases eventually developed clinical signs of leprosy (11). Taylor *et al* (11) searched for acid-fast bacilli in the ear lobes of contacts of leprosy patients. They found that 20% of contacts of lepromatous patients and 2.5% of contacts of tuberculoid patients were positive for acid-fast bacilli, while of 50 persons examined in a leprosy nonendem-

TABLE 2. Results of skin tests done with tuberculin and lepromin.

Serial no.	Type of lesion	Observed in no. of cases	Histories of BCG		Skin tests with old tuberculin and lepromin					
					Tuberculin (10 IU)		Lepromin (0.1 ml)			
					+	—	Fernandez		Mitsuda	
1.	Granuloma	4	2	2	2	2	2 <sup>a</sup>	2	2 <sup>a</sup>	2
2.	Focal necrosis	6	3	3	2	4	1 <sup>a</sup>	5	1 <sup>a</sup>	5
3.	Kupffer cell proliferation	14	5	3	4	4	1	7	1	7
4.	Portal triaditis	7	1	1	1	1	1 <sup>a</sup>	1	0 <sup>a</sup>	2
5.	No lesion	22	10	12	9	13	2	20	1	21

<sup>a</sup> Acid-fast bacilli were demonstrable in liver biopsies. More than one lesion was seen in a biopsy. + = positive; — = negative.

ic area none were found to be positive. Lately, Chatterjee *et al* (3) have reported 5.8% incidence of bacteriologic positivity in contacts without showing clinical signs of infection. During the following two years of observation the authors observed a sixfold increase in the incidence of clinical infections in the bacillary positive over the negative contacts.

The most widely used immunologic test for examination of the immune response to *M. leprae* is the late (Mitsuda) lepromin test. However, because the test has been found to be positive in individuals not exposed to leprosy, it has lost its importance as a specific test for detection of the immune response elicited by *M. leprae*. In visualizing the limitations of the lepromin test, delayed-type immune responses to *M. leprae* have lately been carried out by the lymphocyte transformation test (LTT) and the leucocyte migration inhibition test (LMIT). Godal and Negassi (6) reported that of the subjects living in a leprosy endemic area for less than two months, none responded to *M. leprae*; 24% of subjects who had lived in an endemic area for more than a year gave positive responses to *M. leprae*; more than 50% of individuals with occupational contact of leprosy for more than a year responded; and about 50% of contacts of tuberculoid and treated lepromatous patients responded to *M. leprae*; while 22% of contacts of lepromatous patients, untreated or treated, for less than six months responded. These findings sug-

gest that leprosy is a highly infectious disease and subclinical infection commonly follows exposure to *M. leprae* (5,6).

There is no study where attempts have been made to search for minor pathologic changes in the target organs in cases of leprosy contacts. As it is now well established that leprosy is a systemic disease and that the liver is involved in all types of leprosy cases (1,7), the present study is the first report of the search for minor pathologic changes in cases of leprosy contacts who had no clinical signs or histopathologic changes in the skin. The findings of the present study not only strongly support the existing view that leprosy is a highly infectious disease but further suggest that bacilleamia also occurs in cases of leprosy contacts without showing signs of infection. Our observations at present do not allow us to make any definite conclusion, but taking into consideration the results of various published studies on leprosy contacts (2-6, 11) one is tempted to speculate that development of a lesion (subclinical or clinical) at any stage is not only the outcome of exposure alone but the various contributory risk factors viz.: a) immune status of the host, b) immune enhancing or suppressing factors playing at a particular time, c) dose of bacilli, d) interval between two exposures, e) number of exposures over a period, f) virulence of bacilli (?), and g) genetic factors of the host (?), play an equally important role and that disease at any stage is the end result of the interaction be-



tween the various contributory factors in a contact. The possibility suggested is hypothetical and can only be rejected or supported by further studies not only in man but perhaps in experimental animals also, where conditions can much more precisely be regulated to give specific answers in this specific field.

### SUMMARY

Forty-two asymptomatic children of leprosy patients were studied for possible hepatic lesions. Hepatic lesions were observed in 47% while acid-fast bacilli in the liver were found in 9.5%. The most frequent lesions encountered included granuloma in 9.5%, focal areas of necrosis in 14%, portal triaditis in 17%, and Kupffer cell hyperplasia in 33%. Occasionally more than one lesion was observed in a biopsy. No correlation with the occurrence of the various hepatic lesions could be made with a history of BCG vaccination or results of skin tests done with tuberculin and lepromin.

### RESUMEN

Se estudiaron 42 niños asintomáticos de pacientes con lepra, para determinar la presencia de posibles lesiones hepáticas. Se observaron lesiones hepáticas en el 47% de los casos y bacilos resistentes al alcohol ácido en el 9.5%. Las lesiones encontradas con más frecuencia incluyeron granulomas en el 9.5%, áreas focales de necrosis en el 14%, triaditis portal en el 17% e hiperplasia de las células de Kupffer en el 33%. Sólo ocasionalmente se observó más de una lesión por biopsia. No hubo correlación entre la presencia de las diferentes lesiones hepáticas, la historia de vacunación con BCG y los resultados de las pruebas dérmicas a la lepromina y tuberculina.

### RÉSUMÉ

On a étudié la présence éventuelle de lésions hépatiques chez 42 enfants de malades de la lèpre, ne présentant pas de symptômes. Des lésions hépatiques ont été observées chez 47%, tandis que les bacilles acido-résistants ont été trouvés au niveau du foie chez 9,5%. Les lésions les plus fréquentes qui ont été observées comprenaient des granulomes dans 9,5% des cas, des zones de nécroses en foyer chez 14%, une triadite portale chez 17%, et une hyperplasie des cellules de

Kupffer chez 33%. A l'occasion on a pu observer plusieurs lésions dans une même biopsie. Aucune corrélation n'a pu être établie entre l'apparition des diverses lésions hépatiques et des antécédents de vaccination au BCG, ou les résultats des épreuves cutanées par la tuberculine ou la lépromine.

**Acknowledgment.** We are grateful to the Superintendent, Children's Home Wazirabad for his cooperation and permission to carry out this study.

### REFERENCES

1. AGARWAL, S. C., MAHESHWARI, H. B., MITTAL, M. M. and KUMAR, S. A histological study of liver lesions in leprosy. *Ind. J. Med. Res.* **61** (1973) 389-395.
2. BALINA, L. M., FLIESS, E. L., BACHMANN, J. E., CARDAMA, J. E. and GATTI, J. C. Similar alterations of lymphoblastic differentiation in lepromatous leprosy patients and their healthy lepromin negative consanguineous offspring. *Int. J. Lepr.* **41** (1973) 7-14.
3. CHATTERJEE, B. R., TAYLOR, C. E., THOMAS, J. and NAIDU, G. N. Acid-fast bacillary positivity in asymptomatic individuals in leprosy endemic villages around Jhalda in West Bengal. *Lepr. India* **48** (1976) 119-131.
4. FIGUEREDO, N. and DESAI, S. D. Positive bacillary findings in the skin of contacts of leprosy patients. *Ind. J. Med. Sci.* **3** (1949) 258-285.
5. GODAL, T. Growing points in leprosy research: immunological detection of subclinical infection in leprosy. *Lepr. Rev.* **45** (1974) 22-30.
6. GODAL, T. and NEGASSI, K. Subclinical infections in leprosy. *Br. Med. J.* **3** (1973) 557-559.
7. KARAT, A. B. A., JOB, C. K. and RAO, P. S. S. Liver in leprosy: histological and biochemical findings. *Br. Med. J.* **1** (1971) 307-310.
8. LILLIE, R. D. *Histopathologic Technique and Practical Histochemistry*, 3rd ed., New York: McGraw-Hill Book Co., Inc., 1965, pp 527-580.
9. RIDLEY, D. S. The pathogenesis of the early skin lesion in leprosy. *J. Pathol.* **111** (1973) 191-206.
10. RIDLEY, D. S. Therapeutic trials in leprosy using serial biopsies. *Lepr. Rev.* **29** (1958) 45-92.
11. TAYLOR, C. E., ELLISTON, E. P. and GIDEON, H. Asymptomatic infections in leprosy. *Int. J. Lepr.* **33** (1965) 716-723.