

Surgical Decompression of Nerves in Leprosy. An Attempt at Prevention of Deformities. A Clinical, Electrophysiologic, Histopathologic and Surgical Study^{1,2}

Narendra J. Pandya³

Leprosy poses one of the major problems for the reconstructive surgeon today. A significant proportion of the 15 million people in the world suffering from leprosy could be benefited by corrective surgery at some stage of the disease. Even in the presence of adequate, uninterrupted treatment, in a certain percentage the illness progresses relentlessly. We decided to undertake a study to ascertain if early elective surgical decompression could be beneficial.

Peripheral nerve involvement in leprosy commonly results in disability and/or deformity. The most common nerve involved is the ulnar, followed by the lateral popliteal, median, and the posterior tibial. All the procedures thus far suggested for nerve surgery have been primarily carried out for the relief of pain due to leprosy neuritis or for evacuation of nerve abscesses. Babcock in 1907 was one of the first surgeons to recommend endoneurolysis by multiple longitudinal incisions. Since then many surgical procedures, including desheathing⁽⁶⁾, external and internal neurolysis⁽⁹⁾, external neurolysis with anterior translocation and resection of thickened sheath⁽³⁾, neurolysis and transposition⁽⁵⁾, division of fascial roof and excision of fibrous arch⁽¹¹⁾, external neurolysis in combination with various other procedures⁽⁸⁾, have been carried out. Carayon *et al*⁽⁴⁾ advocated fascicular neurolysis which, in their hands, has given satisfactory results. Brand⁽²⁾ cautions against operating on actively inflamed nerves, believing this

may result in further damage and subsequent fibrosis.

We felt that timely elective surgical help could be rendered in early cases as an adjunct to retrieve some of the damaged tissues and prevent further deformities. It was decided to carry this out with meticulous care and microsurgical technic without the least interference to the blood supply or damage to the vital inflamed tissues. Extranatural decompression to relieve the external, and longitudinal epineurotomy to relieve the internal pressures throughout the involved segment was considered appropriate and adequate. Most of the detailed description will be confined to the ulnar nerve as this was the most common nerve studied. However, the basic pathologic changes and factors involved are similar and therefore applicable to all other nerves.

In order to achieve full benefits of extraneural decompression in the ulnar nerve, complete release must be obtained at four common sites of most severe involvement and compression. For the ulnar nerve these are the medial intermuscular septum, under the deep fascia of the anterior medial compartment of the forearm, in the distal fibroosseous tunnel, and between the tendinous fibers of origin of the two heads of the flexor carpi ulnaris.

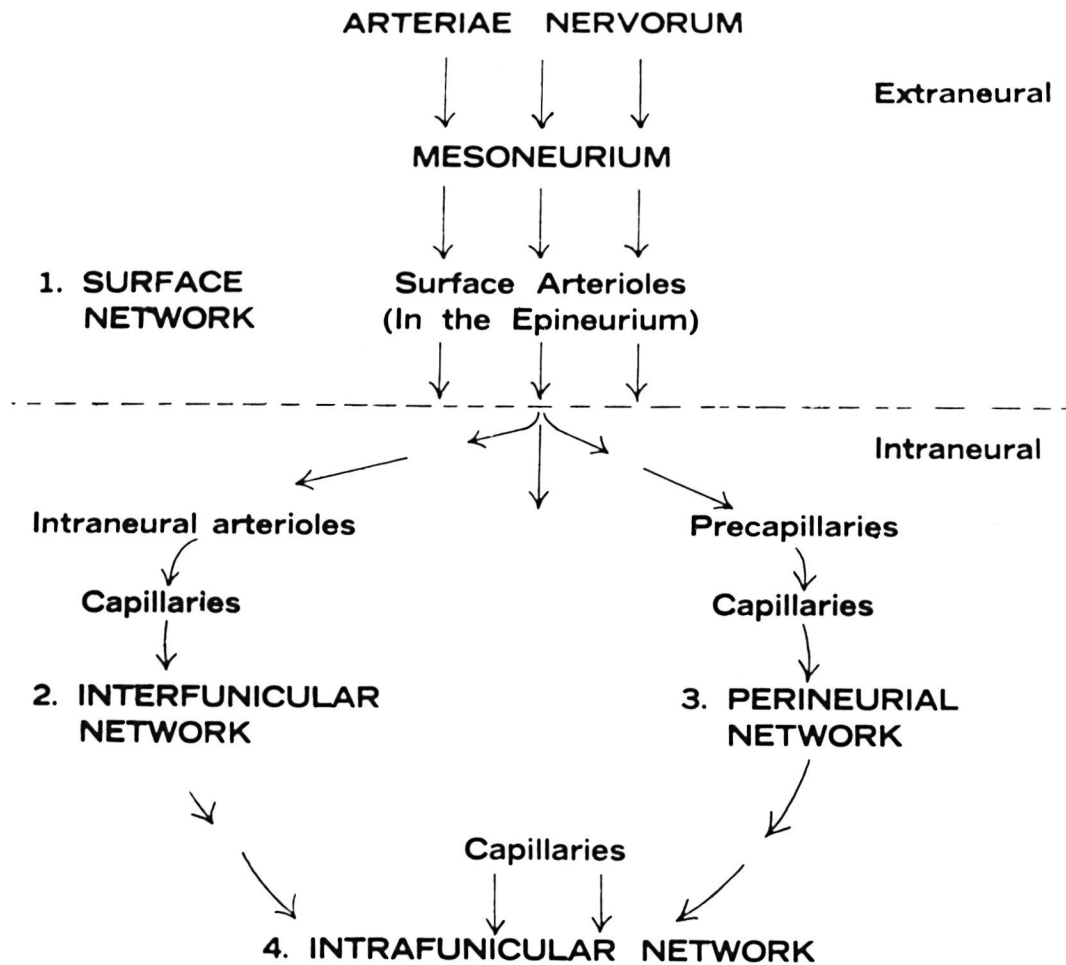
The accumulation of inflammatory products within the peripheral nerve bundles within the confining nerve sheaths, together with edema lead to compression damage of the nerve bundles as well as interference with blood circulation leading to hyperemia and further edema. The resulting ischemia promotes fibrosis.

The vascular supply of the nerve is from the surface, interfunicular, perineural and intrafunicular vessels (Table 1). Any compression causing the disturbance of the blood supply results in the impairment of

¹Original paper received 30 July 1976. Revised paper received for publication 9 May 1977.

²This study was conducted at the Tata Department of Plastic Surgery, J. J. Group of Hospitals, Bombay.

³N. J. Pandya, F.R.C.S., Hon. Assit. Plastic Surgeon, Jaslok Hospital and Research Centre, and B. Y. L. Nair Hospital, Bombay, India. Reprint requests to Dr. Pandya, 1, West Navroze Apartments, Bhulabhai Desai Road, Bombay—400 026, India.

TABLE 1. *Vascular pattern of a nerve.*

function. Relief from ischemic compression as early as possible with little anatomical disturbance so as to prevent further vascular damage should help to achieve better nutrition by restoring improved and adequate vascularity before any permanent and/or irreversible damage occurs. Extraneural decompression may help to restore the surface blood supply while intraneural decompression will relieve the deeper capillary networks⁽¹⁰⁾.

MATERIALS AND METHODS

The patients. This report concerns 45 volunteer patients. The patients were informed of the nature of this treatment and their consent obtained. There were 38 males and 7 females from 13 to 50 years of age. The largest number of patients were from 21-30

years, followed by 31-40 years, 11-20 years, and lastly 41-50 years. Twenty-seven patients had been treated with antileprosy drugs for varying periods of time. Of these, 3 had irregular treatment. Eighteen patients had no treatment at all. The majority of the patients (35) were of the tuberculoid type, followed by seven borderline and three lepromatous. Only nine patients were bacteriologically positive at the time of initial examination.

The interval between the appearance of the first neural symptoms and surgical treatment varied from five weeks to five years. Sixteen patients had symptoms for less than three months, while thirteen had symptoms for four to six months. Nine patients had symptoms for more than one year.

Tingling, numbness, and formication were

TABLE 2. *Presenting symptoms of patients.*

SYMPTOM	NUMBER OF PATIENTS
Tingling & Numbness or Ant-like Crawling Sensation	24
Early Clawing Deformity	8
Dull ache at the site of involvement	7
Sensory loss	6
Pain	4
Motor Weakness	2
Ulcer	1
Patch	1
No Symptoms	1

**NINE PATIENTS HAD MORE THAN ONE
PRESENTING SYMPTOM**

the predominant complaints in 24 patients. Eight patients presented with early claw deformity while seven had a dull ache at the site of nerve involvement. Six patients complained of loss of sensation while only four complained of pain. Nine patients had more than one presenting symptom (Table 2).

Patient evaluation. A detailed history was recorded for each patient, including the duration of the disease, especially the origin of neural symptoms and regularity of treatment or otherwise. A detailed clinical examination was carried out. All the peripheral nerves were systematically palpated and a detailed record of their thickness, tenderness, consistency and fixation to the surrounding tissues was made. Sensory testing included hot and cold temperature as well as No. 5 and graded nylon studies. Details of muscle tone and power were also recorded. Pain on pressure could be elicited in most cases. Photographic records of all patients were also kept. All these were recorded before and after treatment. The examination was completed by a thorough systemic evaluation. Skin smears by routine slit and scrape method were taken from the ear, nasal scrapings and skin patch (if present) and examined for acid-fast bacilli by Ziehl-Neelsen staining.

Electrophysiologic studies were per-

formed before and at varying intervals after the operation whenever feasible or indicated. Percutaneous stimulation of the ulnar nerve was made using two disc electrodes placed on the sides of the nerve in its superficial course in the upper arm. Muscle action potentials were recorded from the flexor carpi ulnaris by means of a bipolar electrode introduced into the muscle about 8 cm below the elbow. The electropotentials were recorded on a 2-channel machine.

Surgical technics. The surgical procedure was carried out under a tourniquet. Local anesthesia was preferred for single nerve and general for multiple procedures. The operative time varied from 20 to 30 minutes. Zeiss magnifying loops ($\times 2$) were employed during dissection.

The ulnar nerve at the elbow was exposed through an incision placed 7 cm above and 3 cm below the medial epicondyle. The deep fascia of the anterior medial compartment of the upper arm was exposed after incising the skin and the subcutaneous tissue. It was divided longitudinally and this was continued to divide the fibro-osseous tunnel between the olecranon and medial epicondyle. This is usually the point of maximum compression. Division of the overlying tendinous fibers of origin of the flexor carpi ulnaris provide a complete extraneural release (Fig. 1).

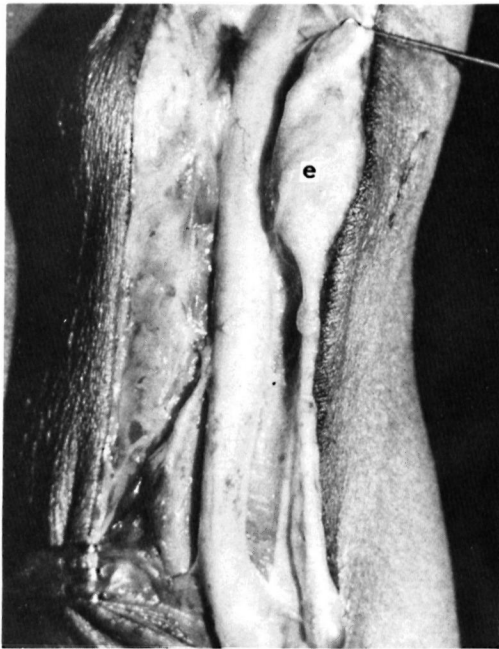

FIG. 1. External neurolysis completed. The rounded nerve shows thickening extending from the lower arm to the heads of flexor carpi ulnaris (e = medial epicondyle).

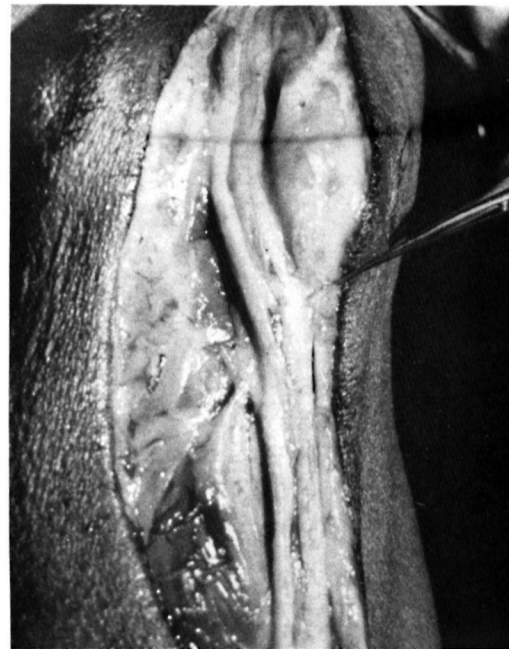

FIG. 2. Medial longitudinal epineurotomy completed. The opened nerve exposes the bundles.

TABLE 3. Sensory recovery of patients.

Group	Excel- lent	V. Good	Good	Satis- factory	Un- Satis- factory	Worse	No Deteri- oration	Lost
Number of Patients	16	5	6	6	3	1	6	2
RECOVERY AGAINST DURATION OF SYMPTOMS								
Less than 3 Months	8	2	1	0	1	1	2	1
4- 6 Months	7	2	2	0	1	0	1	0
7-12 Months	0	0	1	4	1	0	1	0
More than One Year	1	1	2	2	0	0	2	1
RECOVERY AGAINST AGE OF PATIENT								
10-20 Years	4	0	2	1	0	0	2	1
21-30 Years	6	2	1	3	2	1	3	0
31-40 Years	6	1	1	2	1	0	1	1
40-50 Years	0	2	2	0	0	0	0	0

The entire segment of the exposed nerve is cleared without lifting it from its bed. Intra-neural decompression through a medial longitudinal epineurotomy was carried out with the help of a fine untoothed watchmaker's forceps and an iris scissors. Due care was taken to extend this beyond the involved segment without damaging the vascular network (Fig. 2). The skin only was closed and a compression bandage was used.

Neurolysis was performed on 69 nerves. Thirty-two patients had single nerve involvement, 10 had 2, and one each had 3, 6 and 8 nerves involved. The ulnar nerve at the elbow was the most common nerve involved (49), followed by the lateral popliteal at the knee (9), median at the wrist (7), and posterior tibial at the ankle (4). Bilateral neurolysis of the ulnar nerve was carried out in ten patients, of the posterior tibial in two, and the median and lateral popliteal nerves in one patient each (Table 3).

Post-operatively all the patients were continued on antileprosy drugs and followed at regular intervals of two weeks, four weeks, and three and six months. When indicated, they were followed at shorter intervals. At each follow-up visit subjective impressions and objective evaluations to include motor and sensory charting were carried out. If found necessary, repeat electromyographic studies were performed.

RESULTS

The results were evaluated on the basis of subjective improvement and objective findings relating to both sensory and motor modalities. The clinical evaluation was done by a physician while the sensory charting was carried out by one of the other members of the team. These were always confirmed by a second worker.

The improvement in sensory function was assessed by the extent of recovered territory and was expressed as a percentage of the pre-operative involved area. Additional observations were made by serial charting with graded nylon. Motor recovery was assessed from the patient's comments and also by estimation of tone and power changes in the affected group of muscles. This was also expressed as a percentage of the pre-operative level. We feel that our evaluation of motor recovery was less satisfactory as we were unable to quantify the results.

Pain, in all cases when present, was the first symptom to be completely relieved. Sensory improvement appeared as early as four weeks or as late as six months post-operatively. The improvement was progressive and gradual and maximal benefit was observed at about the end of the first year. The improvement in motor function appeared late and was slow. It sometimes took as long as two years to obtain maximal motor recovery. This progressive gradual recovery over a long period emphasizes the need for an extended follow-up.

Forty-three patients were followed for a period varying from 3 months to 3 years with an average of 25 months. Two patients were lost to follow-up. Sixteen had excellent sensory recovery while five had very good return of sensation. Six patients each had good and satisfactory results. Three patients did not show any recovery, while in one patient the condition worsened. Six patients who had no sensory loss pre-operatively did not show any deterioration even three years after surgery (Table 3).

Excellent motor recovery was seen in four patients while three showed good recovery. In 19 patients the recovery was satisfactory while 7 had no improvement at all. Only one patient deteriorated following surgery. Nine patients who had no loss of motor power pre-operatively showed no deterioration at three years after surgery (Table 4).

Sensory and motor recovery were further matched with duration and age at the onset of symptoms. Maximum sensory benefit was obtained when treatment was sought early, within six months of the first symptoms. However, when this was delayed, the extent of recovery was less. Motor recovery also followed a similar pattern showing maximal improvement following decompression within six months of symptom appearance. Sensory as well as motor recovery was, however, less predictable when they were matched with the age of the patient at the onset of symptoms. The recovery was similar in the age groups from 10-40 years. It was less noticeable in the over 40 age group. Sensory recovery, however, even in this group was always better than the motor recovery.

Six patients with sensory loss had total recovery. Four patients who had early clawing of the ring and little fingers also had total recovery (Fig. 3). One patient with a foot drop had complete recovery and discarded

TABLE 4. Motor recovery of patients.

Group	Excel- lent	Good	Satis- factory	Un- Satis- factory	Worse	No Deteri- oration	Lost
Number of Patients	4	3	19	7	1	9	2
RECOVERY AGAINST DURATION OF SYMPTOMS							
Less than 3 Months	1	1	5	3	1	4	1
4- 6 Months	3	1	6	1	0	2	0
7-12 Months	0	0	4	1	0	2	0
More than 1 Year	0	1	4	2	0	1	1
RECOVERY AGAINST AGE OF PATIENT							
10-20 Years	0	0	3	4	0	2	1
21-30 Years	0	3	8	1	1	5	0
31-40 Years	4	0	4	2	0	2	1
41-50 Years	0	0	4	0	0	0	0
SENSORY LEGEND				MOTOR LEGEND			
More than 75%	Excellent	51-75%	Very Good	More than 50%	Excellent	31-50%	Good
26-50%	Good	1-30%	Satisfactory	0%	Satisfactory		Unsatisfactory
1-25%	Satisfactory		Unsatisfactory				
0%	Unsatisfactory						

his splint, while another had a partial but significant similar recovery. One patient with a long-standing plantar ulcer noticed complete healing after five years. In four cases with bilateral involvement, simultaneous decompression showed a greater improvement in the less affected limb.

Electrophysiologic evidence of recovery was more noticeable in those patients with a shorter history. When the nerve damage was considerable no recovery, corresponding to the clinical findings, was obtained.

DISCUSSION

Mitchell in 1872 was one of the first to stress the importance of preserving the blood supply to injured nerves (7). The disturbance in the blood supply of the peripheral nerves is one of the main factors responsible for various types of pathologic changes seen in the nerve. It is now generally accepted that the efficient functioning of the peripheral nerve largely depends on its blood supply. The intraneural as well as perineural blood supply are of equal importance.

Nerve damage is often permanent and disabling and, therefore, of paramount practical importance in leprosy. Advances in the prevention and management of nerve damage

are only possible as a result of increased understanding of the various mechanisms involved. Partial ischemia causes a reversible paralysis without Wallerian degeneration. If, however, the ischemia becomes absolute or lasts for a long time, the nerve will be destroyed and the paralysis is then irreversible. To this can be added the constricting effects of fibrosis following ischemia. At an earlier stage of the disease, the intraneural edema is primarily responsible for the constricting effects and decompression is indicated. Once fibrosis sets in surgery is of little use. This is clearly explained in Figures 4 and 5. Early attack is the essence of treatment. Relief from ischemia in the surface network following extraneural decompression and in the interfunicular, perineural and intrafunicular networks following medial longitudinal epineurotomy could explain the improvement of sensory and motor functions. Semi- and ultrathin sections of decompressed nerves have shown a large number of regenerating fibers. Part of this improvement may also be due to improved lymphatic drainage through the inflamed tissues after relief from pressure.

Corrective reconstructive procedures were carried out simultaneously in five cases at

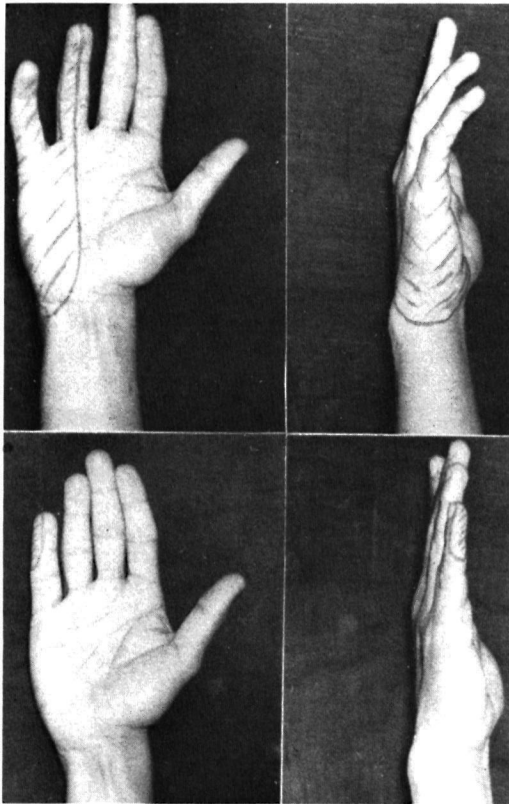


FIG. 3. Pre-operative photographs (upper) of right hand showing ulnar clawing and sensory loss. Lower, six months later, showing motor and sensory recovery.

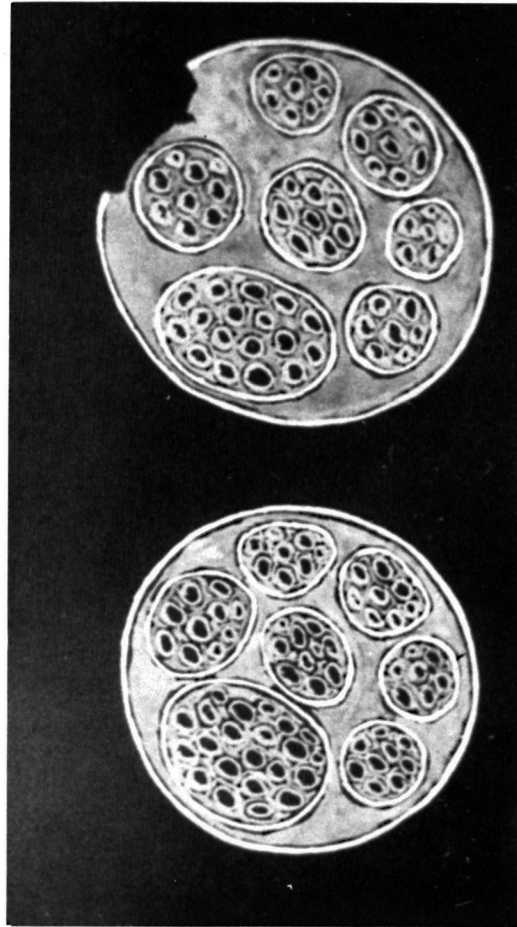


FIG. 4. Edematous nerve in reaction, and the effect of epineurotomy.

the time of decompression. They all give satisfactory results. Four of these patients were in the 10-20 year age group. This high incidence may indicate a higher susceptibility in the younger group.

As expected the damage to the nerve fibers was more severe in the tuberculoid type. Due to an uneven distribution in the type of disease, a comparative assessment could not be made.

Fascicular neurolysis, recommended by Carayon (⁴), has given satisfactory results in his hands. The procedure was intended to relieve intratruncal hypertension which is not a common finding in the ulnar nerve in leprosy. However, no critical objective evaluation has been published. We have no

experience with this method. Anterior transposition has given very good short-term results (⁵). However, we are of the opinion that it is unwise to lift an inflamed nerve from its bed. Antia (¹) has strongly discouraged the isolation of any long segment of ulnar nerve in leprosy. Extensive freeing gives less satisfactory results, possibly by compromising the vascular supply.

The best results were obtained in patients seeking treatment early in whom the nerves were edematous, swollen and surrounded by a hyperemic sheath. A thinned, fibrosed and ischemic nerve, however, showed no improvement. Treatment with antileprosy drugs must be continued. The need for regu-

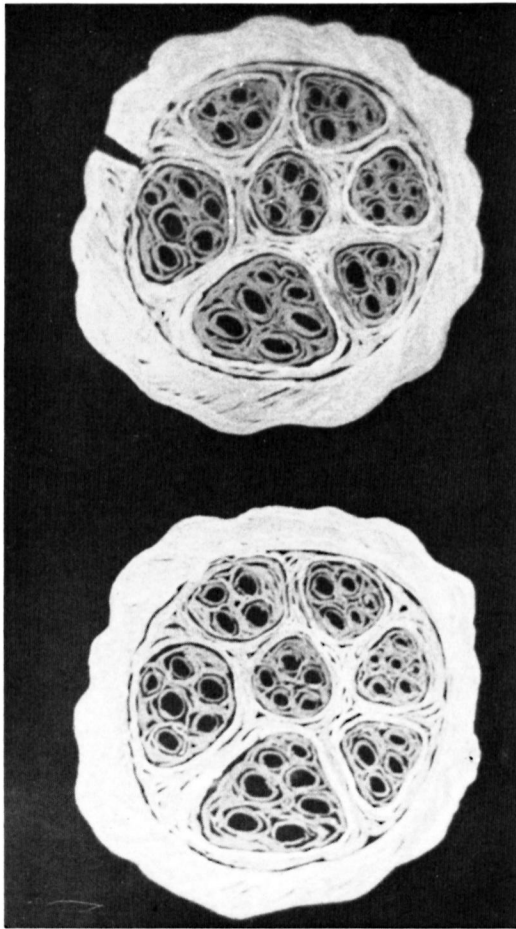


FIG. 5. The effect of epineurotomy on the release of a constricted nerve having intraneural fibrosis.

lar and prolonged therapy must be emphasized to the patient.

Early elective extraneural decompression and medial longitudinal epineurotomy have given very good results in our hands so far for a period up to three years. The results have been very encouraging and, except in one case where these temporarily worsened, no deterioration of symptoms or appearance of new deformities have been seen. Three years is a relatively short period when one takes into account the natural history of leprosy. Yet, these results cannot be ignored. Although these results so far justify our optimism, a need for further long-term follow-up must be emphasized. These studies with controls in bilateral cases are continuing.

SUMMARY

Forty-five leprosy patients were electively subjected to extraneural decompression and medial longitudinal epineurotomy in anticipation that relief from compression may favorably alter the course of the disease by retrieving reversibly damaged nerve bundles and preventing further progression of disease. Neurolysis was performed in 69 nerves, including the ulnar, median, lateral popliteal and posterior tibial. The period of follow-up was up to three years. Excellent sensory recovery was seen in most patients while motor recovery was less predictable. The recovery seen was better in those patients taking treatment early and also at the age the surgery was carried out. Motor damage appeared more severe in the 10-20 year age group. Most of the beneficial effects can be explained on the basis of increased vascularity due to relief from extraneural and intraneural compression.

RESUMEN

Cuarenta y cinco pacientes con lepra se sometieron a descompresión extraneural y a epineurotomía media longitudinal con la idea de que la descompresión pudiera alterar favorablemente la evolución de la enfermedad, permitiendo la regeneración de los haces nerviosos dañados reversiblemente y evitando el progreso posterior de la enfermedad. Se hizo neurolysis en 69 nervios, incluyendo el ulnar, el mediano, el poplíteo lateral y el tibial posterior. El periodo de observación fue de 3 años. En la mayoría de los pacientes se observó una excelente recuperación sensorial mientras que la recuperación motora fue menos predecible. La recuperación fue mejor en aquellos pacientes que habían iniciado su tratamiento temprano y en aquellos que mantenían su tratamiento cuando se sometieron a la cirugía. El daño motor fue más severo en los pacientes entre 10 y 20 años de edad. La mayoría de los efectos benéficos puede explicarse sobre la base de un aumento en la vascularidad debido a la descompresión extraneural e intraneural.

RÉSUMÉ

On a procédé à une décompression extra-neurale et à une épineurotomie longitudinale médiane chez 45 malades de la lèpre choisis de façon sélective. On espérait que cette intervention visant à relever la compression modifierait favorablement l'évolution de la maladie en libérant des faisceaux nerveux dont l'atteinte était encore réversible, et en prévenant la progression ultérieure de la maladie. Cette neurolyse a été pratiquée au niveau

de 69 nerfs, y compris le cubital, le médian, le poplité latéral, et le tibial postérieur. Le suivi s'est étendu sur une période allant jusqu'à trois ans. Une récupération sensorielle excellente a été observée chez la plupart des malades, tandis que la récupération motrice était moins prévisible. La récupération était beaucoup plus notable chez les malades qui avaient été mis en traitement précocement, et également dépendait de l'âge auquel l'intervention avait eu lieu. Les lésions motrices ont paru plus sévères dans le groupe d'âge de 10 à 20 ans. La plus grande partie de l'effet favorable peut être expliquée sur la base d'une vascularisation accrue, par suite du relâchement de la compression extra-neurale et de la compression intra-neurale.

Acknowledgments. This study was supported by a grant from the Tata trusts and companies for the research projects of the Tata Department of Plastic Surgery. The electromyography machine used was donated by Emaus-Suisse. Three patients were from the Jaslok Hospital and Research Centre while two came from Kusht Dawakhana at Wadoli. My special thanks to Drs. N. H. Antia and Bindu Vankani for their guidance and assistance in this study.

REFERENCES

1. ANTIA, N. H. Personal communication, 1975.
2. BRAND, P. W. The reconstruction of the hand in leprosy. *Ann. R. Coll. Surg. Engl.* **11** (1952) 350-372.
3. CALLAWAY, J. C., FITE, G. L. and RIORDAN, D. C. Ulnar and median neuritis due to leprosy. *Int. J. Lepr.* **32** (1964) 285-291.
4. CARAYON, A., BOURREL, P. and LANGUILLON, J. *Surgery in Leprosy*. Paris: Masson et Cie, 1964.
5. ENNA, C. D. Neurolysis and transposition of the ulnar nerve in leprosy. *J. Neurosurg.* **40** (1974) 734-738.
6. LOWE, J. Comments on the history of leprosy. *Indian Medical Gazette* **77** (1942) 680-684.
7. MITCHELL, W. *Injuries of the Peripheral Nerves*. Philadelphia: publisher not available, 1872.
8. PALANDE, D. D. A review of 23 operations on the ulnar nerve in leprosy neuritis. *J. Bone Joint Surg.* **55A** (1973) 1457-1464.
9. SAID, G. Z., ZOHDY, A. and EL-AKKAD, I. N. External and internal neurolysis of ulnar and median nerves in leprosy neuritis. *Lepr. Rev.* **44** (1973) 36-43.
10. SMITH, J. W. Factors influencing nerve repair. Blood supply of the nerves. *Arch. Surg.* **93** (1966) 335-352.
11. VAIDYANATHAN, E. P. and VAIDYANATHAN, S. I. Treatment of ulnar neuritis and early ulnar paralysis. *Lepr. Rev.* **39** (1968) 217-219.