

## Segmental Necrotizing Granulomatous Neuritis of Leprosy<sup>1</sup>

Sushil M. Chandi, C. J. G. Chacko, Ernest P. Fritschi,  
and C. K. Job<sup>2</sup>

In 1924, Muir (<sup>10</sup>) published the first description of a patient with leprosy, who developed localized nodular swellings in a peripheral nerve. After aspiration and subsequent incision of these nodules, "pus-like" material was drained. Following this account, there have been occasional reports of cases with similar lesions under the general appellation, "nerve abscess" in leprosy. However, a clear picture of the nature of the lesion and its clinicopathological features does not seem to have been arrived at, primarily because there has not been to date a systematic study of a large group of such cases.

This paper presents the results of a retrospective analytic study of 30 patients with leprosy who developed localized nodular swellings with caseous necrotic centers and granulomatous inflammation in their peripheral nerves.

While this study was underway it soon became apparent for reasons mentioned below, that the name "nerve abscess" is inaccurate and inappropriate for this lesion. It is therefore suggested that it may be referred to by a more accurate though still descriptive name, "segmental necrotizing granulomatous neuritis of leprosy (SNGN)."

<sup>1</sup> Received for publication on 9 May 1979; accepted for publication in revised form on 9 November 1979.

<sup>2</sup> S. M. Chandi, M.D., Reader, Norman Institute of Pathology, Christian Medical College and Hospital, Vellore-632 004, India; C. J. G. Chacko, M.D., Ph.D., Head, Radda Barnen Research Laboratories, Schieffelin Leprosy Research and Training Centre, Karigiri-632 106 and Professor of Pathology, Christian Medical College, Vellore; Ernest P. Fritschi, D.Orth., F.R.C.S., Medical Superintendent, Schieffelin Leprosy Research and Training Centre, Karigiri-632 106; and C. K. Job, M.D., F.R.C.Path., F.A.M.S., Principal and Professor of Pathology, Christian Medical College, Vellore and Consultant Pathologist, S.L.R. & T.C., Karigiri.

### MATERIALS AND METHODS

All patients seen at the Schieffelin Leprosy Research and Training Centre, Karigiri, between 1960 and 1975 in whom a diagnosis of nerve abscess in leprosy had been made on clinical or pathologic grounds were selected for review of their case records and histopathologic material. Cases were accepted for inclusion in this study only when all of the following four criteria were fulfilled: 1) a clinical diagnosis of leprosy often supported by histopathologic evaluation of skin biopsies; 2) the presence of one or more nodular thickenings of peripheral nerves; 3) microscopic evidence of caseous necrosis in these lesions; and 4) availability of adequate biopsy material from the lesion.

All the available relevant clinical and laboratory data were tabulated. When obtainable, skin biopsies of these patients were reviewed without prior knowledge of the file diagnosis and were used to classify the disease process according to a modified scheme of Ridley and Jopling (<sup>8</sup>). The nerve biopsy in each case was scrutinized by light microscopy for features such as the degree of preservation of the general neural architectural details, perineurial thickening, amount of necrosis, presence of calcification, and composition of the inflammatory cell reaction. Fresh sections were cut from the respective paraffin blocks of the nerve biopsies and examined for the presence of acid fast bacilli (AFB) after staining them by a modified Fite-Faracco method. Each section was carefully examined across its length and breadth, using a method as for blood smear examination, with slightly overlapping microscopic fields. Only unequivocal granular, beaded, or solid AFB with the morphologic characteristics of *Mycobacterium leprae* were taken into account. When AFB were not found in a given sec-

TABLE 1. Age at presentation for treatment.

Age in years	No. of patients
Less than 10	1
10-20	10
21-30	10
31-40	7
41-50	2

tion, an additional two adjacent sections were also similarly examined, and only when all three sections showed no bacilli was the count marked as zero.

### RESULTS

Thirty cases fulfilled the criteria mentioned above and formed the basis of this study.

a) *Age at presentation for treatment:* (Table 1)

The age of the patients at the time of presenting themselves for treatment ranged from 9 years to 50 years. Two-thirds of them were between 10 and 30 years old with an equal number of cases in the 2nd and 3rd decades.

b) *Sex:*

Of the 30 patients, 4 (13.3%) were females and 26 (86.7%) were males.

c) *Duration of symptoms at presentation:* (Table 2)

This ranged from 6 months to as much as 8 years; however, 70% of the patients presented within the first 24 months of the onset of symptoms.

d) *Clinico-pathologic classification of the type of leprosy:*

Twenty-eight of the 30 patients were clin-

TABLE 2. Duration of symptoms at presentation.

Duration in years	No. of patients
Up to ½	3
½-1	10
1-1½	2
1½-2	6
2-2½	—
2½-3	4
5	4
8	1

TABLE 3. Presenting symptoms and signs.

Symptom or sign	No. of patients
Pain	1
Tenderness	4
Paresthesiae	2
Motor paralysis	14
Nerve thickening	30
Regional anesthesia	21
Localized anesthesia	8

ically diagnosed as having the tuberculoid form of the disease.\* One was thought to have borderline tuberculoid and one indeterminate leprosy. A lepromin test was performed on 15 patients and was positive in all of them.

Skin biopsies were available in 19 of these patients and were classified as follows: polar tuberculoid—2 patients, borderline tuberculoid—11, indeterminate leprosy—4, mild nonspecific dermatitis —1, and no significant lesion—1 patient.

e) *Presenting symptoms and signs:* (Table 3)

Apart from the cutaneous manifestations of leprosy, the most common presenting clinical features related to the peripheral nervous system. The triad of localized neural thickening, regional cutaneous anesthesia involving the area of sensory afferents to the affected nerve, and motor paralysis occurred in that order of frequency. Pain was experienced by one and paresthesia by only 2 patients. The affected nerve was tender in 4 cases. Eight patients had small irregular localized patches of cutaneous anesthesia instead of a well defined regional anesthesia. In 7 patients, there was clinical evidence of neuritis; however, there was no proclivity for this to occur in any particular nerve.

f) *Site of the segmental necrotizing granulomatous neuritis:* (Table 4)

By far the commonest primary site was

\* The data on clinical classification were based on records of a period spanning 16 years. During the earlier part of this period, the term, tuberculoid, was used in the older sense and included what is now known as borderline tuberculoid (BT) and polar tuberculoid (TT).

TABLE 4. Site of segmental necrotizing granulomatous neuritis.

Nerve	No. of cases		
	Left	Right	Side not recorded
Greater auricular	1	—	
Ulnar	5	11	
Median	1	—	
Radial cutaneous	2	3	
Lateral popliteal	2	—	1
Cutaneous nerve adjacent to skin patch	—	2	
Sural	2	—	

the ulnar nerve, being involved in 53.3% of the cases. The right ulnar nerve, just above the medial epicondyle of the humerus was the site of the lesion in 11 patients (36.6%).

g) *Gross appearance of the affected nerve:*

When exposed during surgical exploration, the affected segments of the nerves were enlarged and measured up to 4 cm in width and 10 cm in length. All had fluid or semifluid necrotic material in the center of the nodular or fusiform expansion of the nerve. In 6 cases there was a collar-stud-like extension of the lesion beyond the natural confines of the nerve, but the lesion was still enclosed by a fibrous wall. Further adhesions were present between the nerve and the surrounding tissue in 2 cases. In 4 patients there was more than one focus of nodular neural thickening; 3 patients had 3 distinct foci, and 1 patient had 2.

h) *Histopathologic alterations in the nerve:*

The amount of peripheral nerve tissue that was excised for histopathologic examination in each case was variable; however, all were considered to be adequate for analysis.

The general architecture of the nerve was

TABLE 5. Number of bacilli found in tissue sections.

No. of bacilli	No. of cases
0	7
1-5	16
6-10	3
More than 10	4

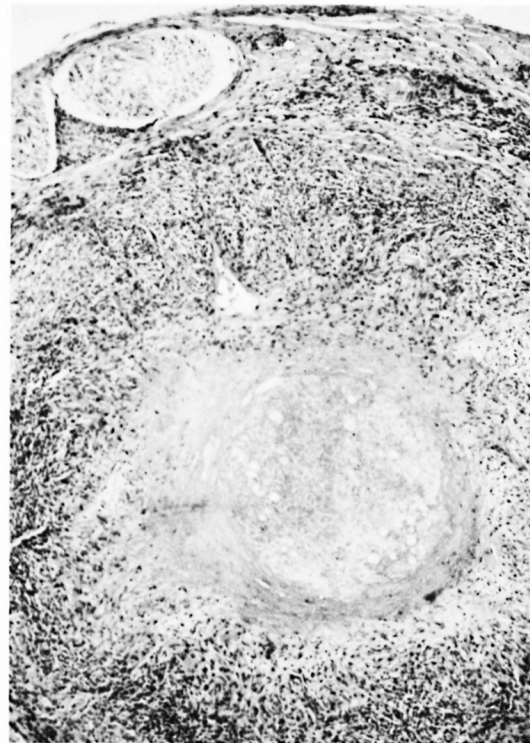


FIG. 1. Typical histopathological appearance of SNGN on transverse section (HE  $\times$  50).

more or less completely effaced in 12 cases, less severely altered in 5, and was relatively well preserved in 13. There was perineural thickening and fibrosis to varying degrees in almost all the cases (26 of 30). In two cases, the perineurium was not identified. The biopsy in these two cases was evidently taken from the inner core of the nerve after it was incised prior to drainage and curettage of the necrotic material within it.

Areas of calcification were present in the necrotic zones of the nerves in 5 cases. Acid fast bacilli were detected in 23 (76.6%) cases (Table 5). Between 1 and 5 bacilli were present in 16 (53.3%) and more than 5 bacilli in 7 (23.3%) nerve sections. Most of the bacilli detected were isolated, solitary ones; however, occasionally they were seen in pairs and sometimes in small groups. The bacilli were most easily and frequently found in the central zones of caseation rather than in the surrounding band of inflammatory cell infiltration. Sometimes the bacilli were noted in strands of what

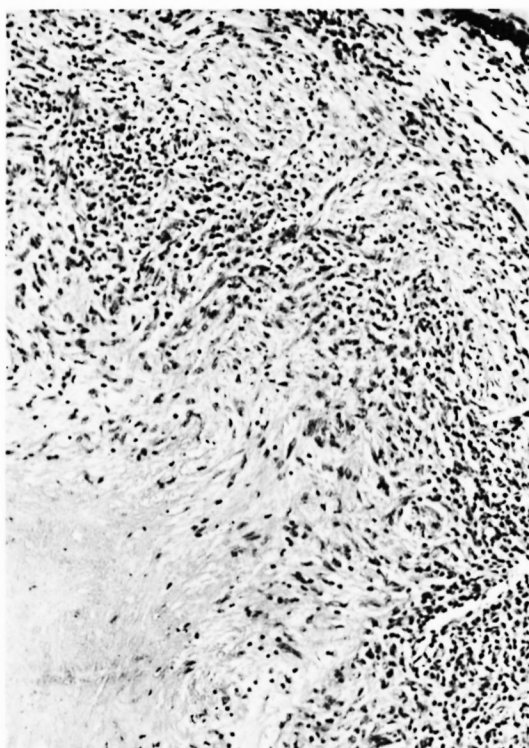


FIG. 2. Characteristic cellular infiltrate of epithelioid cells and lymphocytes around the zone of caseous necrosis (HE  $\times$  130).

appeared to be collagen fibers. Bacilli were identified in all of the 5 nerves that had foci of calcification within the necrotic area. More than 15 bacilli were seen in 2 of them while in the other 3 there were 2 or 3 bacilli.

The cellular reaction in each of the nerve lesions was a granulomatous one, characterized by an ill-demarcated zone of many epithelioid cells and a small number of Langhans' giant cells around a central area of caseous necrosis (Figs. 1 and 2). Peripheral to this there were moderate numbers of lymphocytes often associated with occasional plasma cells. Neutrophils and eosinophils were very sparse.

#### DISCUSSION

Although nodular necrotizing neuritic lesions in leprosy are fairly uniform clinically as well as in gross appearance, there are definite histological differences between groups of such cases. Published reports of "nerve abscesses in leprosy" have concerned essentially two types of lesions. The

vast majority of such cases are associated with tuberculoid disease and are characterized by segmental involvement of peripheral nerves with a central area of caseous necrosis surrounded by granulomatous inflammation. Much less frequently, "nerve abscesses" occur in lepromatous leprosy and are the result of either intraneural erythema nodosum leprosum (ENL) (7, 15) or focal necrosis in an intraneural lepromatous granuloma (4, 6, 16). An intraneural lepromatous granuloma probably becomes necrotic as a result of expansile growth within the confines of the perineural sheath. Sufficient compression of intraneural blood vessels then leads to isochemic necrosis. Differences in the inflammatory cellular response that have been reported in such lesions (15) probably represent phases in their evolution. Iatrogenic necrotizing neuritic lesions have also been reported (3).

Despite differences in histopathological expression and in all probability in pathogenesis, all necrotizing nodular lesions of nerves in leprosy have in the past been collectively referred to as "nerve abscess in leprosy." We feel this term is misleading, particularly for the caseating granulomatous neuritis of tuberculoid (BT and TT) leprosy patients, which constitutes the vast majority of such lesions and is the subject of this study. For one, these are not true abscesses because abscesses by definition are localized collections of pus, usually the result of a pyogenic infection in a solid organ (14, 19, 21). Second, although these lesions may grossly resemble the cold abscess of tuberculosis, in actual practice the term cold abscess "is reserved exclusively" for tuberculosis (20). We feel therefore that the term "nerve abscess of leprosy" should be supplanted by one that indicates the nature and pathogenesis of this lesion more precisely. Unfortunately, its pathogenesis is still shrouded by incomplete understanding. It is, however, a distinctive lesion, not to be confused with the necrotizing neural lesions seen in lepromatous leprosy, and therefore, until more is known about its pathogenesis, we suggest that it be called segmental necrotizing granulomatous neuritis of leprosy (SNGN)—a name that is accurate although only descriptive.

Reports from the Philippines (18), Japan (16), Nigeria (2, 13), U.S.A. (3), and India



(5,9,17,18) indicate that SNGN has no geographic proclivity. The incidence of SNGN has been variously estimated as being 2% of all leprosy patients (18), 1 in 5000 (1) and 0.25% (17). Our cases accounted for 0.25% of all leprosy patients. There was a marked preponderance of SNGN in males as against females. The age of the majority of patients when they presented for treatment was in the 2nd to 4th decades.

The patients presented from 6 months to 8 years after the onset of symptoms, but the majority (70%) were first examined within 2 years of the onset of symptoms.

The peripheral nerve trunk most prone to develop SNGN was the ulnar nerve just above the medial epicondyle of the humerus, with a greater predilection for the right ulnar nerve than the left. The next most common site was the radial cutaneous nerve. In only two instances was a cutaneous nerve in relation to a dermal patch the site of SNGN.

It is well known that *M. leprae* selectively affect nerve trunks at sites where they take a superficial course. The relatively lower environmental temperature as well as the higher risk of nerves in a superficial location to trauma are cited as decisive factors in this predilection (11). In this study the right ulnar nerve was affected twice as often as the left. Since most individuals are right handed, the greater exposure of the right ulnar nerve to trauma might account for its greater vulnerability.

The signs and symptoms manifested by a given case appear to be determined by the cross-sectional extent of the necrotizing granulomatous lesion and the type of nerve that is involved. Incision and drainage of the necrotic contents of the lesion is said to be invariably followed by a regression of edema and inflammation in the surrounding zone with consequent relief of many of the symptoms and at least partial recovery of function (10). The recovery may occasionally be dramatic. This is well exemplified by one of our cases who, on discharge, 23 days after a SNGN of the lateral popliteal nerve was drained, showed complete recovery from the foot drop with which he had presented. In some cases, SNGN may be the only clinical manifestation of leprosy (5,9).

One interesting feature that has emerged

from this study is the high frequency with which AFB can be identified by a careful examination of adequately stained sections of SNGN. While earlier reports are at variance on this matter, Lowe in 1934 (9) stated that AFB could be found in small numbers in 50% of such cases. In the present study, we were able to identify AFB in as many as 76.6% of our cases.

The pathogenesis of SNGN eludes facile explanation. The Ridley-Jopling classification of leprosy is based upon the premise that interaction between *M. leprae* and the human host takes place at an immunological level mediated by lymphocytes and monocytes. Caseation necrosis appears to be the consequence of delayed type hypersensitivity in diseases such as tuberculosis (12). It is recognized that in BT and TT leprosy, caseation necrosis occurs in major nerve trunks as well as on occasion in the skin. It is probable that caseation necrosis occurring in leprosy is also on the basis of delayed type hypersensitivity and is directed to antigens of *M. leprae*. In this study, SNGN with its characteristic focal necrosis occurred more frequently in BT than in TT leprosy. It seems that BT patients are more prone to develop delayed type hypersensitivity reactions to *M. leprae* antigens than TT patients. It is likely that the four patients whose skin biopsies showed features of the indeterminate type of leprosy were in a stage of evolution to the BT form; however, with the nonavailability of followup evaluations of these patients, this remains conjectural.

#### SUMMARY

In leprosy, the occurrence of necrotizing nodular lesions in peripheral nerves is a relatively uncommon complication. Despite clinical and gross similarities, there are microscopical differences among groups of such cases, indicating that in all probability different pathogenetic mechanisms are operative. Furthermore, the vast majority of such cases are not true abscesses but are characterized by caseous necrosis and granulomatous inflammation. The traditional collective name "nerve abscess" is therefore inappropriate. Presented herein is an analytic study of 30 cases of the commonest variant, which we suggest should be called segmental necrotizing granuloma-

tous neuritis of leprosy (SNGN). This lesion commonly affects the right ulnar nerve just above the elbow and occurs most often in those with the borderline tuberculoid form of leprosy. It appears to represent the result of a hypersensitivity phenomenon marked by a preponderance of epithelioid cells rather than a reaction of immunity in which lymphocytes predominate. Acid fast bacilli were demonstrable in the lesion in 77% of cases.

### RESÚMEN

En la lepra, la ocurrencia de lesiones nodulares necrosantes en los nervios periféricos, es una complicación relativamente rara. No obstante las similitudes clínicas gruesas, hay diferencias microscópicas entre grupos de individuos con esa complicación que sugieren la participación de diferentes mecanismos patogénicos. Además, la gran mayoría de los casos no son verdaderos abscesos sino lesiones caracterizadas por necrosis caseosa e inflamación granulomatosa. El término tradicional y colectivo de "absceso nervioso" es, por lo tanto, inapropiado. Aquí se presenta un estudio analítico de 30 casos de la variedad más común la cual, sugerimos, debe ser llamada neuritis granulomatosa necrosante segmental de la lepra. Esta lesión afecta comunmente al nervio ulnar derecho, precisamente por arriba del codo, y se presenta con más frecuencia en los casos de la lepra intermedia cercana a la tuberculoide (borderline tuberculoide). Parece ser el resultado de un fenómeno de hipersensibilidad caracterizado por una preponderancia de células epitelioideas más que una reacción de inmunidad en la cual predominan los linfocitos. En el 77% de los casos se demostraron bacilos en las lesiones.

### RÉSUMÉ

L'apparition dans la lèpre de lésions nodulaires nécrosantes dans les nerfs périphériques constitue une complication relativement peu fréquente. Malgré des similitudes cliniques et macroscopiques, on observe des différences microscopiques selon les groupes de cas. Ceci indique qu'en toute probabilité, des mécanismes pathogènes différents sont à l'oeuvre. De plus, la grande majorité de ces cas ne présentent pas d'abcès vrais, mais sont plutôt caractérisés par la présence de nécroses caséuses et d'une inflammation granulomateuse. Le terme collectif habituellement utilisé d'"abcès nerveux," est dès lors inapproprié. On présente ici l'analyse de 30 cas de la variété la plus commune, à laquelle les auteurs proposent d'appliquer le nom de "névrite granulomateuse nécrosante segmentaire de la lèpre." Cette lésion atteint généralement le nerf cubital droit, juste au-dessus du coude, et survient plus fréquemment chez les malades souffrant de la forme tuberculoide borderline de la maladie. Elle paraît représenter le résultat d'un phénomène

d'hypersensibilité marqué par la prépondérance de cellules épithélioïdes plutôt qu'une réaction d'immunité dans laquelle les lymphocytes prédomineraient. On pu démontrer la présence de bacilles acido-résistants au niveau de la lésion dans 77% de ces cas.

**Acknowledgements.** We are grateful to Mr. Ameer Baig for technical assistance and to the secretarial staff of the Norman Institute of Pathology for help rendered in preparing this manuscript.

### REFERENCES

1. BROWNE, S. G. Leprous nerve abscess. Report of two cases. *Lepr. Rev.* **28** (1957) 20-24.
2. BROWNE, S. G. Nerve abscesses in African leprosy. *Lepr. Rev.* **36** (1965) 55-57.
3. ENNA, C. D. and BRAND, P. W. Peripheral nerve abscess in leprosy. Report of three cases encountered in dimorphous and lepromatous leprosy. *Lepr. Rev.* **41** (1970) 175-180.
4. GHOSH, S. and KUNDU, S. K. Nerve abscess in lepromatous leprosy. *Lepr. India* **41** (1969) 11-13.
5. GUPTA, R. L. Giant nerve abscesses in leprosy. Case report. *Lepr. India* **34** (1962) 205-206.
6. HIRAKO, T. On the caseation necrosis found in the nerve of a lepromatous patient. *La Lepro* **24** (1955) 260. cited by Sato, S. (1956).
7. JOB, C. K. and BHAKTAVIZIAM, C. Nerve abscess in lepromatous leprosy—report of a patient. *Lepr. Rev.* **38** (1967) 243-247.
8. JOB, C. K., SELVAPANDIAN, A. J. and KURIAN, P. V. *Leprosy diagnosis and treatment*. 2nd ed. New Delhi: Hind Kusht Nivaran Sangh, 1975, pp. 21-22.
9. LOWE, J. A further note on nerve abscess in leprosy. *Int. J. Lepr.* **2** (1934) 301-304.
10. MUIR, E. Nerve abscess in leprosy. *Indian Med. Gaz.* **59** (1924) 87-89.
11. PEARSON, J. M. H. and ROSS, W. F. Nerve involvement in leprosy. Pathology, differential diagnosis and principles of management. *Lepr. Rev.* **46** (1975) 199-212.
12. POOLE, J. C. F. and FLOREY, H. W. Chronic inflammation and tuberculosis. In: *General Pathology*, Florey, H. W., ed., London: Lloyd-Lukes Ltd., 1970, pp. 1183-1224.
13. PRIESTMAN, F. G. Nerve abscess in Northern Nigeria. *Lepr. Rev.* **38** (1967) 35-36.
14. ROBBINS, S. L. *Pathologic Basis of Disease*. Philadelphia: W. B. Saunders Company, 1974, p. 86.
15. ROY CHOUDHURY, S. B. and SRINIVASAN, H. Nerve abscess in lepromatous leprosy. A case report and a discussion of pathogenesis. *Lepr. India* **49** (1977) 330-338.
16. SATO, S. Nerve abscess in lepromatous leprosy. Report of a case with a review of reports of nerve abscess in Japan. *Int. J. Lepr.* **24** (1956) 408-418.
17. SEHGAL, V. N., TULLI, S. M. and DUBE, B. Lep-

- rotic nerve abscess in Northern India. *Int. J. Lepr.* **35** (1967) 60-64.
18. WADE, H. W. Tuberculoid changes in leprosy. III. The pathology of a nerve abscess. *Int. J. Lepr.* **2** (1934) 293-300.
19. WALTER, J. B. and ISRAEL, M. S. *General Pathology*. 4th ed. Edinburgh: Churchill Livingstone, 1974, p. 78.
20. WALTER, J. B. and ISRAEL, M. S. *General Pathology*. 4th ed. Edinburgh: Churchill Livingstone, 1974, pp. 246-247.
21. WILLIS, R. A., *The Principles of Pathology*. London: Butterworth and Company, 1950, p. 50.