

## The Histopathology of the Spleen from a Patient with Lepromatous Leprosy<sup>1,3</sup>

Thomas H. Rea, Lynn Bevans, and Clive R. Taylor<sup>2</sup>

Study of the histopathology of leprosy has been fundamental to the present understanding of the disease. Of particular importance has been the work of Ridley and coworkers (<sup>14,15</sup>). Their correlative clinical and histological study of skin lesions not only provided substantial evidence that host resistance to *Mycobacterium leprae* was crucial in determining the diverse expressions of leprosy but also established a system of classification basic to many types of studies, including immunological investigation. Anatomical pathology has also provided important clues to understanding the immunopathology of leprosy, as exemplified by the study of Turk and Waters (<sup>18</sup>), in which the observation of replacement of paracortical areas (T-cell zones) by histiocytes provided an anatomical framework for understanding the generalized impairment of cell-mediated immune (CMI) responsiveness sometimes observed in lepromatous leprosy.

The present paper is a report of the histopathology of a spleen from a young man with lepromatous leprosy, splenectomy being occasioned by traumatic rupture. Earlier work by Bullock, *et al.* showing depletion of T lymphocyte subpopulations in the spleen in murine leprosy (<sup>5</sup>) together with recent demonstrations of suppressor

cell activity in patients with lepromatous leprosy (<sup>2,8</sup>), suppressor cells of splenic origin in murine leprosy (<sup>4</sup>), and periarteriolar infiltration by lepra cells in the spleen of a patient with lepromatous leprosy (<sup>3</sup>) emphasize the importance of the histopathology of the spleen in leprosy.

### CASE REPORT AND RESULTS

The patient, a 22 year old Mexican man, presented in late April 1977 because of leg ulcers. At age 14 he had developed alopecia of the eyebrows and eyelids, and at age 15 a diagnosis of Hansen's disease was made. Sulfones were taken irregularly from age 15 to 21, but not at all in the year preceding his initial presentation to our clinic.

Pertinent physical findings included alopecia of the eyebrows and eyelashes, perforation of the nasal septum, seven leg ulcers measuring from one to three cm in diameter, approximately a dozen barely palpable, irregular hemorrhagic lesions on the legs and thighs, and the absence of any nodular lesions. Acral, distal symmetrical anesthesia was present on the hands, but muscle atrophy and trophic change in the skin were not evident.

The histological changes in a hemorrhagic lesion were characteristic of lepromatous leprosy and Lucio's reaction, i.e., perivascular accumulations of foamy histiocytes, ischemic necrosis of the epidermis, endothelial proliferation in some mid-dermal vessels, and numerous acid-fast bacilli (AFB) both in histiocytes and in some normal or proliferating endothelial cells (<sup>11</sup>).

Tuberculin testing with five units of PPD elicited 40 mm of intense induration at 48 hr, but chest X-ray and urinalysis were normal, and cultures of sputum and urine were negative for mycobacterial species. Attempted dinitrochlorobenzene sensitization, using a 2 mg sensitizing dose and a challenge of 0.1 mg at 21 days, failed. Serum IgA was 600 mg/l (normal upper limit 400 mg), but IgG and IgM were normal; se-

<sup>1</sup> Received for publication on 2 January 1980; accepted for publication in revised form on 24 March 1980.

<sup>2</sup> T. H. Rea, M.D., Section of Dermatology, Department of Medicine, University of Southern California School of Medicine and Department of Dermatology, Los Angeles County-University of Southern California Medical Center; L. Bevans, M.D. (deceased); C. R. Taylor, M.B., Ch.B., D.Phil., Department of Pathology, University of Southern California School of Medicine and Department of Pathology, Los Angeles County-University of Southern California Medical Center, Los Angeles, California 90033, U.S.A. All correspondence to Dr. Rea.

<sup>3</sup> This material was presented in part by Dr. Bevans before the annual meeting of the California Society of Pathologists on 8 December 1977 in San Diego, California, U.S.A.

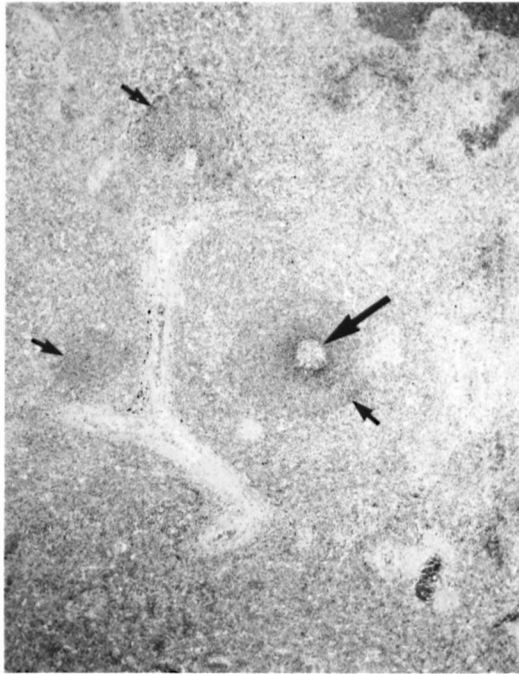

FIG. 1. Section of spleen showing sparsely distributed small lymphocytes in the periarteriolar (T-cell) areas (small arrows). A focus of B-cell proliferation is represented by a small germinal center (large arrow). The white pulp is considerably reduced in extent by comparison to what might be expected in normal men of this age. (H & E,  $\times 32$ )

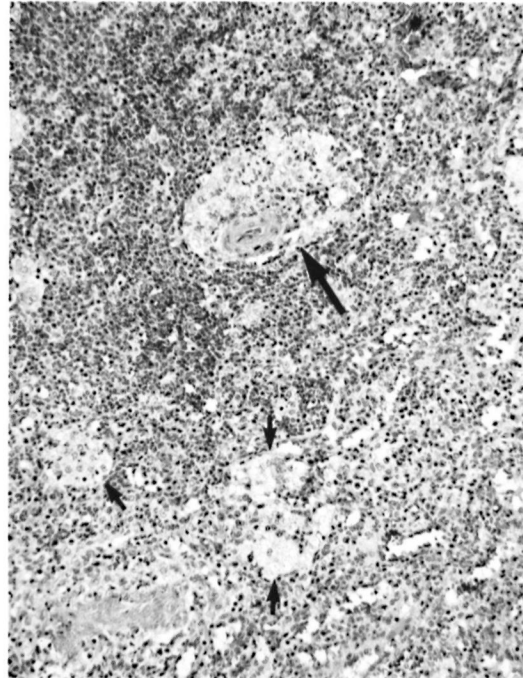


FIG. 2. Aggregates of lepra cells about an arteriole (large arrow) and in the red pulp (small arrows). (H & E,  $\times 135$ )

rum total hemolytic complement (CH50) was 160 units (normal 480–1280)\*; serum cryoglobulins were 29 mg/100 ml (normal  $<3$  mg). Lysozyme was 13.8 ng/ml (normal  $7.7 \pm \text{S.D. } 1.5$ ), and angiotensin-converting enzyme was 33.2 units/ml (normal  $22.6 \pm \text{S.D. } 6$ ).

The patient was begun on dapsone, 50 mg daily. New hemorrhagic lesions ceased within one week of beginning dapsone, and his ulcers began to show good granulation tissue.

After four weeks of observation the patient was lost to follow up for two months. In late July 1977 he was admitted to the surgical service because of two stab wounds in the left side of the chest. Pneumonia was a complication of this injury. While convalescing from pneumonia, painful and tender, red, subcutaneous and dermal nodules erupted in association with

fever and malaise. Biopsy supported the clinical impression of erythema nodosum leprosum (ENL), and this syndrome remitted in association with thalidomide therapy. His leg ulcers had healed. Serum hemolytic complement was 240 units at that time. In late August 1977 the patient was once again admitted to the surgical service, on this occasion because of a ruptured spleen, sustained when beaten severely with a metal pipe. Splenectomy was performed without incident. The patient was seen in the clinic two weeks later, taking only dapsone and having no lesions of ENL. He was lost to follow up thereafter.

The spleen weighed 294 g and measured  $15 \times 9 \times 6$  cm. Hemorrhagic material was present on the hilar surface. The surface was slightly wrinkled and grey to purple in color. Three lacerations, 3, 6, and 10 cm long, were identified. On section, focal areas of hemorrhage were present. Grossly, changes attributable to leprosy were not evident.

Histopathologically, fresh hemorrhage was apparent in many areas but did not ap-

\* Editor's Note: Method used in authors' laboratory.

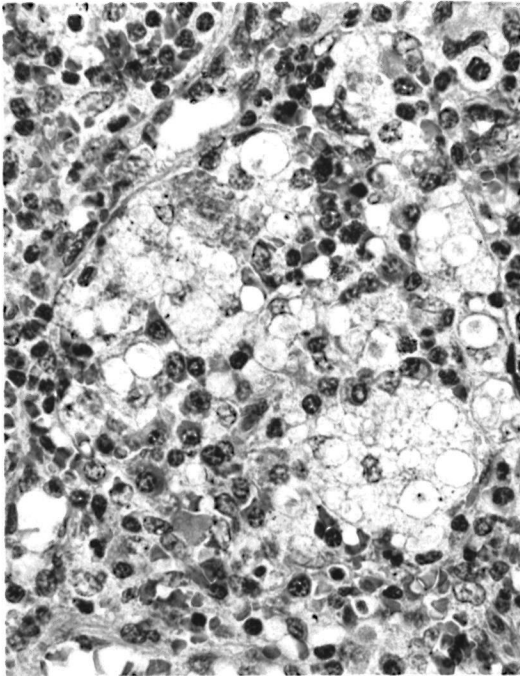


FIG. 3. An aggregate of lepra cells in a cord containing many plasma cells (H & E,  $\times 540$ )

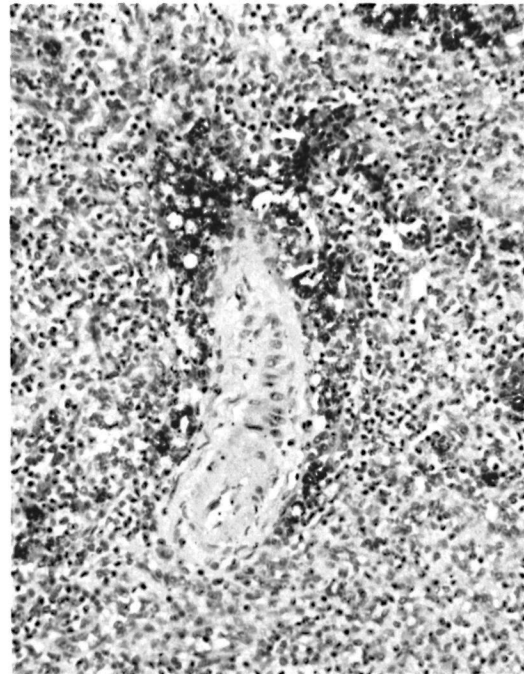


FIG. 4. Lepra cells in a perithelial distribution about an arteriole. Bacilli appear as dark cytoplasmic granules. (Fite-Farraco,  $\times 250$ )

pear to have any influence upon the other microscopic changes reported herein.

Germinal centers were numerous but were not large. They were distributed throughout the white pulp, which was, however, markedly reduced in total amount. In particular, periarteriolar lymphocytes, in the "T" cell zone, were reduced in number although small collections were still present about some vessels (Fig. 1).

Lepra cells (Virchow cells or large vacuolated histiocytes), containing large numbers of acid-fast bacilli (AFB) and globi, were abundant. They were found as aggregates in the cords of the red pulp, without discernible relationship to the arteriolar tree (Figs. 2 and 3), as periarteriolar aggregates in the white pulp (Figs. 2 and 4), and as evidently nonaggregated cells in germinal centers (Fig. 5). In general, lepra cells were most abundant in the red pulp, comparatively less common about arterioles, and sparse in germinal centers.

In the red pulp, collections of lepra cells frequently contained large numbers of plasma cells (see Fig. 3) showing a polyclonal pattern of immunoglobulin by immunoperoxidase methods. Plasma cells, eosino-

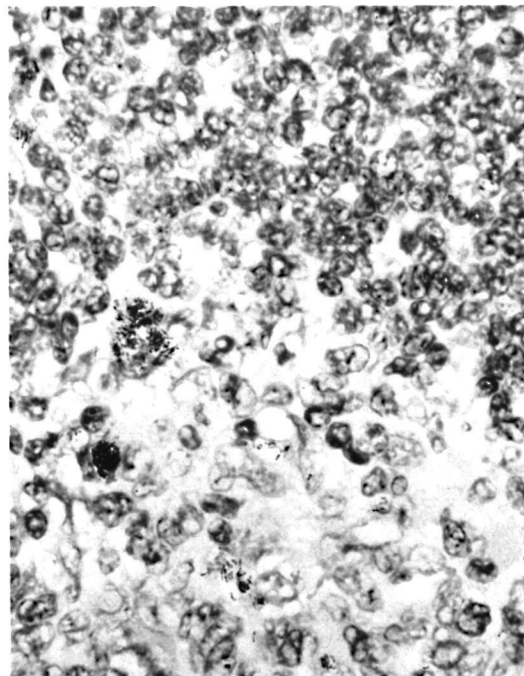


FIG. 5. Large vacuolated histiocytes containing bacilli are present in this field from a germinal center. The bacilli in this particular field, ideal for illustration, are present in greater numbers than found in most other germinal centers. (Fite-Farraco,  $\times 800$ )

phils, and neutrophils were present in the red pulp in larger numbers than normal.

In the white pulp the aggregated lepra cells localized to the perithelium (Figs. 2 and 4). When well developed, the lepra cells formed a periarteriolar cuff. Often only an incomplete arc was involved. In arterioles sectioned horizontally only one side might be infiltrated by lepra cells.

In germinal centers a few large vacuolated histiocytes (perhaps lepra cells) containing AFB were identified (Fig. 5). It was difficult to determine if these cells were truly not aggregated or were so few in number as to give that appearance. The number of bacilli in these cells was usually smaller than those seen in the periarteriolar or red pulp lepra cells.

Many lepra cells contained a hemosiderin-like pigment and stained positively for iron. Also these cells stained positively for oil-red O. With immunoperoxidase staining, the lepra cells of the spleen stained positively (one plus on a scale of four) for lysozyme, showing the same saccular morphology previously demonstrated in lepra cells in lepromatous lesions of the dermis<sup>(13)</sup>. Congo red staining for amyloid was negative as judged by light and fluorescence microscopy.

#### DISCUSSION

The present case appears to represent a comparatively early phase in the normally protracted course of lepromatous leprosy. Although our patient was not untreated, his therapy had been intermittent. He had had Lucio's phenomenon, a syndrome associated with active lepromatous leprosy<sup>(11)</sup>, four months preceding splenectomy. Amyloid, a usual finding in the spleen post-mortem of patients with long-standing lepromatous leprosy<sup>(1,6,9,10)</sup>, was not found in the present case.

Prior reports of the histopathology of the spleen in leprosy, autopsy cases or series, indicate that some of the changes observed herein are representative of the spleen in lepromatous leprosy. In his paper on the lepra cell, Mitsuda describes "leprotic foci" as being numerous "in the region of the splenic arteries" and that lepra cells "are seen . . . in the perithelium of the arteries"<sup>(9)</sup>. Red pulp and germinal center involvement were also found. Furthermore,

the earliest change in the spleen was said to be the perithelial lepra cells.

Powell and Swan<sup>(10)</sup> found "miliary lepromas," consisting of "vacuolated histiocytes . . . located in every part of the parenchyma in both the red and white pulp, often around blood vessels." Likewise, Desikan and Job<sup>(6)</sup> found "discrete lepromatous granulomata, scattered in both the red and white pulp"; their photomicrograph clearly shows a periarteriolar localization of histiocytes.

Sifuentes Guerrero, *et al.*<sup>(17)</sup> reported a patient in whom the diagnosis of lepromatous leprosy was not established prior to her terminal illness, renal failure. In this patient's spleen large histiocytes containing AFB were noted (and pictured) about the splenic arterioles. Sifuentes and Gomez<sup>(16)</sup> reported the necropsy of a patient who died of pulmonary emboli a few months after the diagnosis of Lucio's reaction and diffuse non-nodular lepromatous leprosy was made. They found the spleen to contain focal infiltrations of histiocytes. (Dr. Sifuentes kindly sent hematoxylin and eosin stained sections of this spleen to us for review. There were no germinal centers, and there was marked depletion of lymphocytes in the periarteriolar areas. Aggregates of large vacuolated histiocytes were present in the red pulp and about arterioles, as in the present case.) Bullock recently published an illustration of periarteriolar histiocytic infiltration but reported no details<sup>(3)</sup>.

Another report of splenic involvement in leprosy did not comment critically upon the presence or absence of periarteriolar histiocytic infiltration<sup>(1)</sup>. The photomicrographs of Powell and Swan<sup>(10)</sup> and of Bernard and Vazquez<sup>(1)</sup> show amyloid in a periarteriolar pattern.

Germinal centers containing large vacuolated histiocytes with AFB were previously seen by Mitsuda<sup>(9)</sup>, who describes reticulum cells of the spleen follicles turning into lepra cells. Other reports make no mention of germinal centers, suggesting that they are an early change in leprosy, disappearing with progression of the disease or effaced by terminal illnesses. Mitsuda<sup>(9)</sup> regarded the follicular lepra cells as multiplying, finally causing atrophy of the follicles. There is no evidence to associate the AFB laden histiocytes with the large

dendritic reticulum cells of the germinal centers. However, the absence of aggregation and the fewer numbers of bacilli do suggest that the AFB-containing cell of the germinal center may differ in origin or physiologic activity from the periarteriolar or red pulp lepra cell.

Periarteriolar infiltration by histiocytes is not restricted to lepromatous leprosy. Lukes states that in Letterer-Siwe's disease the white pulp is replaced by "nodules of histiocytes that circumscribe the central artery" (7). Furthermore, we have noted periarteriolar large vacuolated histiocytes in two of seven spleens in necropsy material from patients with disseminated coccidioidomycosis (12). More generally well recognized types of granulomas may involve the white pulp or red pulp, with any of their characteristic features (7).

Using the term lepromatous leprosy to include only the polar and subpolar types as delineated by Ridley (14,15), the prevalence of splenic involvement in lepromatous leprosy is not known. Earlier necropsy series probably employed the term "lepromatous" in a broader sense and may well have included patients who today would be classified as borderline with lepromatous features. The cases reported by Sifuentes and Gomez (16), and Sifuentes Guerrero, *et al.* (17), as well as the present case, were lepromatous by Ridley's criteria, suggesting that splenic involvement is usual in lepromatous disease, as defined by Ridley.

Histiocytes containing AFB were demonstrated in germinal centers, foci of B-cell proliferation about arterioles, sites of T-cell "homing"; and in the red pulp, where a wide variety of cells course. Thus the spleen provides ample opportunity for close contact between *M. leprae* and the central cells of the immunologic response, namely the T and B lymphocytes and cells of the monocyte series. However, the precise sequence of immunological changes that might occur as a result of particular alterations in the spleen in leprosy remains speculative. The perithelial infiltration of lepra cells around splenic arterioles appears to be analogous to the paracortical infiltration by histiocytes in lymph nodes, as reported by Turk and Waters (18). However, the mechanism through which such an infiltration might lead to impaired CMI res-

ponsivity is uncertain; decreased effector or helper activity or increased suppressor activity represent possibilities for future study. These anatomical changes are conveniently thought of as necessary but not sufficient conditions for modulation of immune responsiveness in the lepromatous patient.

#### SUMMARY

The histopathology of the spleen from a young man with diffuse non-nodular lepromatous leprosy is reported. As judged by this case, other case reports, and necropsy series, involvement of the spleen in lepromatous leprosy is characterized by aggregations of large vacuolated histiocytes, containing individual bacilli and globi, in both the red and white pulp. In the white pulp the histiocytes localize about the arterioles. Findings in the present case, which may represent a comparatively early change, include numerous, small germinal centers containing nonaggregated large, vacuolated histiocytes with intracellular bacilli.

#### RESUMEN

Se describe la histopatología del bazo de un joven con lepra lepromatosa difusa (no nodular). A juzgar por este caso, por otros casos publicados, y por las necropsias efectuadas, la afección del bazo en la lepra lepromatosa está caracterizada por la agregación de histiocitos grandes y vacuolados, conteniendo bacilos individuales y globi tanto en la pulpa blanca como en la roja. En la pulpa blanca, los histiocitos se localizan alrededor de las arteriolas. Los hallazgos en el caso aquí presentado, los cuales pueden representar cambios relativamente tempranos, incluyen numerosos centros germinales pequeños conteniendo grandes histiocitos vacuolados no agregados, con bacilos intracelulares.

#### RÉSUMÉ

On rapporte l'observation histopathologique de la rate chez un homme jeune atteint de lèpre lépromateuse diffuse non-nodulaire. Pour autant que l'on puisse en juger sur la base de ce cas, sur d'autres rapports et sur des séries d'autopsies, l'atteinte de la rate dans la lèpre lépromateuse est caractérisée par la confluence d'histiocytes de grande dimension et vacuolés, contenant des bacilles individuels et des globi, à la fois dans la pulpe rouge et dans la pulpe blanche. Dans la pulpe blanche des histiocytes sont localisés autour des artérioles. Les observations faites dans ce cas, qui témoignent peut-être de modifications relativement précoces, font état de nombreux petits

centres germinatifs contenant des histiocytes de grande dimension, vacuolés, et contenant des bacilles intracellulaires, mais ne présentant pas de confluence.

#### REFERENCES

1. BERNARD, J. C. and VAZQUEZ, C. A. J. Visceral lesions in lepromatous leprosy, study of sixty necropsies. *Int. J. Lepr.* **41** (1973) 94-101.
2. BJUNE, G. *In vitro* lymphocyte stimulation in leprosy; simultaneous stimulation with *Mycobacterium leprae* and phytohaemagglutinin. *Clin. Exp. Immunol.* **36** (1979) 479-487.
3. BULLOCK, W. E. Leprosy: a model of immunological perturbation in chronic infection. *J. Infect. Dis.* **137** (1978) 341-354.
4. BULLOCK, W. E., CARLSON, E. M. and GERSHON, R. K. The evolution of immunosuppressive cell populations in experimental mycobacterial infection. *J. Immunol.* **120** (1978) 1709-1716.
5. BULLOCK, W. E., EVANS, P. D. and WYATT, C. R. Depletion of lymphocyte subpopulations in the spleen by murine leprosy. *Int. J. Lepr.* **42** (1974) 368.
6. DESIKAN, K. V. and JOB, C. K. A review of post-mortem findings in 37 cases of leprosy. *Int. J. Lepr.* **36** (1968) 32-44.
7. LUKES, R. J. The pathology of the white pulp of the spleen. In: *Die Milz/The Spleen*. Lennert, K. and Harms, D., eds. Berlin: Springer Verlag, 1970, pp. 129-138.
8. MEHRA, V., MASON, L. H., FIELDS, J. P. and BLOOM, B. R. Lepromin-induced suppressor cells in patients with leprosy. *J. Immunol.* **123** (1979) 1813-1817.
9. MITSUDA, K. The significance of the vacuole in the Virchow lepra cells and the distribution of lepra cells in certain organs. *Int. J. Lepr.* **4** (1936) 491-511 (reprinted from Tokyo Journal of Medical Affairs).
10. POWELL, C. S. and SWAN, L. L. Leprosy: pathologic changes observed in fifty consecutive necropsies. *Am. J. Pathol.* **31** (1955) 1131-1147.
11. REA, T. H. and RIDLEY, D. S. Lucio's phenomenon: a comparative histological study. *Int. J. Lepr.* **47** (1979) 161-166.
12. REA, T. H. and TAYLOR, C. R. Changes in the spleen in disseminated coccidioidomycosis and leprosy. *Clin. Res.* **27** (1979) 42A.
13. REA, T. H. and TAYLOR, C. R. Serum and tissue lysozyme in leprosy. *Infect. Immun.* **18** (1977) 847-856.
14. RIDLEY, D. S. and JOPLING, W. H. A classification of leprosy for research purposes. *Lepr. Rev.* **33** (1962) 119-128.
15. RIDLEY, D. S. and WATERS, M. F. R. Significance of variations within the lepromatous group. *Lepr. Rev.* **40** (1969) 143-152.
16. SIFUENTES, J. and GOMEZ, J. J. Lepra visceral: estudio anatomoclinico de un caso. *Dermatologia Revista Mexicana* **21** (1977) 190-202.
17. SIFUENTES GUERRERO, J., LAGUNES, R. B. and GONZALES, R. O. La lepra en Reynosa (44 casos clinicos y 1 de autopsia). *Patologia* **11** (1973) 99-110.
18. TURK, J. L. and WATERS, M. F. R. Immunological significance of changes in lymph nodes across the leprosy spectrum. *Clin. Exp. Immunol.* **8** (1971) 363-376.