

## Leprosy in a Chimpanzee. Postmortem Lesions<sup>1</sup>

Joel R. Leininger, Kelley J. Donham, and Wayne M. Meyers<sup>2</sup>

In previous reports we described the clinical (<sup>1</sup>) and microscopic (<sup>10</sup>) features of skin lesions and results of tests to identify the infecting agent of a naturally-acquired disease in a chimpanzee that closely resembled lepromatous leprosy in man. The acid-fast bacilli (AFB) in the skin lesions were indistinguishable from *Mycobacterium leprae* with the exception that in initial studies they did not oxidize dihydroxyphenylalanine (dopa).

The chimpanzee was purchased from an animal supply company (Primate Imports, Inc., New York, New York, U.S.A.) in October 1974. Their records indicated that he came from Sierra Leone, but further details regarding his background were sketchy or unavailable. He and seven other young chimpanzees were inoculated with bovine leukemia virus in December 1974. Leprosy-like lesions (macular rash) were first noticed two months later. The other chimpanzees did not develop gross or microscopic lesions.

The chimpanzee died thirty-three months after the first appearance of lesions. He had received no specific treatment for leprosy. To our knowledge, this is the first reported spontaneous case of leprosy or leprosy-like disease in a nonhuman primate. We here describe the lesions found at postmortem examination.

### MATERIALS AND METHODS

The chimpanzee died inadvertently on 9 November 1977, following sedation with phencyclidine and ketamine, a procedure

that was performed routinely at 6 week intervals for 2½ years to obtain blood for concurrent studies. A necropsy was performed within 2 hr of death. Tissues were fixed in 10% neutral buffered formalin, embedded in paraffin, sectioned to 5  $\mu$ , and stained with hematoxylin-eosin (H & E), Ziehl-Neelsen (ZN), Fite-Faraco (FF), or Gomori's methenamine silver (GMS) stains. Fresh tissue was sent to the United States Public Health Service Hospital, Carville, Louisiana for determination of dopa oxidase activity of the AFB (<sup>15</sup>). Intact eyes were sent in formalin to the Armed Forces Institute of Pathology for histopathologic processing.

### RESULTS

**Gross lesions.** There was marked atrophy of skeletal muscles, alopecia, and diffuse thickening of the skin of the hands, feet, and digits (Figs. 1 and 2). Nodules on the ears and lips (Fig. 1) ranged from 0.75 to 1.5 cm in diameter, representing a diminution in size from those seen 1 year earlier (Fig. 3 and also Fig. 1, reference 10). Axillary and inguinal lymph nodes were large and yellow-tan. The soft palate and pharyngeal tissues were diffusely thickened and yellow-tan. The nasal passages were obstructed by thickened, yellow-tan turbinates. In the endocardium of the left atrium there was a brittle, linear, white band, approximately 3 cm by 1 cm, and there were similar lesions in the distal aorta. Other organs had no gross lesions.

**Microscopic lesions.** There were diffuse or multifocal infiltrations of foamy histiocytes in the dermis (Fig. 4). In some areas of the skin, especially the lip, focal collections of lymphocytes were scattered among the histiocytes. Globi, widely variable in size, ranging to 100  $\mu$  in diameter, were present in all skin sections (Fig. 5). The largest globi were in the ears and lips, sites of the earliest gross lesions.

The epidermis was thin, lacked rete ridges, and had various sized ulcers with neutrophils in the base and walls. There

<sup>1</sup> Received for publication on 7 April 1980; accepted for publication on 3 June 1980.

<sup>2</sup> J. R. Leininger, D.V.M., Ph.D., Assistant Professor; K. J. Donham, M.S., D.V.M., Associate Professor, Department of Preventive Medicine and Environmental Health, College of Medicine, University of Iowa, Oakdale, Iowa 52319, U.S.A.; W. M. Meyers, M.D., Ph.D., Director, Microbiology Division, Armed Forces Institute of Pathology, Washington, D.C. 20306, U.S.A. Dr. Leininger's present address, to which reprint requests should be sent, is Department of Veterinary Pathobiology, University of Minnesota, St. Paul, Minnesota 55108, U.S.A.

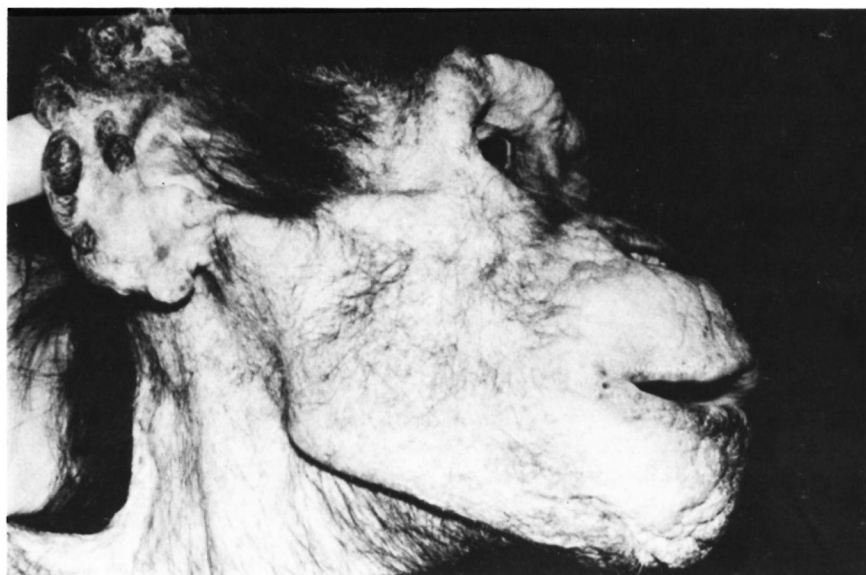

FIG. 1. Gross lesions on face of chimpanzee at autopsy consisting of hyperpigmented nodules on ears, thickened, wrinkled skin of lower lip, and muscle atrophy.

was generally a thin subepidermal clear-zone. There were AFB in histiocytes and in dermal nerves. The AFB occurred singly, in clumps, and in globi and stained much more intensely with the FF than with the ZN stains.

The nasal mucosa was heavily infiltrated

by a mixture of histiocytes, neutrophils, and lymphocytes. Large globi, identical to those in skin sections, were present (Fig. 6). The epiglottis was diffusely infiltrated; only in the deepest parts were mucous glands and collagen fibers present where they were widely separated by the infiltrat-

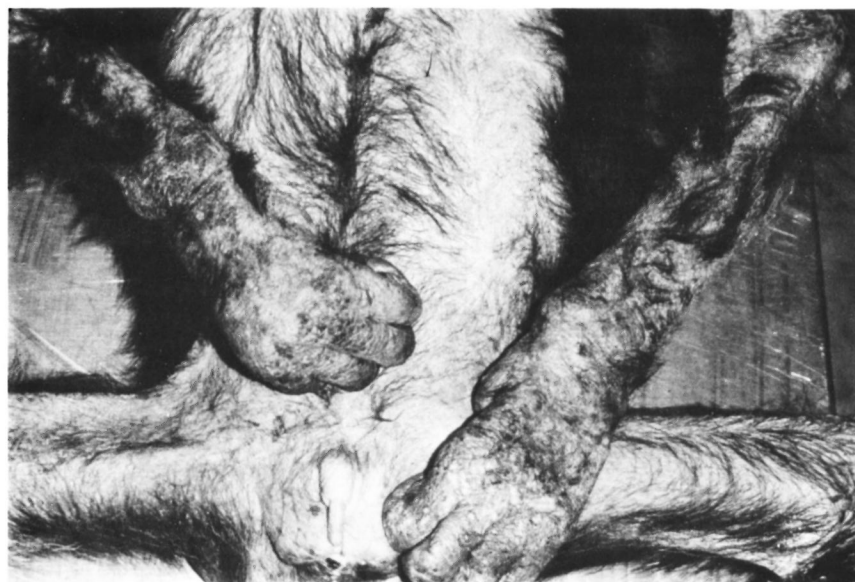

FIG. 2. Diffuse thickening of skin of hands and digits, patchy alopecia on forearms, and muscle atrophy of arms and thighs at necropsy.

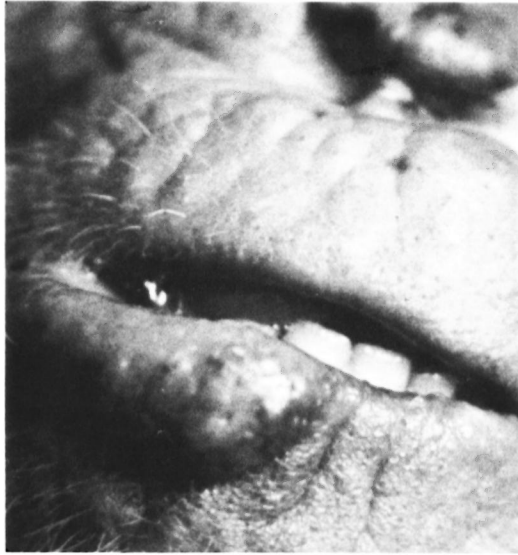

FIG. 3. Gross appearance of nodules on lower lip and nostrils 12 months before death. Lesions are larger than at necropsy, Fig. 1.

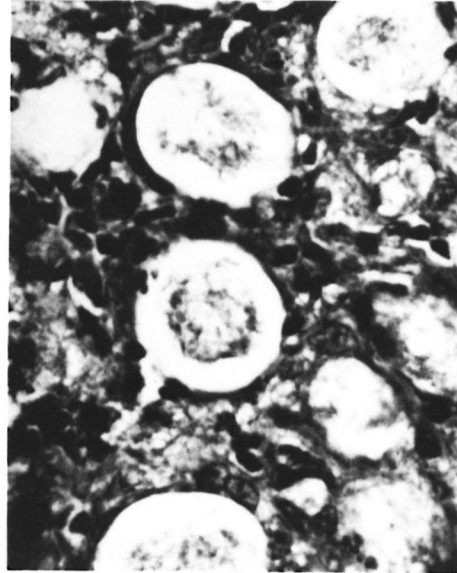


FIG. 5. Globi containing AFB (Ziehl-Neelsen,  $\times 512$ ).

ing cells. FF stained sections revealed only moderate quantities of AFB, but the GMS stained sections showed large masses of organisms (Fig. 7).

The lung interstitium was thickened by histiocytes and by patches of mineralization (Fig. 8). Eosinophils were frequently seen. Subpleural lung parenchyma was

consolidated focally by histiocytes and fibrosis. AFB were present in histiocytes but were fewer than in the skin and the upper respiratory tract.

The liver (Fig. 9) contained scattered lesions composed of histiocytes and hypertrophic Kupffer cells. The spleen (Fig. 10) contained histiocytes forming a sheath around the arterioles of the lymphoid folli-

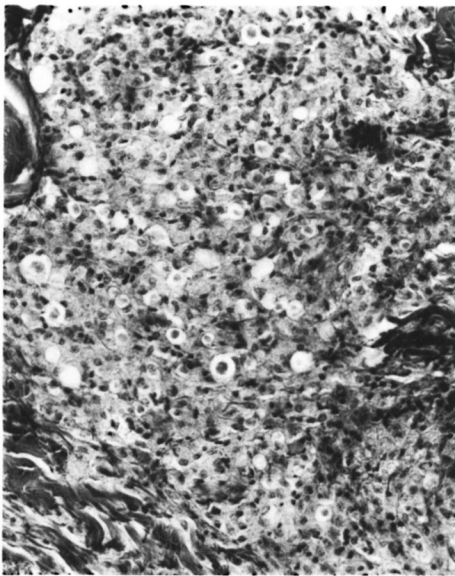


FIG. 4. Histiocytes and globi in dermis (H & E,  $\times 128$ ).

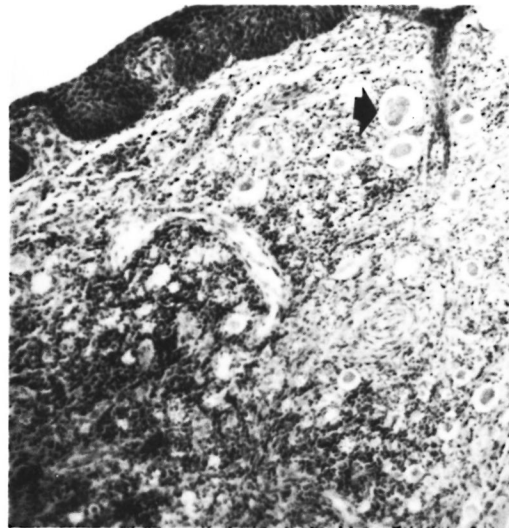

FIG. 6. Nasal mucosa. The subepithelial tissue is populated by histiocytes, lymphocytes, and several large globi (arrow) (H & E,  $\times 81$ ).

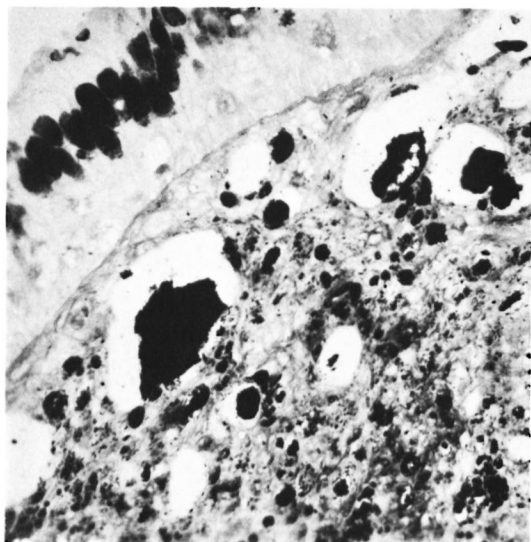


FIG. 7. Epiglottis. Dense masses of organisms are present in the submucosa (GMS,  $\times 250$ ).

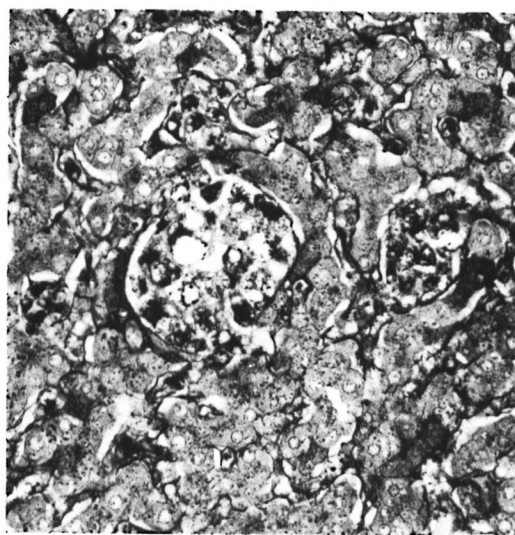


FIG. 9. Liver. Focal collection of histiocytes containing densely staining masses of organisms (GMS,  $\times 250$ ).

cles. AFB were abundant in the liver (Fig. 9) and spleen.

The kidneys had multiple intratubular collections of AFB and histiocytes in the deep layers of the cortex and medulla. Some glomeruli were slightly hypercellular. AFB were seen in very low numbers in glomeruli and were usually in the mesangial region.

Lymph node lesions consisted of virtual-

ly total replacement of normal structures by a uniform population of foamy histiocytes (Fig. 11). A thin rim of lymphocytes was usually present just inside the subcapsular sinus and in foci along cortical trabeculae. Large globi were present.

Multiple sections of nerves from the forearms showed segmental invasion by histiocytes, lymphocytes, and AFB. Connective tissue formed constrictive sleeves around

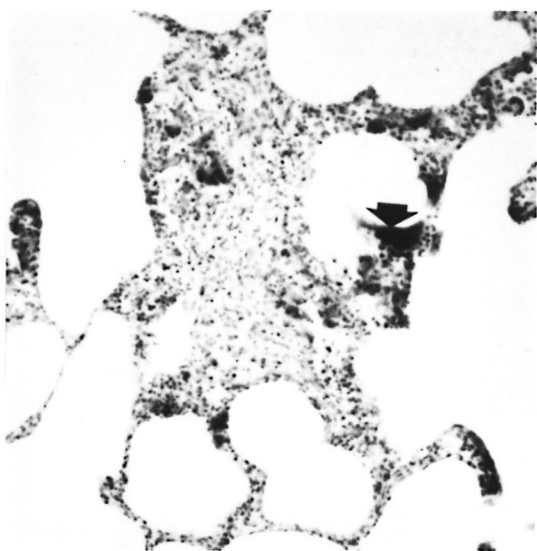


FIG. 8. Lung. Interstitium contains histiocytes and foci of mineralization (arrow) (H & E,  $\times 81$ ).

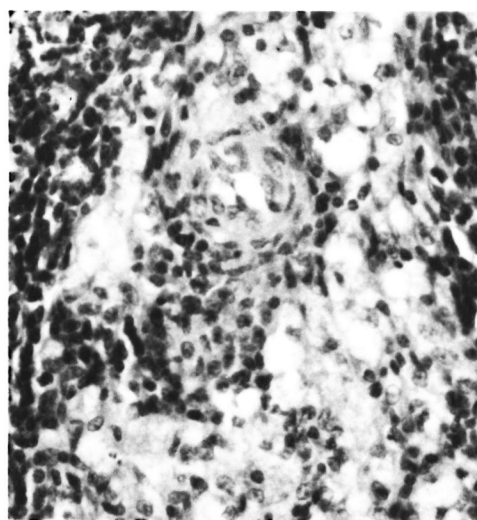


FIG. 10. Spleen. A periarteriolar sheath of histiocytes is in the lymphoid follicle, replacing lymphocytes (H & E,  $\times 477$ ).



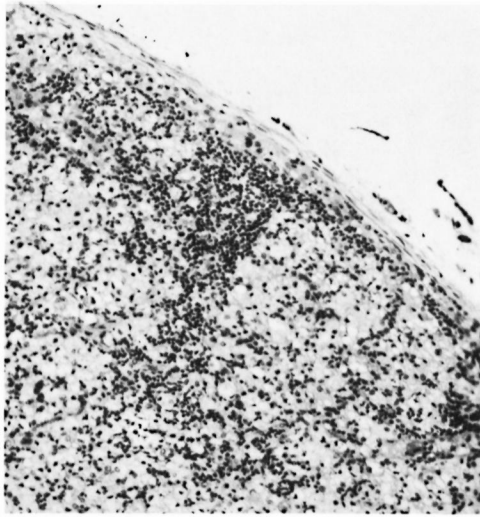


FIG. 11. Peripheral lymph node. Cortex heavily infiltrated by histiocytes (H & E,  $\times 100$ ).

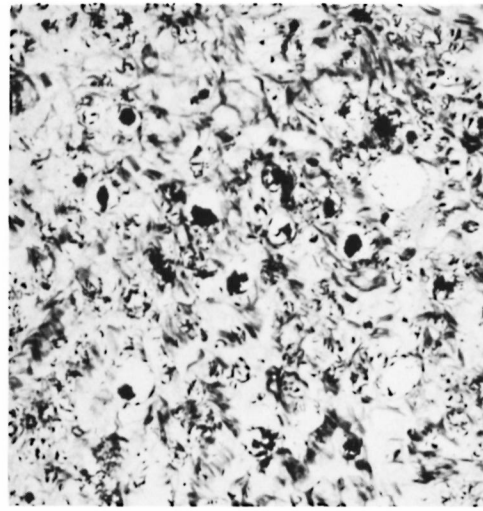


FIG. 13. Nerve, close-up of nerve fiber in Fig. 12 showing masses of organisms (GMS,  $\times 400$ ).

individual nerve fascicles (Fig. 12). AFB were present in very large numbers in nerves (Fig. 13).

Lesions present in both eyes consisted of histiocytic infiltration of the sclera, on the temporal side, near the corneoscleral junction (Fig. 14). The right eye also had macrophage infiltrations of the deep layers of the peripheral cornea, ciliary body, and iris. AFB were seen within histiocytes in all instances.

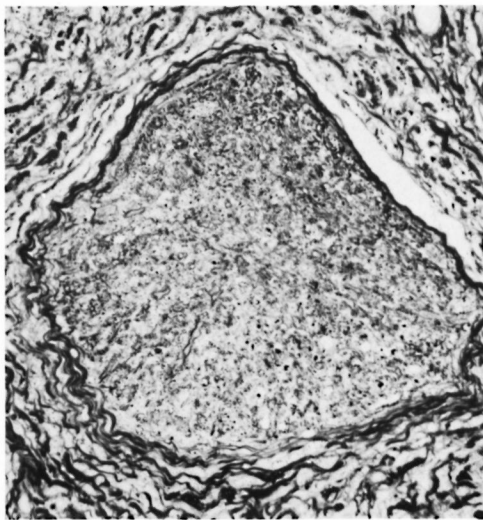


FIG. 12. Nerve from forearm. Extensive endoneurial fibrosis forming sleeve around nerve fiber (GMS,  $\times 100$ ).

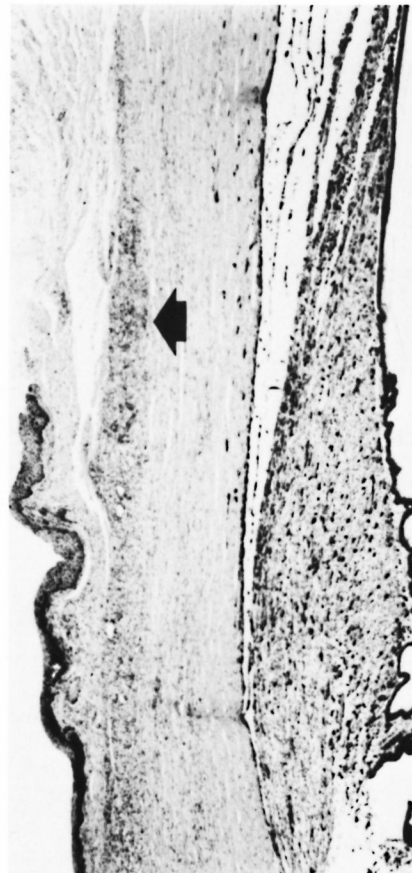

FIG. 14. Eye. Histiocytic infiltration in sclera (arrow) (H & E,  $\times 32$ ).

AFB and small numbers of histiocytes were in the testicular tunics and in the adjacent interstitium. Seminiferous tubules were hypoplastic with only Sertoli cells and multinucleated cells present.

The adrenal glands had a few AFB in vacuolated cells in the cortex.

Lesions in the endocardium and distal aorta consisted of multifocal necrosis with mineralization and lymphocytic infiltration. No AFB were seen in these areas.

#### DISCUSSION

The postmortem lesions in this chimpanzee were consistent with those reported for lepromatous leprosy in man<sup>(3, 5, 7, 12, 13, 14)</sup>. Lesions in the spleen, liver, testes, and adrenal glands are usually observed grossly in man<sup>(13)</sup>, but gross lesions in these organs were not observed in this chimpanzee.

The testes in men with advanced lepromatous leprosy are usually atrophic and extensively invaded by AFB-laden histiocytes<sup>(14)</sup>. There was no evidence of spermatogenesis in the testes of this chimpanzee, but this was probably due to sexual immaturity.

Interstitial histiocytic pneumonia, as seen in this chimpanzee, is considered uncommon in man<sup>(3, 14)</sup>; however, Mitsuda<sup>(12)</sup> did describe such lesions in some patients. The high incidence of pulmonary tuberculosis in some autopsy series of patients with leprosy may be partly responsible for the controversy over lesions in the lungs of leprosy patients<sup>(5)</sup>. Neither gross nodules nor microscopic granulomas were found in the lung of the chimpanzee. We did not attempt to culture acid-fast bacilli from the lung but believe that the lung lesions are due to *M. leprae*. The animal had no response to intradermal tuberculin (PPD and old Mammalian) on several occasions.

In some organs at necropsy (pharynx, nerves, skin) AFB stained rather poorly (granularly) with FF but were seen to be very numerous when stained with GMS. This staining quality has also been noted in human patients treated for lepromatous leprosy<sup>(9)</sup>. This indication of bacterial degeneration, along with the findings of progressively more lymphocytes in lesions and eventual atrophy of skin nodules, indicates that this was probably not polar lepromatous leprosy (LL) but more like the borderline lepromatous (BL) or subpolar lep-

romatous classification used in man. Had treatment been instigated and had the animal not been subjected to repeated stresses of anesthesia, he might have survived for some time.

The armadillo is the only nonhuman species previously reported to be indigenously infected with *M. leprae*<sup>(16, 17)</sup>. The lesions of leprosy in the nine-banded armadillo are similar to those in this chimpanzee<sup>(2, 16)</sup>. In our view, armadillos most likely became infected in nature by *M. leprae* originating from advanced human lepromatous patients who had never received effective chemotherapy, i.e., in the pre-sulfone era. We speculate that this chimpanzee became infected in Sierra Leone by contact with a contagious leprosy patient, possibly in the process of being captured or reared by an animal dealer.

These postmortem findings, the positive dopa oxidase results on organisms collected at necropsy, and previously reported clinical, histopathological, and microbiological findings<sup>(4, 10)</sup> are evidence that this is naturally-acquired leprosy in a nonhuman primate and that the causative agent is indistinguishable from *M. leprae*.

Experimental transmission of leprosy to nonhuman primates, using AFB from humans, has been done<sup>(1, 6)</sup>. The results of these studies were considered negative; the animals developed transient skin nodules resembling those of tuberculoid leprosy of man. A recent report by Waters, *et al.*<sup>(18)</sup>, however, describes disseminated lepromatous leprosy in a white-handed gibbon. The disease was detected only by histopathologic examination of tissues collected at necropsy 15 years after inoculation of AFB of human origin. It is not known if lesions may have been present for many years before necropsy and if the animal might have been exposed to contagious leprosy patients.

The findings of Waters, *et al.*, along with our discovery of naturally-acquired leprosy in a chimpanzee, suggests that attempts to develop a nonhuman primate model for leprosy may be productive. Besides the armadillo, the Korean chipmunk<sup>(11)</sup> and the hedgehog<sup>(8)</sup> are receiving attention as potentially useful models. These animals, however, may have quite different defense mechanisms from man; the study of leprosy

in an animal phylogenetically closer to man may provide more valid information on the pathogenesis of leprosy in man and thereby lead to improved methods of treatment and prevention.

Experimental transmission of the AFB from this chimpanzee to other nonhuman primates is necessary to compare the infectivity of this organism to *M. leprae* from human sources. The discovery of leprosy in this chimpanzee may represent the fortuitous finding of infection of an animal with an organism that is usually only infectious for man but which under appropriate conditions, e.g., genetic susceptibility, stress, intercurrent viral infections (bovine leukemia virus?), can infect other primate species. It is possible, however, that this strain of *M. leprae* may be "chimpanzee adapted," and animals may be naturally infected by such an "adapted" mycobacterium in the geographical area of origin of this animal. Whether or not leprosy is a zoonotic disease under any epidemiologic and/or pathogenetic circumstances has not been determined, however.

#### SUMMARY

A young (5-7 year old) male chimpanzee died 33 months after the first clinical manifestations of a naturally acquired disease that was similar to disseminated leprosy in man. At autopsy there were diffuse or multifocal histiocytic infiltrations of the skin, nasal mucosa, pharynx, lung interstitium, liver, spleen, sclera, testicles, adrenal glands, and peripheral lymph nodes. Major nerves of the forearms had extensive fibrosis. There were large numbers of acid-fast bacilli (AFB), many occurring as globi, in histiocytes in most affected tissues including nerves. The histopathologic features of the disease and the microbiologic and antigenic properties of the AFB in the tissues indicate that *Mycobacterium leprae* or an organism indistinguishable from it was the causative agent. This and other cases of leprosy in nonhuman primates indicate that studies of the development of nonhuman primate models for leprosy may be worthwhile.

#### RESUMEN

Un chimpancé macho de 5-7 años de edad murió 33 meses después de las primeras manifestaciones clí-

cas de una enfermedad, adquirida en forma natural, similar a la lepra diseminada del hombre. La autopsia reveló la presencia de infiltrados difusos o multifocales de histiocitos en la piel, mucosa nasal, faringe, intersticio pulmonar, hígado, bazo, esclera, testículos, glándulas adrenales y ganglios linfáticos periféricos. En los antebrazos, los troncos nerviosos mayores tuvieron fibrosis extensa. En la mayoría de los tejidos afectados, incluyendo nervios, se encontraron grandes cantidades de bacilos ácido-resistentes, aislados y en globi, dentro de los histiocitos. Las características histopatológicas de las lesiones y las propiedades microbiológicas y antigénicas de los bacilos ácido-resistentes en los tejidos indicaron que el agente causal de la enfermedad fue el *Mycobacterium leprae* o un microorganismo indistinguible de él. Este y otros casos de lepra en primates no humanos indican que los estudios sobre el desarrollo de modelos para la lepra en tales primates son absolutamente justificables.

#### RÉSUMÉ

Un jeune chimpanzé male (âgé de 5 à 7 ans), est mort 33 mois après avoir présenté les premières manifestations cliniques d'une maladie acquise naturellement qui était similaire à la lèpre disséminée chez l'homme. A l'autopsie, on a observé des infiltrations d'histiocytes, diffuses ou en foyers multiples, dans la peau, le mucus nasal, le pharynx, les espaces interstitiels du poumon, le foie, la rate, la sclérotique, les testicules, les glandes surrénales, et les nodules lymphatiques périphériques. Les principaux nerfs des avant-bras présentaient une fibrose étendue. Dans la plupart des tissus atteints, y compris les nerfs, on a relevé des bacilles acido-résistants en grande quantité dans les histiocytes, beaucoup d'entre eux étant agglomérés en globi. Les caractéristiques histopathologiques de la maladie, de même que les propriétés microbiologiques et antigéniques des bacilles acido-résistants présents dans les tissus, indiquent que l'agent étiologique était soit *Mycobacterium leprae*, soit un microorganisme que l'on ne peut distinguer de celui-ci. Cette observation, de même que d'autres cas de lèpre chez des primates non-humains, montre qu'il vaut la peine de mener des études en vue de mettre au point des modèles de primates non-humains pour effectuer des recherches sur la lèpre.

**Acknowledgements.** We thank Dr. C. H. Binford, AFIP, Washington, D.C., Dr. C. C. Shepard, CDC, Atlanta, Georgia, U.S.A., and Michael Rubino, University of Iowa, for extensive general assistance; Dr. L. E. Zimmerman, AFIP, for preparing and examining the eye sections; and Dr. W. F. Kirchheimer, Carville, Louisiana for performing the dopa oxidase test and for consultation. This study was supported in part by grants from the Heiser Fellowship Program for Leprosy Research and from the Immunology of Leprosy (IMMLEP) component of the UNDP/World Bank/WHO Special Programme for Research and Training in Tropical Diseases.

## REFERENCES

1. BINFORD, C. H. The inoculation of human leprosy in the chimpanzee. Initiation of a long-term project. *Int. J. Lepr.* **33** (1965) 666-668.
2. BINFORD, C. H., MEYERS, W. M., WALSH, G. P., STORRS, E. E. and BROWN, H. L. Naturally acquired leprosy-like disease in the nine-banded armadillo (*Dasypus novemcinctus*): Histopathologic and microbiologic studies of tissues. *J. Reticuloendothel. Soc.* **22** (1977) 377-388.
3. BLACK, S. H. The pathology of leprosy. In: *Tuberculosis and Leprosy: The Mycobacterial Diseases*. Vol. 1. Moulton, F. R., ed. Am. Assoc. for the Adv. Sci. Symposium Series. Lancaster, Pa.: The Science Press Printing Co., 1942, 97-105.
4. DONHAM, K. J. and LEININGER, J. R. Spontaneous leprosy-like disease in a chimpanzee. *J. Infect. Dis.* **136** (1977) 132-136.
5. FITE, G. L. Leprosy from the histologic point of view. *Arch. Pathol.* **35** (1943) 611-644.
6. GUNDERS, A. E. Progressive experimental infection with *Mycobacterium leprae* in a chimpanzee: A preliminary report. *J. Trop. Med. Hyg.* **61** (1958) 228-230.
7. KEAN, B. H. and CHILDRESS, M. E. A summary of 103 autopsies on leprosy patients on the Isthmus of Panama. *Int. J. Lepr.* **10** (1942) 51-59.
8. KLINGMÜLLER, G. Inoculation of hedgehogs (*Eriinaceus europaeus*) with *Mycobacterium leprae*. *Abstr., XI Int. Lepr. Cong. Int. J. Lepr.* **47** (1979) 344.
9. KRIEG, R. E. and MEYERS, W. M. Demonstration of *Mycobacterium leprae* in tissues from bacteriologically negative treated lepromatous leprosy patients. *Int. J. Lepr.* **47** (1979) 408.
10. LEININGER, J. R., DONHAM, K. J. and RUBINO, M. J. Leprosy in a chimpanzee: Morphology of the skin lesions and characterization of the organism. *Vet. Pathol.* **15** (1978) 339-346.
11. LEW, J., YANG, Y. T. and PYUN, W. S. Experimental infection of the Korean chipmunk (*Tamias sibiricus asiaticus*, Gmelin) with *M. leprae*. *Int. J. Lepr.* **42** (1974) 193-202.
12. MITSUDA, K. The significance of the vacuole in the Virchow lepra cells and the distribution of lepra cells in certain organs. *Int. J. Lepr.* **4** (1936) 491-511.
13. MITSUDA, K. and OGAWA, M. A study of one hundred-fifty autopsies on cases of leprosy. *Int. J. Lepr.* **5** (1937) 53-60.
14. POWELL, C. S. and SWAN, L. L. Leprosy: Pathologic changes observed in fifty consecutive necropsies. *Am. J. Pathol.* **31** (1955) 1131-1147.
15. PRABHAKARAN, K. J. and KIRCHHEIMER, W. F. Use of 3,4 dihydroxyphenylalanine oxidation in the identification of *Mycobacterium leprae*. *J. Bacteriol.* **92** (1966) 1267-1268.
16. WALSH, G. P., STORRS, E. E., BURCHFIELD, H. P., COTTRELL, E. H., VIDRINE, M. F. and BINFORD, C. H. Leprosy-like disease occurring naturally in armadillos. *J. Reticuloendothel. Soc.* **18** (1975) 347-351.
17. WALSH, G. P., STORRS, E. E., MEYERS, W. M. and BINFORD, C. H. Naturally acquired leprosy-like disease in the nine-banded armadillo (*Dasypus novemcinctus*): Recent epizootiologic findings. *J. Reticuloendothel. Soc.* **22** (1977) 363-376.
18. WATERS, M. F. R., BAKRI, H. I., REES, R. J. W. and MCDUGALL, A. C. Experimental lepromatous leprosy in the white-handed gibbon (*Hylobatus lar*): Successful inoculation with leprosy bacilli of human origin. *Br. J. Exp. Pathol.* **59** (1978) 551-557.