

Degeneration and Regeneration of Unmyelinated Fibers in Experimental Leprous Neuropathy¹

V. P. Shetty and N. H. Antia²

Since Gasser (⁸) documented the precise relationship of unmyelinated axons and Schwann cells, electron microscopy has been used to define both the qualitative and quantitative aspect of these fibers in normal and diseased peripheral nerves in humans as well as in experimental animals. Autonomic nerves of the rat cervical sympathetic trunk have been studied by Dyck and Hopkins (⁷) and Aguayo, *et al.* (¹) and the rabbit abdominal vagus by King and Thomas (¹¹). Behse, *et al.* (⁴) have examined the relationship of unmyelinated fibers and their Schwann cells in the sural nerve of man in various peripheral neuropathies.

Early changes both in traumatic and other neuropathies consist of swelling of the axons, more so in the transected or crushed unmyelinated nerves, with degeneration of the neurotubules, neurofilaments, and mitochondria (⁷). In crush injury, regeneration follows soon after the degeneration of unmyelinated fibers. This has been demonstrated by functional as well as morphologic studies by Hopkins and Lambert (⁹), Bray, *et al.* (⁵), and Aguayo, *et al.* (¹). In these studies, four phases of unmyelinated fiber regeneration have been recognized. These are axonal sprouting, longitudinal growth, loss of redundant sprout and axonal maturation. The axonal sprouts are similar in size and in their clustered appearance to those observed in the early stages of fetal nerve development (¹³). However, the morphologic characteristics of the degenerative process of unmyelinated fibers and the exact fate of the swollen unmyelinated fiber are not clearly defined (^{7,22}). It is presumed that they are rapidly reabsorbed by the Schwann cells (¹⁰).

The present report is based on our observations during the study of peripheral nerve changes seen in the sciatic nerves of Swiss mice inoculated into the foot pad with *M. leprae*. Details of the experiments have been published elsewhere (²⁰). In the earlier reports, attention has been drawn to the fact that the earliest changes in human as well as mouse leprosy neuropathy are observed in the unmyelinated fibers and their Schwann cells (^{3, 12, 17, 18, 19}). In this paper we wish to describe some of the morphologic changes observed in the unmyelinated fibers, which throw some light on the sequence of changes that follow the early derangement of these fibers in experimental leprosy neuropathy.

MATERIALS AND METHODS

Fifty non-immunosuppressed Swiss white female mice, 2–4 weeks of age, were inoculated in both hind foot pads with 5×10^8 *M. leprae*. Ten uninoculated mice and ten mice inoculated into both hind foot pads with 0.03 ml of normal saline were also maintained as controls. The sciatic nerves were biopsied at two monthly intervals from the 4th to the 24th post-inoculation month. A foot pad harvest was done each time to keep a check on the growth curve of *M. leprae*.

All the nerve specimens were fixed *in vivo* with 2.5% glutaraldehyde and further fixed *in vitro* in cacodylate buffered 2.5% glutaraldehyde followed by buffered 1% OsO₄ for 2 hr. The specimens were then dehydrated and embedded in an epoxy resin mixture. Ultra thin sections were studied using a Phillips 300 electron microscope.

RESULTS

The observations in this communication are mainly restricted to the 4th to the 8th post-inoculation month. This is because our previous study (¹⁹) had revealed non-myelinated fiber changes as early as the 4th post-inoculation month while myelinated

¹ Received for publication on 26 June 1980; accepted for publication in revised form on 18 May 1981.

² V. P. Shetty, Ph.D., Research Officer; N. H. Antia, F.R.C.S., Trustee and Research Director, The Foundation for Medical Research, 84-A, R.G. Thadani Marg, Sea Face Corner, Worli, Bombay-400 018, India.

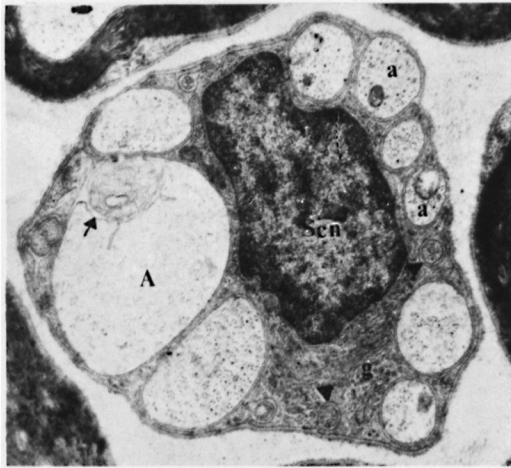


FIG. 1. The swollen axon 'A' has a watery appearance with disintegration of axonal elements. It also shows retraction of the inner axolemma (arrow) around membrane debris. The other axons 'a' in the same Schwann cell subunit are comparatively better preserved, but have incomplete Schwann cell ensheathment. Some well preserved miniature axons (arrow head) are also seen. Sc. n.—Schwann nucleus, g—Golgi. Thin section of sciatic nerve from a foot pad inoculated mouse at the 4th post-inoculation month. Uranyl acetate and lead citrate stain ($\times 14,000$).

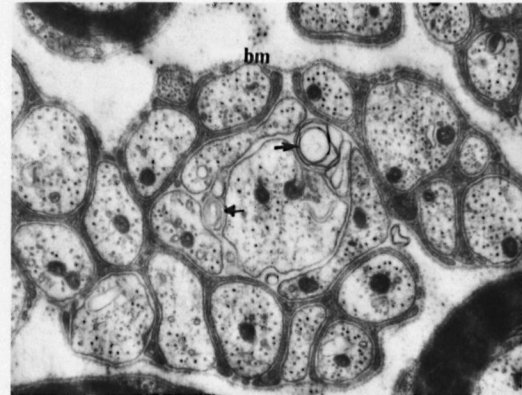


FIG. 2. Loose arrangement of the axons of an unmyelinated fiber unit. A few centrally placed axons have lost their Schwann cell support and their integrity. Some laminated inclusions (arrow) are also seen. The other axons in the same Schwann cell subunit have better preserved neurotubules and mitochondria, but most of the axons at the periphery have an incomplete Schwannian ensheathment. bm—basement membrane. Thin section of sciatic nerve from a mouse inoculated into the foot pad with *M. leprae* at the 4th post-inoculation month. ($\times 39,150$).

fiber changes were observed only after the 8th post-inoculation month.

Although similar changes were observed in the sciatic nerves of the majority of the animals under study, most of the micrographs presented in this paper were selected from nerves of one mouse in order to give a complete picture of the varying structural changes as revealed simultaneously in a single nerve.

Fig. 1 shows axonal swelling in the unmyelinated fiber unit. The swollen axons exhibit a watery axoplasm with disintegration of axonal elements like neurotubules, neurofilaments, and mitochondria. There is a retraction of Schwann cytoplasmic processes, and at places the axons are held only by basement membrane. In Fig. 2, a few centrally placed axons have lost their Schwann cell support as well as integrity. Most of the axons at the periphery also show incomplete Schwannian ensheathment. Often a breakdown of the parent Schwann unit leads to loose scattering of axons which otherwise have a normal appearance of their axis cylinders. A group of axons in Fig. 3 are held by a collar of

Schwann cytoplasm with its associated basement membrane but with complete lack of individual ensheathment by the Schwann processes. Some of the axons devoid of their manual support by Schwann processes show varying degrees of atrophic changes. On the other hand, some of the other unmyelinated fiber groups show Bungner band like appearance⁽⁶⁾, as demonstrated in Fig. 4. The collapsed axons reveal condensation of neurotubules and filaments and the Schwann cell processes supporting these axons show a very unhealthy appearance. A number of axons also show atrophic changes.

In Fig. 5 one centrally placed axon is surrounded by folds of basement membrane which contain finger-like unhealthy Schwann cell cytoplasmic processes giving an onion peel like appearance. Fig. 6 also demonstrates features similar to the above but the axon in the center is in the early stage of myelination. A fairly well preserved axon (A) in Fig. 7 shows three distinct rings of extended mes-axon while the remaining axons in the same Schwann cell subunit show varying degrees of degenerative changes. In a fairly well preserved unmyelinated fiber group in Fig. 8, one of

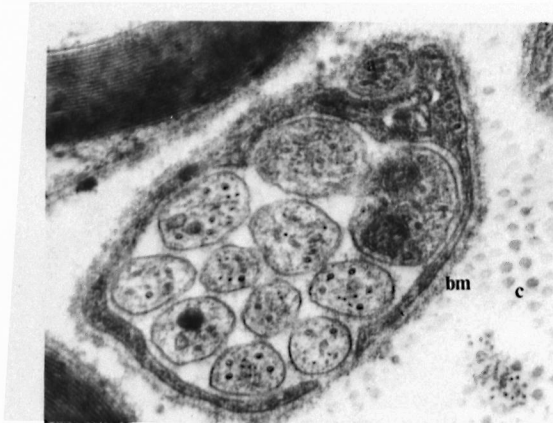


FIG. 3. A number of fairly well preserved small axons are held by a collar of Schwann cytoplasmic process. There is no individual ensheathment of the axons by the Schwann process. One axon (a) outside the Schwann collar shows atrophic change. c—collagen, bm—basement membrane. Thin section of sciatic nerve from foot pad inoculated mouse at the 6th post-inoculation month ($\times 170,000$).

the large axons (A) which is attached to the main unit by an electron dense Schwann process is observed to be undergoing successful myelination. Another small but well preserved axon (a) in the same Schwann cell subunit reveals elongation of the mesaxon with $1\frac{1}{2}$ turns. In Fig. 9, an isolated

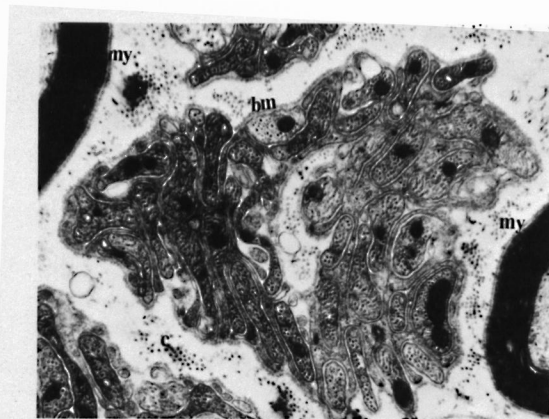


FIG. 4. Unmyelinated fiber group showing flattened processes, looking like bands of Bungner. The flattened processes, which are mostly axons, are seen partly encircled by unhealthy looking Schwann processes with its basement membrane (bm). Parts of two well preserved myelinated fibers (my) are seen at the periphery. c—collagen. Thin section of sciatic nerve from a foot pad inoculated mouse at the 4th post-inoculation month ($\times 39,150$).

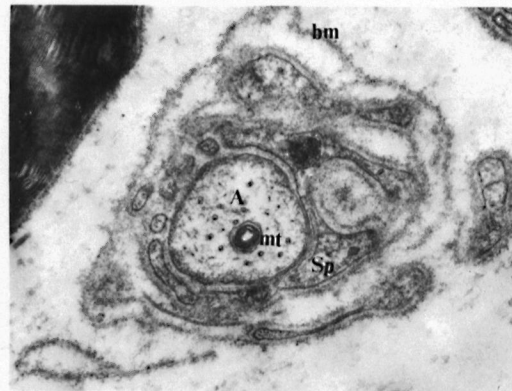


FIG. 5. A fairly well preserved axon (A) is surrounded by folds of basement membrane processes (bm) and remnants of Schwann cytoplasmic processes (Sp) giving an onion peel like appearance. mt—mitochondria. Thin section of sciatic nerve from foot pad inoculated mouse at the 6th post-inoculation month ($\times 85,260$).

axon is in the early stage of myelination with the myelinating Schwann cell showing a highly folded basement membrane with enclosed flattened Schwann processes. Occasionally a freshly forming myelin ring system enclosing multiple axonal units was also observed (Fig. 10), details of which have been published previously elsewhere⁽²⁰⁾. The inner axolemma of the myelinating Schwann cell is in continuity and is seen to form contact with most of the axons.

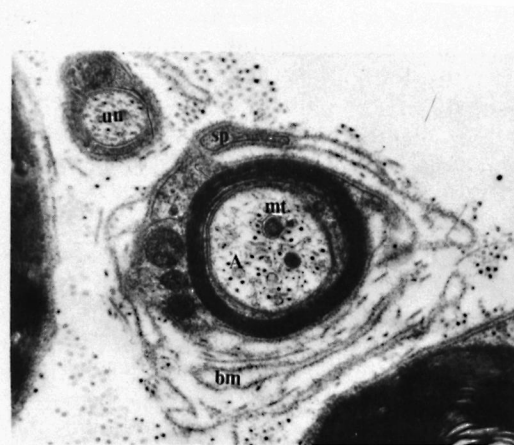


FIG. 6. Another area in the same nerve as Fig. 5 showing an axon (A) in the early stage of myelination surrounded by multiple folds of basement membrane (bm) also giving an onion peel like appearance. Sp.—Schwann process, mt—mitochondria, Un—Unmyelinated axon ($\times 46,000$).

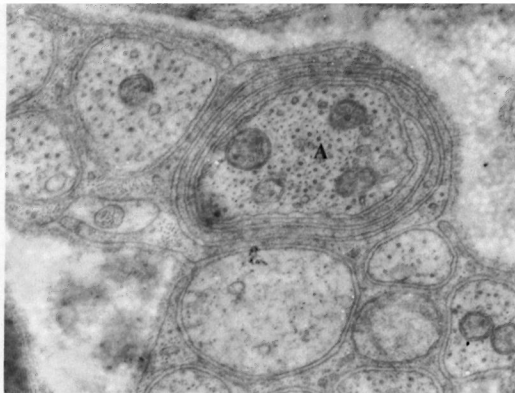


FIG. 7. One of the fairly well preserved axons (A) in an unmyelinated fiber unit has elongation of the mesaxon into three rings and is probably in the early stage of myelination. The other axons in the same Schwann cell subunit show varying degrees of degenerative changes. Thin section of sciatic nerve from a foot pad inoculated mouse at the 8th post-inoculation month. ($\times 40,000$).

A simultaneous regenerative effort was observed in most of the unmyelinated fiber groups. Subsequently, as a result of repeated denervation, irreversible damage seems to occur to most of the axons of the unmyelinated fiber groups, though efforts at reinnervation were noticed throughout.

DISCUSSION

It is fortunate that in the mouse model of leprosy there is a period between the 4th and 8th post-inoculation month when the degenerative and regenerative changes in the unmyelinated fibers of the sciatic nerve can be observed in relative isolation undisturbed by any activity of the myelinated fibers. The observations in this study are based on this differential involvement of the unmyelinated fibers as opposed to myelinated fibers and their Schwann cells. This study demonstrates some of the earliest degenerative as well as regenerative changes in the unmyelinated fibers of the peripheral nerve.

Figs. 1 and 4 demonstrate swelling of the axons and axonal collapse respectively observed in the early stages of unmyelinated fiber damage. Fig. 1 reveals disintegration of axonal elements. The swelling of the axons often results in the retraction of the encircling Schwann process, i.e., de-en-

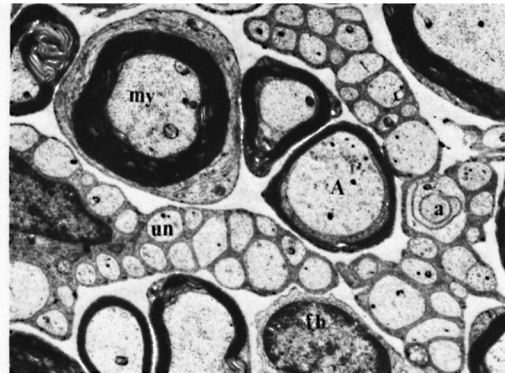


FIG. 8. Reveals two unmyelinated fiber units (un) and number of myelinated fibers (my). One of the axons (A) which is in the early stage of myelination is seen attached to one of the unmyelinated fiber units by a foot plate like Schwann process. This myelinating axon (A) has a highly enlarged size as compared to the rest of the unmyelinated axons. Another small axon (a) in the same unmyelinated fiber unit has a highly elongated mesaxon with $1\frac{1}{2}$ turns around the axon. Note the definite continuity of the BM from the unmyelinated into the myelinated fiber. fb—fibroblast. Thin section of sciatic nerve from a foot pad inoculated mouse at the 4th post-inoculation month ($\times 10,000$).

sheathment of the axons as seen in Fig. 1. It is possible that as a consequence of Schwannian de-ensheathment there is axonal swelling as well as axonal collapse. The question would therefore arise as to where the primary lesion lies, in the Schwann cell or in the axon. Leprosy as a disease is known to affect primarily the Schwann cells, especially of the unmyelinated fibers. Based on this assumption, at least part of the axonal atrophy and swelling that occurs in leprosy may result from the involvement of the unmyelinated fiber Schwann cells.

The axons which have lost their integrity with the Schwann cells reveal various axoplasmic abnormalities. Collapse of the axon at any one level may well lead to blockage of the axoplasmic flow in the distal part of the axon, which if not supported by a myelin sheath would result in its gross dilatation and degenerative changes in its intraaxonal structures. When a disorganized unmyelinated axon balloons, it achieves a vastly increased diameter as compared to normal unmyelinated axons.

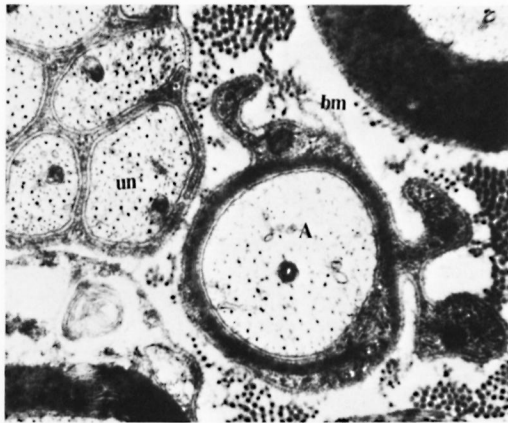


FIG. 9. A newly myelinating axon 'A' shows highly folded basement membrane 'bm' with inclusions of Schwann cytoplasmic process. The axon 'A' has a very sparse neurotubules. Part of unmyelinated unit (un) seen nearby looks normal. Thin section of a sciatic nerve from foot pad inoculated mouse at the 8th post-inoculation month. ($\times 40,000$).

Onion bulb formations have been described exclusively in the myelinated fibers undergoing repeated demyelination^(21,25). This study reveals onion bulb like structures in relation to unmyelinated fibers. Ochoa⁽¹⁶⁾ provides strong evidence that unmyelinated fibers do participate in onion bulb formations, especially when they are partially denervated. We feel that the onion bulb-like structures demonstrated by us in relation to unmyelinated axons (Fig. 5) are also the result of partial denervation of the parent unit. We further postulate that in these partially denervated units some of the axons might undergo myelination.

While some authors like Ochoa and Mair⁽¹⁴⁾, Morris, *et al.*⁽¹³⁾, may describe Figs. 5 and 6 as demyelinating and remyelinating activity following degeneration of a myelinated fiber, we herewith provide clear evidence that this may well represent myelination of a parent unmyelinated axon. In Fig. 7, which is undoubtedly an unmyelinated fiber group, there is a well-preserved axon (A) which shows three distinct rings of mesaxon, whereas the other axons in the same Schwann cells subunit show various stages of degeneration. In Fig. 8 there is successful myelination of one of the enlarged axons (A), which is attached to the parent unmyelinated fiber unit by a finger-like

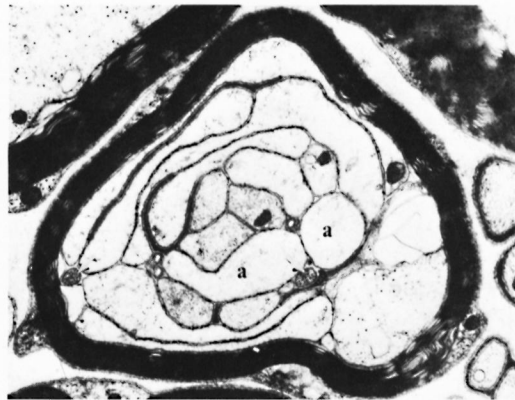


FIG. 10. Multiple axons, a number of them cut tangentially, are surrounded by a reasonably good thickness of myelin with its enclosing Schwann cytoplasm and basement membrane. The electron dense processes seen between the tangentially cut axons are Schwann processes which could be mistaken for myelin. Most of the axons 'a' show a watery appearance of the axoplasm. Two miniature axons are also present. Thin section of sciatic nerve from a foot pad inoculated mouse at the 6th post-inoculation month. ($\times 20,000$).

Schwann process which is definitely an extension of the parent unmyelinated fiber unit as demonstrated by the continuity of the basement membrane. While Figs. 6 and 9 could be interpreted as remyelination following the demyelination of a myelinated fiber, we are inclined to interpret them in our study as myelination of a parent unmyelinated axon which has undergone a partial denervation because of the following reasons.

The nerves in this study revealed an almost uniformly well preserved and unaffected myelinated fiber population, while demonstrating an intense involvement of unmyelinated fiber groups and their Schwann cells. Figs. 6 and 9 probably represent the sequence following that indicated in Figs. 5 and 7 where the other unmyelinated axons and surrounding Schwann processes have disintegrated, leaving loose folds of basement membrane. The central enlarged axon of the unmyelinated group has now been successfully myelinated. In Fig. 9 the freshly myelinating Schwann cell has a highly folded basement membrane with remnants of Schwann cytoplasmic processes, which may have harbored other

unmyelinated axons. Fig. 10 reveals distinct myelination of a large, compact, rounded cluster of a tangentially cut unit of unmyelinated fibers.

The presence of myelinated and unmyelinated axons collected together into clusters is considered to indicate regenerative activity following degeneration of a single myelinated fiber⁽¹³⁾ or is the result of a collateral branching from an original fiber⁽¹⁴⁾. The study of King and Thomas⁽¹¹⁾ revealed that the regenerating unmyelinated axons of the vagus nerve were guided by the myelinated axons giving a "clustered" appearance in the recurrent laryngeal nerve. The sequence of events described by us indicates that the derangement of unmyelinated axons and associated Schwann cells may also lead to myelination of some of the parent unmyelinated axons, giving a "cluster" like appearance as described by the previously mentioned authors.

It is also postulated that the enlarged size of a disorganized unmyelinated axon as also that of a rounded cluster of reorganizing unmyelinated axons could possibly serve as a necessary signal for the Schwann cell to initiate the myelination. This is supported by the belief that the peripheral nerves contain a uniform population of Schwann cells^(2, 23, 24).

Leprosy is a disease of the peripheral nerve. The primary involvement is related to the Schwann cells associated with unmyelinated axons and thus provides a model for the study of unmyelinated fibers and their Schwann cells. The early changes in the sciatic nerves of mice infected with *M. leprae* have provided us with an opportunity to observe some usual as well as unusual changes in unmyelinated nerve fibers, some of which have not been reported previously in this or any other experimental model.

SUMMARY

Electron micrographs have been presented illustrating several changes in the unmyelinated fibers in the sciatic nerves of mice with experimental leprosy neuropathy. An attempt has been made to postulate the sequence of changes. Based on these observations the possibility of myelination of parent unmyelinated fibers, following de-

range of their Schwann cells and axons, has been discussed.

RESUMEN

Se presentan fotografías al microscopio electrónico que ilustran diversos cambios en las fibras no mielinizadas en los nervios ciáticos de ratones con neuropatía leprosa experimental. Al mismo tiempo se hace el intento de postular la secuencia de cambios observados. Basados en estos hallazgos, se discute la posibilidad de mielinización de las fibras progenitoras no mielinizadas, después del desarreglo de sus células de Schwann y axones.

RÉSUMÉ

On présente ici des micrographies électroniques qui illustrent plusieurs modifications au niveau des fibres non myélinisées des nerfs sciatiques chez la souris atteinte de neuropathie lépreuse expérimentale. On a tenté de définir la séquence des modifications. Sur la base de ces observations, on a discuté la possibilité d'une myélinisation des fibres originales non myélinisées, à la suite des désordres survenus au niveau des cellules de Schwann et des axones.

Acknowledgments. The authors thank Dr. Mrs. Lata Mehta for her helpful discussion and the Cancer Research Institute for their generous use of the electron microscope.

REFERENCES

1. AGUAYO, A. J., PEYRONNARD, J. M. and BRAY, G. M. A quantitative ultrastructural study of regeneration from isolated proximal stumps of transected unmyelinated nerves. *J. Neuropathol. Exp. Neurol.* **32** (1973) 256-270.
2. AGUAYO, A. J., CHARRON, L. and BRAY, G. M. Potential of Schwann cells from unmyelinated nerves to produce myelin: A quantitative ultrastructural and radioautographic study. *J. Neurocytol.* **5** (1976) 565-573.
3. ANTIA, N. H., MEHTA, L. N., SHETTY, V. P. and IRANI, P. F. Clinical, electrophysiological, quantitative, histologic and ultrastructural studies of the index branch of the radial cutaneous nerve in leprosy. 1. Preliminary report. *Int. J. Lepr.* **43** (1975) 106-113.
4. BEHSE, F., BUCHTHAL, F., CARLSEN, F. and KANAPEIS, G. G. Unmyelinated fibres and Schwann cells of sural nerve in neuropathy. *Brain* **98** (1975) 493-510.
5. BRAY, G. M., PEYRONNARD, J. M. and AGUAYO, A. J. Reactions of unmyelinated nerve fibres to injury—An ultrastructural study. *Brain Res.* **42** (1972) 297-309.
6. BUNGNER, O. Über die Degenerations und Regenerationsvorgänge am Nerven nach Verletzungen. *Zieglers Beiträge* **10** (1891) 321.

7. DYCK, P. J. and HOPKINS, A. P. Electronmicroscopic observations on degeneration and regeneration of unmyelinated fibres. *Brain* **95** (1972) 223–234.
8. GASSER, H. S. The hypothesis of saltatory conduction. *Cold Spring Harbor Symp. Quant. Biol.* **17** (1952) 32–36.
9. HOPKINS, A. P. and LAMBERT, E. H. Conduction in regenerating unmyelinated fibres. *Brain* **95** (1972) 213–222.
10. IWAYAMA, T. Ultrastructural changes in the nerves innervating the cerebral artery after sympathectomy. *Z. Zellforsch. Mikrosk. Anat.* **109** (1970) 465–480.
11. KING, R. M. H. and THOMAS, P. K. Electronmicroscopic observations on aberrant regeneration of unmyelinated axons in the vagus nerve of rabbit. *Acta Neuropath.* **18** (1971) 150–159.
12. MEHTA, L. N., SHETTY, V. P., ANTIA, N. H. and IRANI, P. F. Quantitative histological and ultrastructural studies of the index branch of the radial cutaneous nerve in leprosy and its correlation with electrophysiological study. *Int. J. Lepr.* **43** (1975) 256–264.
13. MORRIS, J. H., HUDSON, A. R. and WEDDELL, G. A study of degeneration and regeneration in the divided rat sciatic nerve based on electronmicroscopy. *Z. Zellforsch.* **124** (1972) 76–203.
14. OCHOA, J. and MAIR, W. G. P. The normal sural nerve in man II. Changes in the axons and Schwann cells due to aging. *Acta Neuropath. (Berl.)* **13** (1969) 217–239.
15. OCHOA, J. The sural nerve of the human foetus: Electronmicroscopic observations and counts of axons. *J. Anat.* **108** (1971) 231–245.
16. OCHOA, J. Recognition of unmyelinated fibre disease: Morphologic criteria. *Muscle and Nerve* **1** (1978) 373–387.
17. SHETTY, V. P., MEHTA, L. N., IRANI, P. F. and ANTIA, N. H. Study of evolution of nerve damage in leprosy. I. Lesions of the index branch of the radial cutaneous nerve in early leprosy. *Lepr. India* **52** (1980) 5–18.
18. SHETTY, V. P., MEHTA, L. N., IRANI, P. F. and ANTIA, N. H. Study of evolution of nerve damage in leprosy. II. Observations on the index branch of the radial cutaneous nerve in contacts of leprosy. *Lepr. India* **52** (1980) 19–25.
19. SHETTY, V. P., VIDYASAGAR, P. B. and ANTIA, N. H. Study of evolution of nerve damage in leprosy. III. Sciatic nerve lesion in mice inoculated with *M. leprae*, with nerve conduction velocity correlation. *Lepr. India* **52** (1980) 26–47.
20. SHETTY, V. P. and ANTIA, N. H. Myelination around multiple axons in the peripheral nerve—An ultrastructural observation. *Acta Neuropathol. (Berl.)* **50** (1980) 147–151.
21. THOMAS, P. K. and LASCELLES, R. G. Hypertrophic neuropathy. *Q. J. Med.* **36** (1967) 223–238.
22. THOMAS, P. K., KING, R. M. H. and PHELPS, A. C. Electronmicroscope observations of unmyelinated axons following nerve section. *J. Anat.* **113** (1972) 279–280.
23. WEINBERG, H. and SPENCER, P. S. Studies on the control of myelinogenesis. I. Myelination of regenerating axons after entry into a foreign unmyelinated nerve. *J. Neurocytol.* **4** (1975) 395–418.
24. WEINBERG, H. and SPENCER, P. S. Studies on the control of myelinogenesis. II. Evidence for neuronal regulation of myelination. *Brain Res.* **113** (1976) 363–378.
25. WELLER, R. O. An electronmicroscopic study of hypertrophic neuropathy of Dejerine and Sottas. *J. Neurol. Neurosurg. Psychiatry* **30** (1967) 111–125.