

## Structure and Function of the Small Bowel in Lepromatous Leprosy<sup>1</sup>

Nirmal Kumar, Veena Malhotra, Rattan Singh,  
J. C. Vij, and B. S. Anand<sup>2</sup>

In leprosy the most commonly involved areas are the skin and peripheral nerves. Less frequently, some of the internal organs such as the liver, spleen, and lymph nodes are also affected. However, involvement of the small bowel in leprosy is controversial. Reports, most of which are based on post-mortem studies, vary from essentially normal histological appearances (7) to significant mucosal atrophy (12). In order to examine this in more detail, a prospective study of the histological appearances and absorptive functions of the small bowel was carried out in ten patients with leprosy.

### MATERIALS AND METHODS

Ten untreated patients with lepromatous leprosy were included in the study. The following routine blood tests were carried out: complete hemogram, total and differential proteins, serum bilirubin, SGOT, SGPT, and alkaline phosphatase. Hepatitis B surface antigen was assessed by the counter-current immunoelectrophoresis technique. A barium contrast study of the small bowel was performed in all the cases. Stool examinations for ova and cysts were carried out on three consecutive days.

**Fat balance test.** Patients were put on a high (75 g) fat diet for six days and all stool samples over the last three days were collected. Fat content was estimated by the method of van de Kamer (15). The results were expressed as grams of fat per 24 hr stool sample.

**D-Xylose test.** A 5 g dose of D-xylose was administered orally. One hr later a blood sample was obtained and was analyzed for xylose by standard techniques (6).

Peroral jejunal biopsy specimens were obtained using the Watson capsule. The capsule was positioned under fluoroscopy just beyond the duodeno-jejunal junction. The biopsy specimens were orientated using a dissecting microscope and stained with hemotoxylin and eosin and Ziehl-Neelsen stains.

### RESULTS

There were eight males and two females with a mean ( $\pm$ S.D.) age of 35.8 ( $\pm$ 11.2) years, range, 20–52 years. The duration of illness varied from one to ten years with an average of 3.9 years. The BI (11) varied from 2+ to 6+. One patient had concomitant pulmonary tuberculosis. All patients were on an adequate diet and all were free from any symptoms related to the gastrointestinal tract.

The mean hemoglobin ( $\pm$ S.D.) concentration was 10 ( $\pm$ 2.8) g%. The mean ( $\pm$ S.D.) total serum proteins were 6.8 ( $\pm$ 0.32) g% with a mean albumin of 3.1 ( $\pm$ 0.31) and globulin of 3.65 ( $\pm$ 0.32) g%. Other liver function tests were within normal limits. The erythrocyte sedimentation rate was significantly raised in all patients with a mean of 74 ( $\pm$ 44) mm per hr. Stool examinations showed *Ankylostoma duodenale* in one patient. Hepatitis B surface antigen was negative in all patients. No abnormality of the small bowel was detected on barium contrast studies.

**Tests of absorption.** Table 1 summarizes the results of the absorption tests. All patients except one had normal fat absorption. The one exception had a mild steatorrhea with fat excretion of 7.1 g/24 hr. Similarly, D-xylose absorption was normal in all patients except two (case nos. 6 and 10) and both showed only a mild derange-

<sup>1</sup> Received for publication on 3 August 1981; accepted for publication on 14 December 1981.

<sup>2</sup> N. Kumar, M.D., Senior Resident, Department of Gastroenterology; V. Malhotra, M.D., Lecturer, Department of Pathology, G. B. Pant Hospital, New Delhi, India; Prof. R. Singh, D.V., M.D., Head of Department of Skin and V.D., Irwin Hospital, New Delhi, India; J. C. Vij, M.D., D.M., Lecturer; B. S. Anand, M.D., Ph.D., Assoc. Prof. and Head, Department of Gastroenterology, G. B. Pant Hospital, New Delhi, India.

ment. Barium contrast studies showed no abnormality in any of the patients.

**Jejunal mucosa.** The histological appearances of the jejunal mucosa are shown in Figures 1 and 2 and the detailed assessment summarized in Table 2. The villous pattern was normal in eight patients; while the remaining two (case nos. 6 and 9) showed mild broadening and stunting of the villi. Jejunal crypts were of normal length in all biopsy specimens, including those with villous stunting. No acid-fast bacilli or granulomas were seen in any of the biopsy specimens. The surface absorptive cells were tall and columnar with a uniform basal arrangement of the nuclei. A subjective assessment of the chronic inflammatory cellular infiltrate did not reveal any appreciable increase in cells either in the surface epithelium or in the lamina propria in all patients except one. The exception showed an increase in the number of chronic inflammatory cells in the lamina propria and was, incidentally, the one with the *Ankylostoma* infestation.

#### DISCUSSION

Skin and peripheral nerves are invariably involved in leprosy. In addition, internal viscera can be extensively involved in lepromatous leprosy particularly those that are rich in reticuloendothelial cells, such as the liver, spleen, bone marrow and lymph nodes<sup>(3, 4, 8, 9, 10)</sup>. Involvement of the gastrointestinal tract, on the other hand, is a subject of much controversy. Post-mortem studies give conflicting results; some studies show-

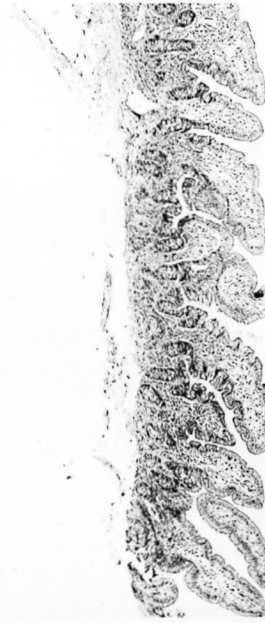


FIG. 1. Jejunal mucosa of a patient with lepromatous leprosy showing normal histological appearances (H & E  $\times 63$ ).

ing invasion by leprosy bacilli<sup>(1)</sup> and even severe villous atrophy<sup>(12)</sup>, others reporting perfectly normal histological appearances<sup>(7)</sup>. From a therapeutic viewpoint, it is of importance to assess the state of absorption in leprosy patients since treatment is dependent upon the ability of the small bowel to absorb orally administered drugs. The present study shows that intestinal absorp-

TABLE 1. Small bowel functions in patients with lepromatous leprosy.

Case No.	Age/sex	Ridley Bacteriologic Index (mean)	Fecal fat <sup>a</sup>			Mean	Blood D-xylose <sup>b</sup>	Barium meal follow-through
			Day 1	Day 2	Day 3			
1	35/F	2.3	1.2	1.6	3.3	2.03	33.0	Normal
2	25/M	2.7	5.9	3.1	3.1	4.03	22.2	Normal
3	20/M	3.5	4.0	3.1	4.7	3.93	22.2	Normal
4	52/M	3.0	2.4	2.2	3.0	2.53	25.0	Normal
5	35/M	3.5	4.2	5.6	5.1	4.96	25.0	Normal
6	30/M	6.0	4.2	4.4	4.2	4.26	16.6	Normal
7	50/M	3.0	7.6	7.2	6.6	7.13	22.2	Normal
8	25/M	3.0	4.0	3.2	2.8	3.33	22.2	Normal
9	38/F	3.5	4.1	3.7	2.8	3.53	22.2	Normal
10	48/M	2.8	2.3	1.7	2.8	2.26	20.0	Normal

<sup>a</sup> Grams per 24 hr; normal < 6 g/24 hr.

<sup>b</sup> Concentration 1 hr after 5 g oral dose; normal > 22 mg%.

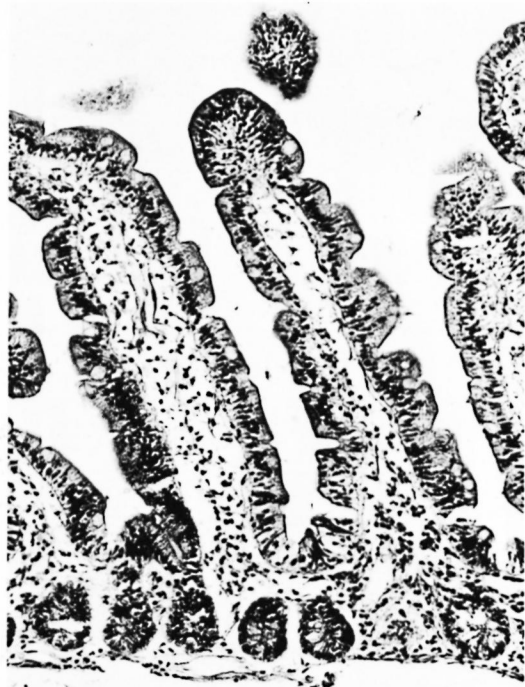


FIG. 2. Normal jejunal mucosal appearances in lepromatous leprosy as seen under high power (H & E  $\times 250$ ).

tion is well preserved in subjects with extensive lepromatous leprosy and is in agreement with the observations made by Kaur, *et al.* (7). Therefore, oral drug therapy should be perfectly adequate in treating subjects, even those with a severe disease.

Histological assessment of the small intestinal mucosa did not reveal any significant abnormality as judged by light microscopic examination of the specimens (Figs. 1 and 2). Furthermore, specific staining for acid-fast bacilli failed to reveal any organisms in the mucosa and submucosa. However, it is not possible to comment upon the invasion of the muscle coat, as noted by other workers (1), since peroral biopsy specimens are limited to the muscularis mucosa.

Theoretically, it is of interest to determine why the small bowel is spared in this disease despite a continuous bacillemia in untreated subjects (5, 13). It is known that the central nervous system, lung parenchyma, heart, great vessels, and female reproductive organs are not involved in leprosy (2, 3, 4). This is not difficult to understand

TABLE 2. Histopathology of jejunal mucosa in patients with lepromatous leprosy.

Case No.	Villous pattern	Crypts	Inflammatory infiltrate of lamina propria	Acid-fast bacilli
1	Normal	Normal	Increased lymphoid collection	Nil
2	Normal	Normal	Normal	Nil
3	Normal	Normal	Normal	Nil
4	Normal	Normal	Normal	Nil
5	Normal	Normal	Normal	Nil
6	Mild broadening	Normal	Normal	Nil
7	Normal	Normal	Normal	Nil
8	Normal	Normal	Normal	Nil
9	Mild broadening	Normal	Increased	Nil
10	Normal	Normal	Normal	Nil

in view of the fact that these organs are deficient in reticuloendothelial cells. The gastrointestinal tract, on the other hand, has an abundance of macrophages and, therefore, it is somewhat surprising that the small bowel is not affected. One explanation may lie in the optimal physical requirements of leprosy bacilli, since these organisms thrive only at low temperatures (14). It is possible that the small bowel has a relatively higher temperature in view of the marked metabolic activity taking place there, and this may protect this organ from infection.

#### SUMMARY

The structural and functional status of the small bowel was examined in ten patients with lepromatous leprosy. The absorptive functions were essentially normal in all patients except for minor abnormalities; one patient had mild steatorrhea and two others had derangement of D-xylose absorption. Barium examination did not reveal any abnormality in any patient. Histological study of the small intestinal mucosa showed mild, partial villous atrophy in two patients and normal appearances in the remaining eight.

The above abnormalities were mild and were not considered to be of any clinical significance. It is therefore concluded that the small bowel is not commonly involved in lepromatous leprosy.

#### RESUMEN

Se examinó el estado estructural y funcional del intestino delgado en 10 pacientes con lepra lepromatosa.

Las funciones de absorción fueron esencialmente normales en todos los pacientes, excepto por algunas alteraciones menores; un paciente tuvo esteatorrea moderada y otros dos tuvieron alteraciones en la absorción de D-xilosa. El examen con bario no reveló ninguna anomalía en ningún paciente. Los estudios histológicos de la mucosa del intestino delgado revelaron una atrofia vellosa parcial y moderada en 2 pacientes, y una apariencia normal en los ocho restantes.

### RÉSUMÉ

L'état structurel et fonctionnel de l'intestin grêle a été examiné chez 10 malades atteints de lèpre lépromateuse. Les fonctions d'absorption se sont révélées absolument normales chez tous les malades, sinon pour quelques anomalies mineures. Un patient présentait une stéatorrhée légère, et deux autres souffraient de troubles de l'absorption du D-xylose. Les examens au baryum n'ont pas révélé d'anomalies chez aucun malade. L'étude histologique de la muqueuse de l'intestin grêle a mis en évidence une atrophie peu prononcée et partielle des villosités chez deux malades, alors que les huit autres patients présentaient des images normales.

**Acknowledgment.** We should like to thank Dr. N. K. Ganguly for his critical suggestions.

### REFERENCES

1. BERNARD, J. C. and VAZQUEZ, C. A. J. Visceral lesions in lepromatous leprosy; study of sixty necropsies. *Int. J. Lepr.* **41** (1973) 94-101.
2. BRAND, P. W. Temperature variation and leprosy deformity. *Int. J. Lep.* **27** (1959) 1-7.
3. DESIKAN, K. V. and JOB, C. K. A review of post-mortem findings in 27 cases of leprosy. *Int. J. Lep.* **36** (1968) 32-44.
4. DESIKAN, K. V. and JOB, C. K. Visceral lesions caused by *M. leprae*, a histological study. *Indian J. Pathol. Bacteriol.* **13** (1970) 101-104.
5. DRUTZ, D. J., CHEM, T. S. N. and WEN-HSIANG LU. The continuous bacteremia of lepromatous leprosy. *N. Engl. J. Med.* **287** (1972) 159-164.
6. HAENEY, M. R., CULANK, L. S. and MONTGOMERY, R. D. Evaluation of xylose absorption as measured in blood and urine, a one hour blood xylose screening test in malabsorption. *Gastroenterology* **77** (1978) 393-400.
7. KAUR, S., MEHTA, S. K., KUMAR, B., CHAKRAVARTY, R. N. and SIDHU, H. K. Involvement of gastrointestinal tract in leprosy. *Int. J. Lep.* **46** (1978) 35-41.
8. KEAN, B. H. and CHILDRESS, M. E. A summary of 203 autopsies on leprosy patients on the Isthmus of Panama. *Int. J. Lepr.* **10** (1942) 51-59.
9. MITSUDA, K. and OGAWA, M. A study of 150 autopsies of cases of leprosy. *Int. J. Lepr.* **5** (1937) 53-60.
10. POWELL, C. S. and SWAN, L. L. Pathological changes observed in 50 consecutive necropsies. *Am. J. Pathol.* **31** (1955) 1131-1147.
11. RIDLEY, D. S. Bacterial indices. In: *Leprosy in Theory and Practice*, 2nd ed. Cochrane, R. G. and Davey, T. Frank, eds. Baltimore, Maryland, U.S.A.: Williams and Wilkins Co., 1964, pp. 620-622.
12. SAHA, K., AGARWAL, S. K. and MISRA, R. C. Gut associated IgA deficiency in lepromatous leprosy. *Scand. J. Immunol.* **8** (1978) 397-402.
13. SAXENA, H., AJWANI, K. D., PRADHAN, S., CHANDRA, J. and AJAI, K. A preliminary study on bacteremia in leprosy. *Lepr. India* **47** (1975) 79-83.
14. SHEPARD, C. C. Stability of *Mycobacterium leprae* and temperature optimum for growth. *Int. J. Lepr.* **33** (1965) 541-550.
15. VAN DE KAMER, J. H., TEN BOKKEL HUININK, H. and WEYERS, H. A. Rapid method for determination of fat in feces. *J. Biol. Chem.* **177** (1949) 347-355.