

## Preliminary Observation on Langerhans' Cells in Leprosy<sup>1</sup>

Liu Jihe, Shi Yuanfu, Kong Qingying, and Ye Gan-yun<sup>2</sup>

Since the target role of Langerhans' cells (LC) in contact allergic reactions was noted by Silberg<sup>(8)</sup>, further advances in the immunological techniques of characterizing such cells have been made<sup>(6,9)</sup>, and LC are well confirmed as special epidermal macrophages<sup>(7)</sup>. But very little is known about the condition of LC in leprosy, even about the number and shape. Accordingly, it was decided to observe the state of LC in different types of leprosy, and the investigation of their number and morphology was our first trial.

### MATERIALS AND METHODS

Skin specimens were obtained by biopsy from eight patients with active leprosy. The patients were classified according to the Ridley-Jopling classification on clinical and histological grounds as: TT, 3 cases; BT, 4 cases; BL, 1 case. None of the patients had previously been treated with any antileprosy drugs.

In seven cases of TT and BT leprosy, biopsies were taken from the well demarcated marginal area of the lesions, about  $3 \times 1.5$  cm in size. One half of each biopsy contained the leprosy lesion. The other half was the adjacent, normal-appearing skin used as the control. In the BL leprosy case, besides the biopsy of the lesion, a control specimen was obtained from the same region on the contralateral side showing no obvious lesion. The biopsies were divided into two pieces: a small piece was provided for routine histological examination (hematoxylin and eosin and Harada's acid-fast stain), and the rest was processed for the

demonstration of LC using an enzyme histochemical technique for ATPase as described by Juhlin and Shelley<sup>(4)</sup>.

Quantitative cell counts were made as described by Brown, *et al.*<sup>(2)</sup> on epidermal sheets by means of a reticule fitted into the eyepiece of a microscope with an objective lens of  $\times 16$ . The size of the field outlined by the reticule was calibrated; the cells in each of ten randomly chosen fields were counted, and cell populations were expressed as the mean number of cells per square millimeter of epidermis. The morphology of the LC was also examined with these epidermal sheets microscopically.

### RESULTS

Individual values obtained from the eight patients examined are shown in The Table. The number of ATPase-positive dendritic LC in normal appearing skin varied from  $266/\text{mm}^2$  to  $548/\text{mm}^2$  (mean 376). In involved areas, the number varied from  $103/\text{mm}^2$  to  $256/\text{mm}^2$  (mean 184). These differences were highly significant statistically. In addition, the dendritic processes of LC in these epidermal sheets from involved areas appeared to be reduced in number, shortened, or diminished (Figs. 1 and 2).

### DISCUSSION

In 1956, Richter<sup>(5)</sup> used Ferreira-Marques' method for the demonstration of LC in the epidermis overlying leprosy lesions and found that they were damaged early in leprosy. They were not only reduced in number but were also typically degenerated. These observations were based solely upon light microscopic examination of skin sections impregnated with gold chloride. Six years later, Breathnach, *et al.*<sup>(1)</sup> investigated nine patients with leprosy, using similar materials both with Gaion's technique of impregnation with gold chloride and electron microscopy. With the possible exception of one tuberculoid case, they found that the number of LC was not greatly re-

<sup>1</sup> Received for publication on 2 February 1982; accepted for publication in revised form on 25 March 1982.

<sup>2</sup> Liu Jihe, Vice-Chief of Department of Dermatopathology; Shi Yuanfu, Research Assistant; Kong Qingying, Research Associate, Ye Gan-yun, Deputy Director, Institute of Dermatology, Chinese Academy of Medical Sciences, 2 Jiankang Road, Taizhou, Jiangsu, People's Republic of China.

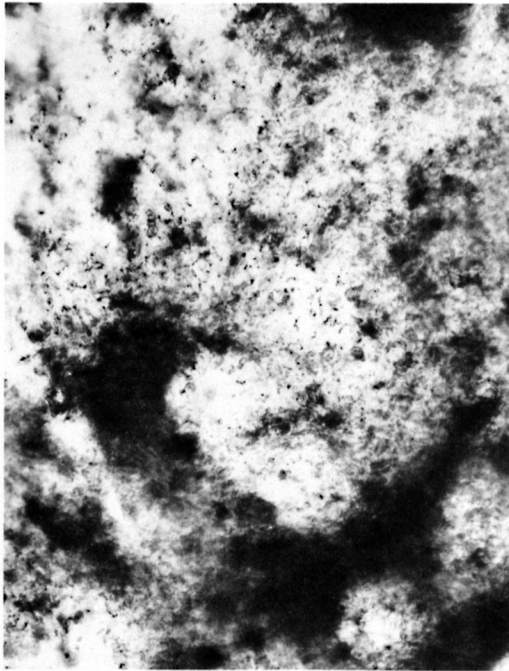


FIG. 1. Langerhans' cells were destroyed in the annular erythematous lesion of a 48-year-old female patient with TT leprosy of six months' duration. The lesion was located on the lateral surface of the left thigh ( $\times 300$ ).




FIG. 2. Langerhans' cells in the normal appearing skin of the same patient at the same site ( $\times 300$ ).

duced. The morphology of the majority of the LC in their gold-impregnated material appeared to be normal, but some of them displayed features identical to those of de-

generated cells as defined by Richter. Therefore, they believed that the occurrence of degenerated cells could be attributed to poor impregnation. Under the elec-

THE TABLE. Langerhans' cell counts in involved skin and normal appearing skin in leprosy.

Case no.	Sex	Age	Duration (yr)	Classification	Site	Clinical appearance	Langerhans' cells (no./mm <sup>2</sup> )	
							Involved skin	Normal appearing skin
1	F	49	1	TT	thigh	annular erythema	103	548
2	M	47	1	BL	thigh	yellowish erythema	211	341
3	F	38	5	BT	buttock	erythema	191	342
4	F	17	1	BT	pretibial	erythema	207	410
5	F	46	1	BT	buttock	erythema reddish	172	362
6	F	29	3	BT	thigh	depigmented macule	256	414
7	M	27	3	TT	thigh	erythema	167	324
8	M	49	1	TT	knee	erythema	167	266
Mean $\pm$ standard deviation							184.3 $\pm$ 44.4 <sup>a</sup>	375.9 $\pm$ 84.2

<sup>a</sup> Significantly less than normal appearing skin,  $p < 0.01$ , Student's *t* test for paired comparisons.

tron microscope, LC in leprosy appeared to be essentially normal. In 1972, Job, *et al.* (3) studied two cases of indeterminate leprosy with electron microscopy and noticed that a number of LC had atrophic changes and that there was an appreciable increase in their number. Most of the eight cases of leprosy in the present study were classified at TT and BT. In these cases, the number of LC was obviously reduced in involved skin compared with the number of LC in uninvolved areas.

The enzyme histochemical method for the demonstration of ATPase is now widely accepted as a simple, reproducible, and probably specific demonstration of LC in several mammalian species. When applied to isolated epidermal sheets, it is an ideal method for quantitatively evaluating the LC population. Although LC in our specimens showed their dendritic processes to be reduced in number, shortened, or diminished, the morphology observed in the epidermal sheets was not satisfactory. Further detailed study with electron microscopy is needed.

#### SUMMARY

Langerhans' cells were enumerated in the skin of eight borderline and tuberculoïd leprosy patients by the enzymatic histochemical demonstration of ATPase in these cells in epidermal sheets. The number of Langerhans' cells was significantly reduced in the skin lesions of these patients compared with normal appearing skin from the same patients. The morphological details of these cells were not clear under light microscopy; further study with electron microscopy is desirable.

#### RESUMEN

Se enumeraron las células de Langerhans en la piel de ocho pacientes con lepra intermedia o tuberculoïde por la demostración histoquímica de ATPasa en estas células presentes en las capas epidérmicas. El número de células de Langerhans estuvo significativamente reducido en las lesiones dérmicas de estos pacientes en comparación con el observado en la piel no lesionada de los mismos pacientes. Los detalles morfológicos de estas células no fueron claros bajo la microscopía de

luz; es pertinente extender estos utilizando microscopía electrónica.

#### RÉSUMÉ

On a procédé à l'énumération des cellules de Langerhans dans la peau de huit malades atteints de lèpre borderline et tuberculoïde. La méthode utilisée était basée sur la démonstration histochimique enzymatique de l'ATPase dans ces cellules des couches épidermiques. Le nombre de cellules de Langerhans était significativement diminué dans les lésions cutanées chez ces malades, par comparaison avec les résultats obtenus par l'examen de peau normale prélevée chez ces mêmes malades. Les détails morphologiques de ces cellules n'apparaissaient pas clairement à la microscopie optique. Il serait souhaitable de procéder à une étude par microscopie électronique.

#### REFERENCES

1. BREATHNACH, A. S., BIRBECK, M. S. and EVERALL, J. D. Observations on Langerhans' cells in leprosy. *Br. J. Dermatol.* **74** (1962) 243-253.
2. BROWN, J., WINKELMANN, R. K. and WOLFF, K. Langerhans cells in vitiligo; a qualitative study. *J. Invest. Dermatol.* **49** (1967) 386-390.
3. JOB, C. K., NAYAR, A. and NARAYANAN, J. S. Electromicroscopic study of hypopigmented lesions in leprosy; a preliminary report. *Br. J. Dermatol.* **87** (1972) 200-212.
4. JUHLIN, L. and SHELLY, W. B. New staining techniques for the Langerhans' cell. *Acta Derm. Venereol. (Stockh.)* **57** (1977) 289-296.
5. RICHTER, R. Studien zur Neurohistologie der nervösen vegetativen Peripherie der Haut bei verschiedenen chronischen infektiösen Granulomen mit besonderer Berücksichtigung der Langerhansschen Zellen. *Leprosy. Arch. Dermatol. Forsch.* **202** (1956) 518-555.
6. ROWDEN, G. and LEWIS, M. G. Langerhans' cell: Involvement in the pathogenesis of mycosis fungoides. *Br. J. Dermatol.* **95** (1976) 655-672.
7. ROWDEN, G., PHILIPS, T. M., LEWIS, M. G. and WILKINSON, R. D. Target role of Langerhans' cells in mycosis fungoides: Transmission and immunoelectronmicroscopic studies. *J. Cutan. Pathol.* **6** (1979) 364-382.
8. SILBERG, I. Apposition of mononuclear cells in Langerhans' cells in contact allergic reactions: An ultrastructural study. *Acta Derm. Venereol. (Stockh.)* **53** (1973) 1-12.
9. STINGL, G., KATZ, S. I., SHEVACH, E. M., ROSENTHAL, A. S. and GREEN, I. Analogous functions of macrophages and Langerhans' cells in the initiation of the immune response. *J. Invest. Dermatol.* **71** (1978) 59-64.