

## Leprous Synovitis. A Study of Fifty Cases<sup>1</sup>

Vasudeva V. Holla, Maneesha V. Kenetkar, Madhav K. Kolhatkar,  
and Chandrashekhar N. Kulkarni<sup>2</sup>

By and large, we think of leprosy as a painless disease. However, some patients with lepromatous leprosy attending our hospital complain of neuritis. In the majority of these patients neuropathic joint involvement and joint involvement secondary to paralysis of muscles acting on the joint as well as arthritis associated with acute lepra reaction could be ruled out. The present study was undertaken to determine if primary synovial involvement could be the cause of arthritis in these patients.

### MATERIALS AND METHODS

A study of synovial biopsies in 50 lepromatous leprosy patients presenting with arthritis was carried out at General Hospital and Dr. V. M. Medical College, Solapur, India, during the year 1979–80. All the cases were confirmed as having lepromatous leprosy by skin biopsy. These patients had been treated for variable periods of time. Patients with any other specific cause for joint involvement were excluded from the study. Of these 50 lepromatous patients, 14 showed clinical evidence of lepra reaction. An additional ten patients with lepromatous leprosy under treatment, but without joint complaints, were also studied as controls.

Before taking the synovial biopsy of the knee joint, it was confirmed that no lepromatous skin lesions were present over the knee joint. Radiological studies of the involved joint were carried out in each case. Additional studies included a VDRL, rheumatoid factor, complete hemogram, and complete urinalysis in each subject.

Synovial tissue (1.0 × 0.5 cm) was surgically removed and fixed in 10% formalin. Sections of 5 μ thickness were cut after pro-

cessing and paraffin embedding and stained with hematoxylin and eosin (H & E). Each section was also stained with Fite's stain to demonstrate acid-fast bacilli.

### RESULTS

**Clinical observations.** Of the 50 patients with arthritis studied, the highest number of cases (23) were in the third decade of life. All were taking their antileprosy treatment regularly by history. Most had been on treatment for from 1–5 years (Table 1).

TABLE 1. *Duration of antileprosy treatment.*

Treatment (yrs)	No. of patients
Untreated	1
<1	5
1–5	29
6–10	11
≥11	4
Total	50

The pattern of joint involvement is given in Table 2. In six cases there was bilateral involvement of the knee joint only. In 44 cases other joints were involved in addition to the knee joints.

TABLE 2. *Pattern of joint involvement.*

Joint affected	No. (%) of cases
Knee	50 (100)
Ankle	18 (36)
Wrist	9 (18)
Elbow	9 (18)

**Histopathology.** In the ten lepromatous leprosy patients under treatment and with no joint complaints studied as controls, no histopathological abnormalities in the synovium could be detected. In contrast, chronic synovitis was present in all 50 cases who had presented with arthritis. In the 36 patients who presented with arthritis

<sup>1</sup> Received for publication on 13 February 1981; accepted for publication revised form on 19 November 1982.

<sup>2</sup> V. V. Holla, M.D., D.C.P., D.P.B., Reader in Pathology; M. V. Kanetkar, M.D., D.C.P., Reader in Pathology; M. K. Kolhatkar, M.D., Professor of Pathology and C. N. Kulkarni, M. S., Registrar in Orthopedics, Dr. V. M. Medical College, Solapur 413003, India.

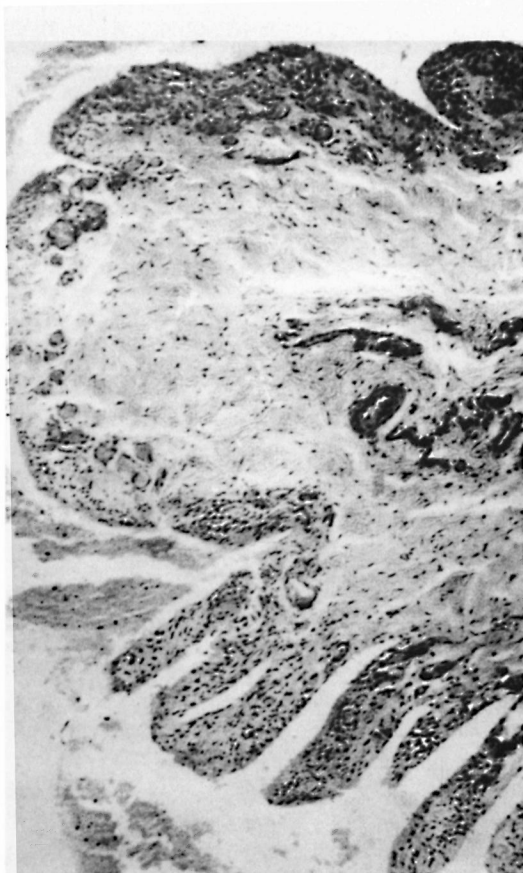


FIG. 1. Villous hypertrophy and thickening of synovial lining (H & E  $\times 160$ ).

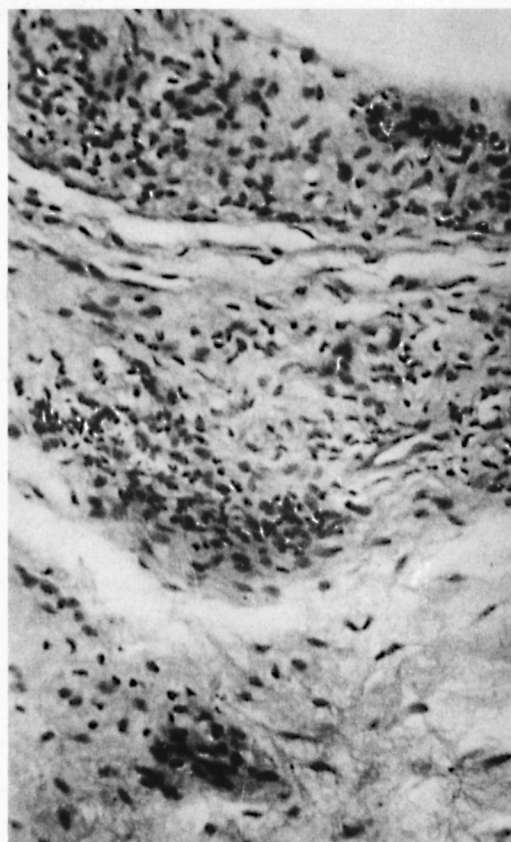


FIG. 2. Macrophage granuloma in synovial tissue (H & E  $\times 400$ ).

not associated with lepra reaction, the synovial lining showed hyperplasia and villous hypertrophy (Fig. 1), and the synovial tissue showed congestion, pannus formation, and the presence of macrophage granulomas (Fig. 2). Macrophage granulomas were also observed in the lining epithelium, soft tissue, and nerve bundle. In two cases, giant cells with cytoplasmic vacuoles were observed in the granuloma (Fig. 3) and nine cases showed intact, acid-fast bacilli in the granulomas.

In the remaining 14 cases whose arthritis was associated with lepra reaction, there was vasculitis and focal infiltration by mononuclear cells in addition to synovial thickening (Fig. 4). In nine of these 14 cases, fragmented acid-fast bacilli were present in the endothelial lining of blood vessels. However, villous hypertrophy, pannus formation, and macrophage granulomas, all of which were characteristically seen in the first

group of 36 cases (arthritis not associated with lepra reaction), were not seen in these 14 cases (arthritis associated with lepra reaction).

#### DISCUSSION

In the present study a histopathological examination of the synovium was carried out in patients with lepromatous leprosy complaining of arthritis. In 14 cases, with clinical evidence of lepra reaction and arthritis, our histopathological study revealed the presence of vasculitis and lymphocytic infiltration of the synovium. In the remaining 36 cases without lepra reaction our histopathological study showed granulomatous infiltration of the synovium and, in some cases, the presence of acid-fast bacilli. Synovial involvement in lepra reaction is well documented<sup>(1, 2, 4, 6)</sup>. On the other hand, to our knowledge, infiltration of the synovium with the presence of acid-fast bacilli

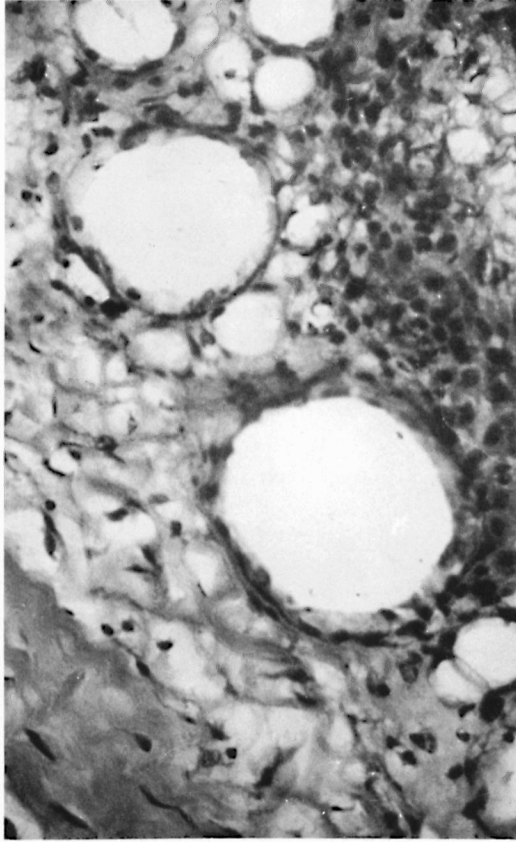


FIG. 3. Giant cells with cytoplasmic vacuoles in the granuloma (H & E  $\times 600$ ).

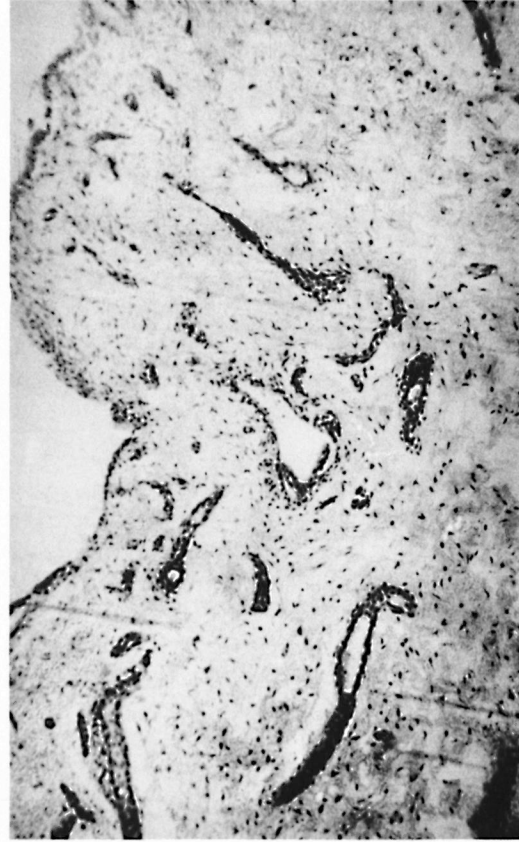


FIG. 4. Vasculitis and mononuclear cell infiltration in deeper synovial tissue (H & E  $\times 160$ ).

has been reported previously only by Lele, *et al.* (<sup>3</sup>). These authors performed synovial biopsies to diagnose the cause of arthritis in their patients and, in six of the 13 cases, observed specific changes of lepromatous leprosy in the synovium.

Since no skin lesions were observed on the knee joint, and since radiological examination ruled out involvement of bone, it can be inferred that bacillemia may be responsible for this primary synovial involvement. Dissemination of the bacilli to distant organs through the bloodstream and the occurrence of bacillemia in leprosy has been repeatedly confirmed (<sup>3</sup>). Since other obvious causes of arthritis were ruled out by clinical and radiological examination and by laboratory investigations, it is likely that the primary synovial involvement in the 36 non-reactional cases was responsible for the arthritis.

## SUMMARY

A study of 50 synovial biopsies of proved lepromatous patients with arthritis was carried out. Out of these 50 cases, 14 cases were suffering from lepra reaction and the histopathological study of the synovium in these 14 cases revealed the presence of only vasculitis and lymphocytic infiltration. In the remaining 36 cases, not associated with lepra reaction, the synovial lining showed hyperplasia and villous hypertrophy, and the synovial tissue showed congestion, pannus formation, the presence of macrophage granulomas and, in some cases, even intact acid-fast bacilli. Since there was no other cause for arthritis, it is perhaps likely that the primary synovial involvement in these 36 cases may be the cause of the arthritis. In the ten cases of lepromatous leprosy without arthritis studied as controls, no his-

topathological abnormality in the synovium could be detected.

### RESUMEN

Se hizo un estudio de 50 biopsias sinoviales de pacientes lepromatosos con artritis. Catorce de los 50 pacientes presentaban reacción leprosa y el estudio histopatológico del sinovio en estos 15 casos reveló sólo la presencia de vasculitis e infiltración linfocítica. En los 36 casos restantes, no asociados con reacción leprosa, el recubrimiento sinovial mostró hiperplasia e hipertrofia vellosa en tanto que el tejido sinovial mostró congestión, formación de pannus, la presencia de granulomas macrofágicos y, en algunos casos, bacilos ácido-resistentes intactos. Puesto que no había otra causa de la artritis, es quizá posible que la afección sinovial primaria en estos 36 casos pudiera ser la causa de la misma. En los 10 casos de lepra lepromatosa sin artritis estudiados como controles, no se observaron anomalías histopatológicas.

### RÉSUMÉ

On a procédé à l'étude de 50 biopsies de la synoviale chez des malades atteints de lèpre lépromateuse confirmée, et souffrant d'arthrite. Parmi ces 50 cas, 14 présentaient une réaction lépreuse. Chez ces 14 cas, l'étude histopathologique de la synoviale a révélé la présence uniquement de vascularité et d'une infiltration lymphocytaire. Chez les 36 autres cas, qui ne souffraient pas de réaction lépreuse, le revêtement synovial présentait une hyperplasie et une hypertrophie villositaire; le tissu synovial montrait de la congestion, la formation de pannus, et la présence de granulomes à macro-

phages, et même, dans certains cas, des bacilles acido-résistants intacts. Comme il n'y avait pas d'autres causes d'arthrite, il semble que l'atteinte synoviale primaire chez ces 36 malades pourrait être à l'origine de l'arthrite. Chez les 10 cas de lèpre lépromateuse sans arthrite qui ont été étudiés comme témoins, aucune anomalie histopathologique n'a pu être mise en évidence.

**Acknowledgments.** The authors are grateful to the Dean, Dr. V. M. Medical College at Solapur, and to Dr. M. S. Despande, Professor and Head of the Department of Pathology, for providing the facilities, and also to Dr. J. J. Balsa-ra for assisting with the manuscript.

### REFERENCES

1. BROWNE, S. G. Erythema nodosum in leprosy. *J. Chronic Dis.* **16** (1963) 23-30.
2. KARAT, A. B. A., KARAT, S., JOB, C. K. and FURNESS, M. A. Acute exudative arthritis in leprosy. Rheumatoid-arthritis-like syndrome in association with erythema nodosum leprosum. *Br. Med. J.* **3** (1967) 770-772.
3. LELE, R. D., SAINANI, G. S. and SHARMA, K. D. Leprosy presenting as rheumatoid arthritis. *J. Assoc. Phys. India* **13** (1965) 275-277.
4. MODI, T. H. and LELE, R. D. Acute joint manifestations in leprosy. *J. Assoc. Phys. India* **17** (1969) 247-254.
5. PADMA, M. N., DESIKAN, K. V. Bacillaemia in leprosy. *Indian J. Med. Res.* **63** (1975) 888-892.
6. RAMU, G. and BALAKRISHNAN, S. Arthritis in lepromatous leprosy. Clinical features and biochemical findings. *Lepr. India* **40** (1968) 62-69.