

## Small Bowel Deposition of Crystals Associated with the Use of Clofazimine (Lamprene®) in the Treatment of Prurigo Nodularis<sup>1</sup>

Pierre Belaube, Jean Devaux, Marthe Pizzi, Richard Boutboul, and Yvan Privat<sup>2</sup>

Clofazimine (Lamprene®; B663) was first used in the treatment of leprosy by Browne in 1962 (3) and has also proved successful in the management of various other conditions. Although its gastrointestinal side effects are well known, we report an interesting and unusual case.

### Case report

A 46-year-old woman with widespread prurigo nodularis, which had failed to respond to treatment, was first admitted to our hospital in 1978. Laboratory investigations were normal except for a depression of cell-mediated immunity; anergic skin test results to *Candida albicans* and tuberculin, diminished *in vitro* proliferative responses to phytohemagglutinin, concanavalin A, and pokeweed mitogen. The patient was therefore put on 100 mg clofazimine three times a day for six months.

Ten months after stopping the drug, she complained of abdominal pain, severe diarrhea, and weight loss. Laboratory studies disclosed the following values: hemoglobin = 9 g/dl; ESR = 110/150 mm/hr; folates = 1.4 ng/ml (normal = 3–5 ng/ml); serum total protein = 55 g/l (normal = 70 g/l); steatorrhea, D-xylose test, and other results were normal. Jejunal biopsies showed normal mucosal villous patterns, but according to the reported association of prurigo nodularis and gluten enteropathy (8,11) a gluten-free diet was instituted, leading to significant improvement of the prurigo and complete relief of the abdominal symptoms.

Twenty-two months after withdrawal of clofazimine, despite the gluten-free diet, abdominal pain and diarrhea relapsed and a laparotomy was performed. All tissues in the abdominal wall were stained bright orange-yellow. The most striking finding was the extreme congestion of the mucosa of the small bowel and the presence of enlarged lymph nodes in the mesentery. On histological examination, there was no atrophy of the intestinal mucosa and unstained frozen sections showed several black clumps deposited in the chorion of intestinal villi (Fig. 1) and in the mesenteric lymph nodes. These crystals appeared birefringent in polarized light and, ultrastructurally, they were seen in the cytoplasm of macrophages (Fig. 2).

### Comment

Clofazimine is a substituted iminophenazine dye which proved successful in the treatment of dapsone-resistant leprosy cases and in lepra reactions, especially in erythema nodosum leprosum and in steroid treatment withdrawal (8,11). It has also been tried and found useful in discoid lupus (6,12), pyoderma gangrenosum (1,16,18), and pustulosis palmaris and plantaris (17). Treatment of our patient with clofazimine was based on the immunostimulant properties of this drug, especially its enhancing effect on phagocytosis by neutrophils (2).

Although clofazimine is usually regarded as relatively free of serious side effects (8,11), when used in high dosage (300 mg daily) over prolonged periods (4–6 months) crystallization of the drug is known to occur in various tissues (4,5,7,10,13,14). Harvey, *et al.* (7) reported a case which ultimately proved fatal. Our case presents some unusual features. First, the abdominal symptoms did not occur until ten months after the clofazimine had been discontinued. This prolonged symptom-free interval has not pre-

<sup>1</sup> Received for publication on 15 June 1982; accepted for publication in revised form on 21 April 1983.

<sup>2</sup> P. Belaube, M.D., Assistant; J. Devaux, M.D., Assistant, Department of Dermatology, Hôtel-Dieu, 13002 Marseille, France. M. Pizzi, M.D., Assistant, Department of Histopathology, Hôpital Nord, 13015 Marseille, France. R. Boutboul, M.D., Assistant, Department of Surgery; Y. Privat, M.D., Professor, Department of Dermatology, Hôtel-Dieu, 13002 Marseille, France.

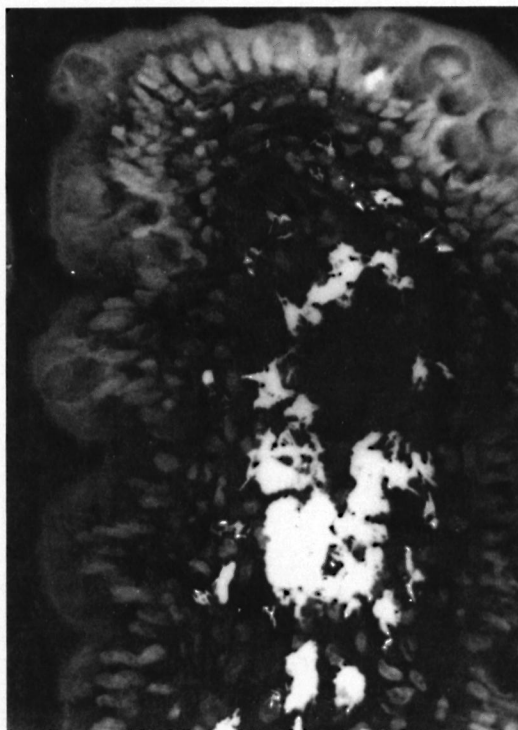


FIG. 1. Crystals in the chorion of intestinal villi ( $\times 250$ ).

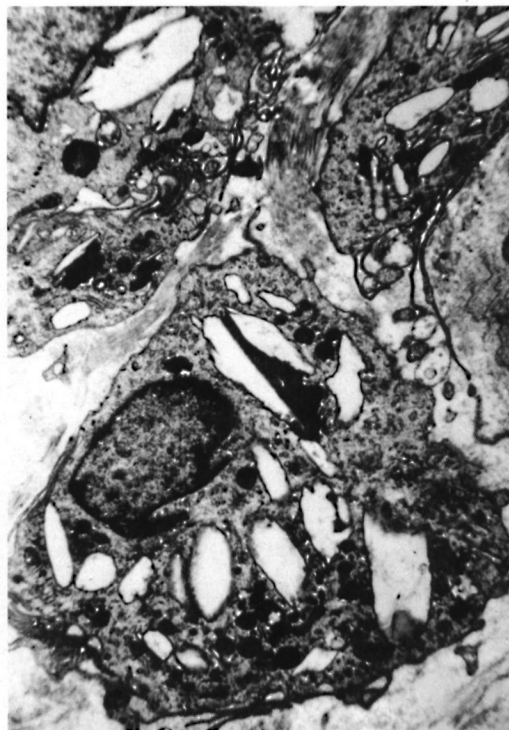

FIG. 2. Ultrastructural presence of numerous crystals in macrophage cytoplasm ( $\times 20,000$ ).

viously been observed in patients developing an enteropathy due to clofazimine. Secondly, the patient improved on a gluten-free diet, and despite the jejunal biopsy this might represent a gluten enteropathy aggravated by the clofazimine intake.

These unwanted side effects should be avoided by using clofazimine in dosage of 100 mg three times weekly; higher doses should be employed only under close clinical and laboratory supervision.

#### SUMMARY

A 46-year-old woman with widespread prurigo nodularis was treated with 300 mg clofazimine a day for six months. Ten months after stopping the drug she complained of weight loss and gastrointestinal side effects which were shortly improved by a gluten-free diet, but relapsed one year later. At laparotomy, all tissues were stained bright orange-yellow, and histological examination showed crystals deposited in the chorion of intestinal villi and in the mesenteric lymph nodes.

#### RESUMEN

Una paciente de 46 años de edad con prurigo nodularis difuso se trató con 300 mg de clofazimina al día durante 6 meses. Diez meses después de haber suspendido la ingesta de la droga, la paciente presentó pérdida de peso y alteraciones gastrointestinales las cuales fueron rápidamente controladas con una dieta libre de gluten pero la paciente recayó un año después. En la laparotomía se encontró que todos los tejidos estuvieron teñidos de color amarillo-naranja brillante, y el examen histológico demostró la presencia de cristales depositados en el córion de las vellocidades intestinales y en los ganglios linfáticos mesentéricos.

#### RÉSUMÉ

Une femme âgée de 46 ans, et atteinte d'un prurigo nodulaire largement disséminé, a été traitée par 300 mg de clofazimine par jour pendant 6 mois. Dix mois après l'interruption du traitement, elle s'est plainte de perte pondérale et d'effets secondaires gastro-intestinaux, qui ont été temporairement soulagés par un régime sans hydrates de carbone. On a cependant enregistré une récurrence une année plus tard. Lors de la laparotomie, tous les tissus se coloraient en jaune-orange, et l'examen histologique a révélé des dépôts cristallins dans le chorion des villosités intestinales et dans les ganglions nodulaires mésentériques.

## REFERENCES

1. BEUREY, J., WEBER, M., DELROUS, J. L. and CHAULIEU, Y. Pyoderma gangrenosum: thérapeutique par clofazimine. *Ann. Dermatol. Venereol.* **104** (1977) 631-634.
2. BRANDT, L. Enhancing effect of clofazimine (B663) on the phagocytosis of neutrophil leucocytes *in vitro*. *Scand. J. Haematol.* **8** (1971) 266-269.
3. BROWNE, S. G. and HOGERZEIL, L. M. "B 663" in the treatment of leprosy. Preliminary report of a pilot trial. *Lepr. Rev.* **33** (1962) 6-10.
4. DESIKAN, K. V., RAMANUJAM, D., RAMU, A. and BALAKRISHNAN, S. Autopsy findings in a case of lepromatous leprosy treated with clofazimine. *Lepr. Rev.* **46** (1975) 181-189.
5. DESIKAN, K. V. and BALAKRISHNAN, S. Tissue levels of clofazimine in a case of leprosy. *Lepr. Rev.* **47** (1976) 107-111.
6. DUPRE, A., BONAFE, J. L., LASSERE, J., ALBAREL, N. and CHRISTOL, B. Traitement du lupus érythémateux chronique par le Lamprène (clofazimine). Etude préliminaire. *Ann. Dermatol. Venereol.* **105** (1978) 423-425.
7. HARVEY, R. F., HARMAN, R. R. M., BLACK, C., READ, A. E., BADDELEY, H., DAVIES, J. and ESPINER, H. J. Abdominal pain and malabsorption due to tissue deposition of clofazimine (Lamprene) crystals. *Br. J. Dermatol.* **96** (1977) 19-20.
8. HASTINGS, R. C., JACOBSON, R. R. and TRAUTMAN, J. R. Long-term clinical toxicity studies with clofazimine (B663) in leprosy. *Int. J. Lepr.* **44** (1976) 287-293.
9. HOWELL, R. Exsudative nummular prurigo with idiopathic malabsorption syndrome. *Br. J. Dermatol.* **79** (1967) 387.
10. JAGADEESAN, K. and VISWESWARAN, M. K. and IYER, K. H. Acute abdomen in a patient treated with Lamprene. *Int. Surg.* **60** (1975) 208-209.
11. JOPLING, W. H. Complications of treatment with clofazimine (Lamprene B663). *Lepr. Rev.* **47** (1976) 1-3.
12. MACKAY J. P. and BARNES J. Clofazimine in the treatment of discoid lupus erythematosus. *Br. J. Dermatol.* **91** (1974) 93-96.
13. MALSON, G. H., ELLIS-PEGLER, R. B. and ARTHUR, J. F. Clofazimine and eosinophilic enteritis. *Lepr. Rev.* **48** (1977) 175-180.
14. MCDUGALL, A. C., HORSEFALL, W. R., HEDE, J. E. and CHAPLIN, A. J. Splenic infarction and tissue accumulation of crystals associated with the use of clofazimine (Lamprene B. 663) in the treatment of pyoderma gangrenosum. *Br. J. Dermatol.* **102** (1980) 227-340.
15. MCKENZIE, A. W., STUBBING, D. G. and ELVY, B. L. Prurigo nodularis and gluten enteropathy. *Br. J. Dermatol.* **95** (1976) 89-92.
16. MICHAELSSON, G., MOLIN, L., OHMAN, S., GIP, L., LINDSTROM, B., SKOGH, M. and TROLIN, I. Clofazimine: a new agent for the treatment of pyoderma gangrenosum. *Arch. Dermatol.* **112** (1976) 344-349.
17. MOLIN, L. Clofazimine: enhanced phagocytosis in pustulosis palmaris and plantaris. *Acta Derm. Venereol. (Stockh.)* **55** (1975) 151-153.
18. THOMSEN, K. and ROTHENBORG, H. W. Clofazimine in the treatment of pyoderma gangrenosum. *Arch. Dermatol.* **115** (1979) 851-852.