

Observations on Langerhans' Cells in Leprosy Using Monoclonal Antibody OKT6¹

Liu Ji-he, Shi Yuan-fu, Kong Qing-ying, Yang Li-he,
Li Weng-zhong, and Ye Gan-yun²

In our previous report (²), Langerhans' cells (LC) were enumerated in the skin of eight borderline and tuberculoid leprosy patients by the enzymatic histochemical demonstration of ATPase in these cells in epidermal sheets. The number of LC was significantly reduced in the skin lesions of these patients compared with normal-appearing skin from the same site of the same patients. Their dendritic processes appeared to be reduced in number, shortened or diminished. Similar morphologic changes of LC were demonstrated by transmission electron microscopy (TEM) in the skin lesion of another borderline case (³).

The present study was undertaken to observe the change of LC in leprosy lesions using the monoclonal antibody OKT6.

MATERIALS AND METHODS

Seven patients with different types of leprosy, confirmed by clinical and histopathological examination according to the Ridley-Jopling classification, were studied. Brief clinical data on these subjects are shown in The Table.

Skin biopsies were taken from sharply demarcated lesions. Frozen sections of 6 μ thickness were prepared, dried for 30 min with an electric fan (unheated air), and fixed in acetone at room temperature for 8 min. These sections were washed with 0.1 M phosphate buffered saline (PBS), pH 7.4, before incubation.

Then the sections were incubated with mouse monoclonal antibody, FITC conjugated OKT6 (Ortho Pharmaceutical Corp.,

U.S.A.) in a previously determined dilution (1:16) for 30 min at 37°C in a humidified chamber. After washing in PBS, the sections were examined under an Olympus immunofluorescence microscope.

RESULTS

In the epidermis of the leprosy lesions of most cases, the processes of the LC were reduced or diminished. Some LC were disintegrated. In case 1 (TT), some fluorescent debris was seen in the epidermis besides a few intact LC. In case 5 (BT), most LC had disappeared from the surface epidermis but some disintegrated LC were seen in the hair follicle (Fig. 1). In cases 2 (Fig. 2) and 3 (BT in upgrading or type 1 reaction), there were increased numbers and aggregation of OKT6-positive cells in clusters in some areas of the epidermis, but in the area of the epidermis with atrophy, liquefaction or destruction, LC were still disintegrated. No obvious change in LC was seen in the dermis.

DISCUSSION

According to Dubertret, *et al.* (¹), OKT6 reacts specifically with LC but not with macrophages in human skin. Therefore the use of this monoclonal antibody technique in the investigation of LC in leprosy is the best method to date. It is more specific than the ATPase method, not only demonstrating LC in the epidermis but also in the dermis. In normal skin, LC have OKT6-positive cell surfaces and dendritic processes, distribute evenly and uniformly, and are mainly located in the mid-epidermis. A few OKT6-positive cells may occasionally be seen within the papillary dermis.

In recent years the changes in LC in leprosy have been re-emphasized. After our previous report (²), van Voorhis, *et al.* (⁴) found increased numbers of OKT6-positive cells in clusters in the epidermis just above

¹ Received for publication on 9 February 1984; accepted for publication in revised form on 31 May 1984.

² J. Liu, M.D., Vice-chief, Department of Dermatopathology; Y. Shi, Research Assistant; Q. Kong, Research Associate; L. Yang, M.D., Associate Professor; W. Li, Research Associate; G. Ye, M.D., Deputy Director, Institute of Dermatology, Chinese Academy of Medical Sciences, 100 Jiang-wang-miao, Tai-ping-men, Nanjing, Jiangsu, People's Republic of China.

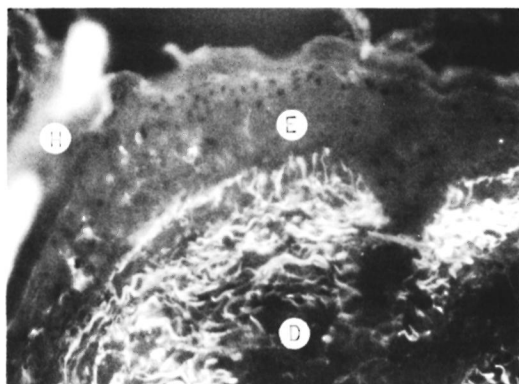


FIG. 1. Case 5, BT. Most Langerhans' cells (LC) have disappeared in the surface epidermis, but some disintegrated LC are shown in the hair follicle. E = epidermis; D = dermis; H = hair.

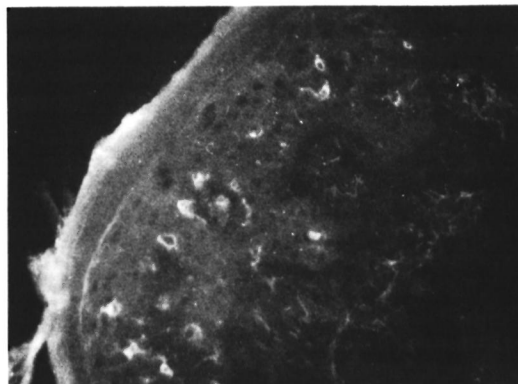


FIG. 2. Case 2, BT (in type 1 or upgrading reaction). Increased numbers and aggregation of OKT6-positive cells in a cluster in the epidermis of a leprosy lesion. Some of the LC are disintegrated or their processes diminished.

the dermal infiltrates in 8 of 21 patients with leprosy (including 6 tuberculoid, 5 borderline, and 10 lepromatous cases). OKT6-positive cells were seen in superficial dermal infiltrates as well as in four patients. The morphological changes in the LC observed in the present study using the monoclonal antibody technique were similar to those of our previous observation^(2, 3). Some of the results were similar to those of van Voorhis, i.e., increased numbers and aggregation of OKT6-positive cells in clusters in the epidermis of two cases of BT (in upgrading or type 1 reaction). Disintegration of LC was also seen, and seemed to be related to histopathological changes in the epidermis. Thus LC may be involved in the pathogenesis of leprosy and its reaction. In order to further identify the morphological changes in LC in leprosy, immuno-electron microscopic observation is necessary.

SUMMARY

Changes in the Langerhans' cells (LC) in seven cases of leprosy were observed using the monoclonal antibody OKT6. In the epidermis of the lesions of most of the leprosy cases, the processes of LC were reduced or diminished. Some LC were disintegrated. In two BT cases in the upgrading (type 1) reactional stage, either increased numbers and aggregation of OKT6-positive cells in clusters or their disintegration was seen in different areas of the epidermis.

RESUMEN

Usando el anticuerpo monoclonal OKT6 se observaron cambios en las células de Langerhans (CL) en 7 casos de lepra. En la epidermis de las lesiones de la mayoría de los casos, los procesos (prolongaciones citoplásmicas) de las CL estuvieron reducidos o disminuídos. Algunas CL estuvieron desintegradas. En 2 ca-

THE TABLE. *Brief clinical data on the patients.*

Case no.	Sex	Age	Duration	Classification	Site	Clinical appearance
1	F	29	2 mos.	TT	Right foot	Erythema
2	M	26	1 mo.	BT ^a	Left lumbar	Erythema
3	M	25	1 yr.	BT ^a	Right knee	Erythema
4	F	22	6 mos.	BT	Left thigh	Erythema
5	F	30	1 yr.	BT	Left post-auricular	Purplish-brown macule
6	M	60	3 yrs.	BT	Right cheek	Annular erythema
7	F	47	6 mos.	BT	Left wrist	Annular brownish erythema

^a Patient in type 1 or upgrading reaction.

ses BT en réaction reversa (tipo 1), se observó o bien un incremento en el número y en la agregación de las células OKT6 positivas, o bien su desintegración en diferentes áreas de la epidermis.

RÉSUMÉ

On a observé des modifications au niveau des cellules de Langerhans chez 7 cas de lèpre, au moyen d'une méthode utilisant dans l'anticorps monoclonal OKT6. Dans la plupart des cas de lèpre, l'activité des cellules de Langerhans était réduite au niveau de l'épiderme des lésions. Certaines de ces cellules étaient déinstégréées. Dans deux cas réactionnels BT de type 1 ("up-grading"), on a observé dans différentes régions de l'épiderme, soit une augmentation du nombre de cellules et l'aggrégation en amas des cellules positives pour l'anticorps monoclonal OKT6, ou bien leur désintégration.

REFERENCES

1. DUBERTRET, L., PICARD, O., BAGOT, M., TULLIEZ, M., FOSSE, M., AUBERT, C. and TOURAINE, R. Specificity of monoclonal antibody anti-T-6 for Langerhans' cells in normal human skin. *Br. J. Dermatol.* **106** (1982) 287-289.
2. LIU, J., SHI, Y., KONG, Q. and YE, G. Preliminary observation on Langerhans' cells in leprosy. *Int. J. Lepr.* **50** (1982) 316-318.
3. LIU, J., ZHU, Y., GU, C. and WANG, T. Preliminary observation on the ultrastructure of Langerhans' cells in leprosy. *Acta Xui Zhou Med. College* **2** (1982) 9-12.
4. VAN VOORHIS, W. C., KAPLAN, G., SARNO, E. N., HORWITZ, M. A., STEINMAN, R. M., LEVIS, W. R., NOGUEIRA, N., HAIR, L. S., GATTASS, C. R., ARRICK, B. A. and COHN, Z. A. The cutaneous infiltrates of leprosy. *N. Engl. J. Med.* **307** (1982) 1593-1597.