

Experimental Reproduction of Leprosy in Seven-banded Armadillos (*Dasypus hybridus*)¹

Luis M. Baliña, Raúl P. Valdez, Miguel de Herrera,
Horacio Costa Cordova, Juan Bellocq, and Norberto Garcia²

A number of attempts have been made to infect animals with *Mycobacterium leprae* (⁸). Large numbers of leprosy bacilli from infected animals would be particularly useful for ongoing studies of the antigenicity of the bacillus and for the further development of antileprosy vaccines for high-risk contacts or for immunological stimulation of patients who already have the disease (⁵). Following the initial demonstration that *M. leprae* would multiply in the foot pads of mice by Shepard (^{10, 11}), Kirchheimer and Storrs (^{7, 13, 14}) produced disseminated leprosy in nine-banded armadillos (*Dasypus novemcinctus*). Convit, *et al.* (^{3, 4}) then showed that the Venezuelan armadillo (*D. sabanicola*) was susceptible, and Storrs, *et al.* (¹⁵) showed that the seven-banded armadillo (*D. hybridus*) was also susceptible.

In our laboratory, we have inoculated several different species of the family Dasypodidae with *M. leprae*, namely, *Chaetophractus villosus*, *Zaedus pichi*, *D. novemcinctus*, and *D. hybridus*. We have been able to reproduce leprosy only in the last two species. The present report summarizes our experience in the experimental reproduction of leprosy in four *D. hybridus*. This animal has a number of interesting characteristics, including the fact that it readily breeds in captivity in contrast to the nine-banded armadillo.

MATERIALS AND METHODS

The four seven-banded armadillos (*D. hybridus*) were captured in the province of

Buenos Aires in the central part of Argentina. This area corresponds to the vast plains in Argentina called the Pampas, an area which is not endemic for leprosy. Two of the armadillos were males and two were females. The animals were initially maintained in our breeding colony. Two years after capture, the 2 females produced litters of 9 and 6 offspring, all of which survived.

The four animals were then transferred to, and maintained in, dog cages (70 × 50 × 50 cm) for experimental inoculation with *M. leprae*. They were fed a high-protein diet consisting of cat food, milk, boiled vegetables, and meat. It was our impression that the *D. hybridus* survive better if they are given meat in their diets, while *D. novemcinctus* apparently do not require supplemental meat in their diets.

M. leprae were obtained from biopsies from untreated lepromatous patients, and suspensions were prepared to have a concentration of 1×10^8 acid-fast bacilli/ml. Techniques used for counting bacilli and for the preparation of the inocula were as described elsewhere (^{9, 12}). The acid-fast stain used was the Ziehl-Neelsen technique as routinely utilized in the Leprosy Branch of the Centers for Disease Control, Atlanta, Georgia, U.S.A.

Following inoculation, the animals were monitored for signs of infection with *M. leprae* by a) the presence of acid-fast bacilli (AFB) in smears from the earlobe, nasal mucus, and peripheral blood, b) enlarged lymph nodes, c) histopathologic examinations of earlobe biopsies, and d) clinical behavior of the animal, e.g., feeding habits, reflexes, and weight loss.

When AFB were detected in the animals, they were identified as *M. leprae* by the criteria suggested by the World Health Organization (¹⁶), namely, a) failure to grow in mycobacterial culture media (Löwenstein-Jensen and Stonebrick), b) extraction of acid-fastness with pyridine (²), c) characteristic

¹ Received for publication on 31 May 1984; accepted for publication in revised form on 19 June 1985.

² L. M. Baliña, M.D., Ph.D., Professor of Dermatology and Director, Equipo de Lepra Experimental (ELEUS), and R. P. Valdez, M.D.; M. de Herrera, M.D.; H. Costa Cordova, M.D.; J. Bellocq, D.V.M.; N. Garcia, M.D., Pathologist, ELEUS, Universidad del Salvador (Buenos Aires), Avda. Alvear 1890, Buenos Aires 1129, Argentina.

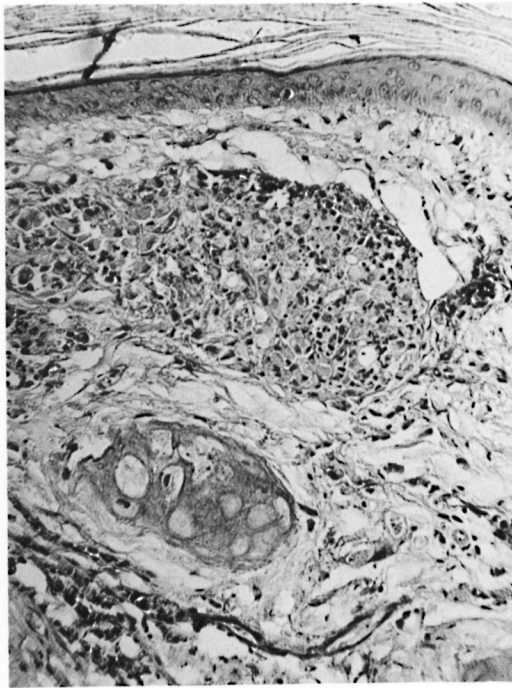


FIG. 1. Armadillo DH43. The skin shows a histiocytic granuloma (H&E $\times 300$).

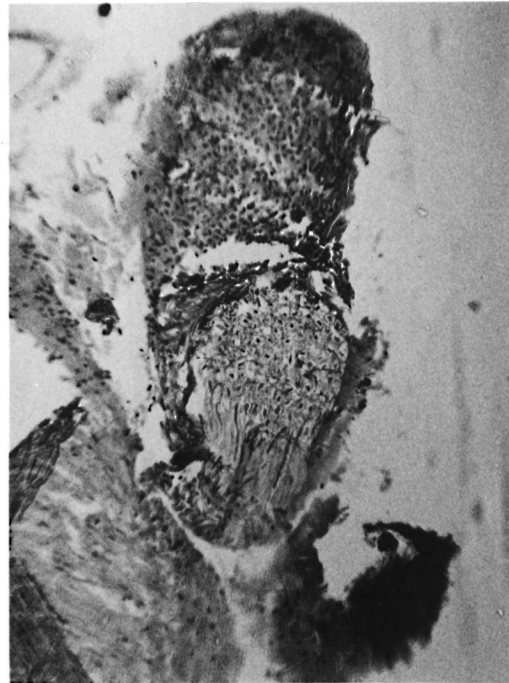


FIG. 2. Armadillo DH43 showing a peripheral nerve granuloma (H&E $\times 125$).

multiplication in the foot pads of mice^(10, 11), and d) characteristic histopathologic features.

RESULTS

A male armadillo, designated DH43, received 1.61×10^8 *M. leprae* intravenously in October 1981. In September 1982, AFB were detected in peripheral blood and ear smears. One month later, enlarged lymph nodes were noted in the abdominal wall, and the animal was sacrificed. A total of 426 days (14.2 months) elapsed between inoculation and sacrifice. Histopathologic studies demonstrated AFB in skin (Fig. 1), peripheral nerves (Fig. 2), liver, spleen, lymph nodes, lungs, striated muscle (Fig. 3), tongue, and meninges (Fig. 4), but not in the kidney, esophagus, heart, or testicles. The pyridine test was positive for *M. leprae* on the AFB obtained at autopsy. The bacilli did not grow on mycobacterial culture media after 90 days of incubation. The mouse foot pad test was not performed. The concentrations of AFB were 2.55×10^9 /g of liver and 3.02×10^9 /g of spleen.

A female armadillo, designated DH76,

which had delivered a litter of 9 offspring during captivity, received an identical inoculum of *M. leprae* as that received by the male animal DH43, i.e., 1.61×10^8 bacilli, in October 1981. In November 1982, DH76 showed AFB in blood and ear smears and had enlarged lymph nodes. In December 1984, the animal was sacrificed because of weight loss, refusal to eat, and ulcers on both hind legs. Histopathologic studies showed AFB in skin, liver, spleen, peripheral nerves, lymph nodes, lung, striated muscle, and the tongue but not in the uterus, kidney, brain, esophagus, heart or ovaries. The pyridine test was positive for *M. leprae*, and mycobacterial culture media inoculated with AFB from the liver, spleen, lymph nodes, ear, and peripheral blood showed no growth.

Portions of liver, spleen, and lymph nodes from this animal were sent to Dr. Arvind Dhople at the Florida Institute of Technology, Melbourne, Florida, U.S.A. In that laboratory the pyridine test was positive for *M. leprae*. Löwenstein-Jensen, Middlebrook, and Dubos media inoculated with AFB from these tissues showed no growth. AFB (6×10^5) were inoculated into the foot pads of

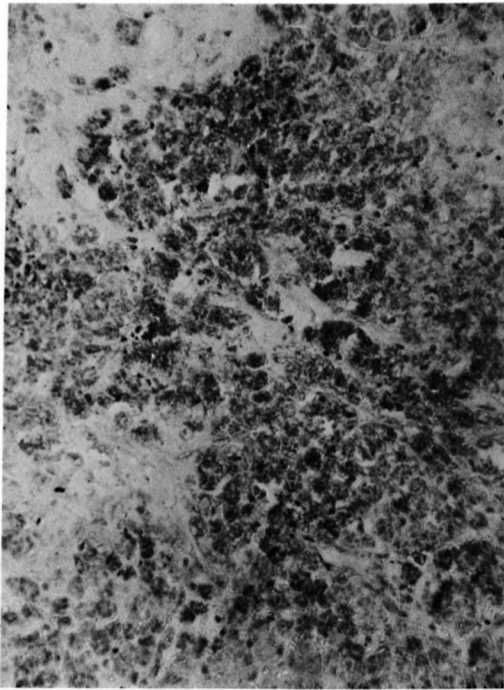


FIG. 3. Armadillo DH43, striated muscle showing areas of necrosis with abundant AFB (Ziehl-Neelsen $\times 500$).

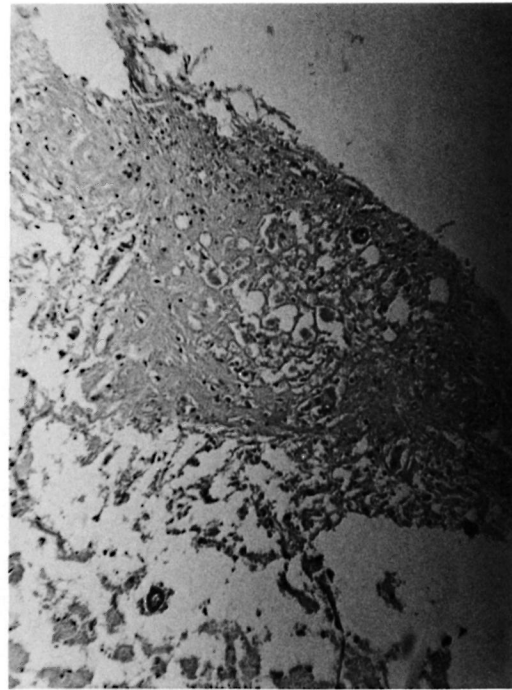


FIG. 4. Armadillo DH43, meningeal nodular granuloma (H&E $\times 125$).

mice, and the mice were sacrificed 4½ months after inoculation. With bacilli from the liver, 0.77×10^6 AFB/foot pad were harvested. With AFB from the spleen, 1.09×10^6 /foot pad were harvested, and from lymph node material, 1.1×10^6 /foot pad were harvested.

The concentrations of AFB from DH76 were 7.58×10^8 /g of liver, 4.4×10^9 /g of spleen, and 6.9×10^8 /g of lymph node.

The other female armadillo, designated DH94, received 2.31×10^8 *M. leprae* intravenously in July 1981. AFB were found in peripheral blood smears in June 1982 and in nasal mucus in July 1982. In September 1982, the animal was sacrificed because of difficulty with feeding, weight loss, lethargy, and leg ulceration. The time between inoculation and sacrifice was 443 days (14.8 months).

Histopathologic studies of tissues obtained at autopsy in this animal showed AFB in the spleen (small amounts), peripheral nerves, lungs, lymph nodes, and liver but not in the heart, muscle, kidney, or uterus.

AFB from this animal were positive for

M. leprae by the pyridine test and did not grow on mycobacterial culture media. Mouse foot pad tests were not performed. The concentrations of AFB were 1.6×10^9 /g of liver, 8.6×10^7 /g of spleen, and 9×10^8 /g of lymph node.

The other male armadillo, designated DH146, received the same inoculum as DH43, namely, 1.61×10^8 bacilli, intravenously in October 1981. AFB were found in smears of peripheral blood and in ear clips in November 1982. In December 1982, ulcers appeared on the legs. In January 1983, the animal ceased feeding, became lethargic, and was sacrificed. The time from inoculation to sacrifice was 462 days (15.4 months).

Histopathologic studies of tissues obtained at autopsy showed AFB in the ear, liver, spleen, lymph nodes, lungs, striated muscle, and testicles, but not in the brain, esophagus, kidney or heart. In this animal, severe necrosis of striated muscle was seen. All lesions showed a histopathologic picture similar to that seen in lepromatous leprosy patients, but much more severe. The histiocytes were observed to have two mor-

phologic features, either vacuolated or "rough-glass" cytoplasm.

AFB from this animal were positive for *M. leprae* by the pyridine test and showed no growth on mycobacterial culture media. The mouse foot pad test was not performed. The concentrations of AFB were 8.75×10^8 /g of liver, 6.57×10^8 /g of spleen, and 1.2×10^9 /g of lymph node.

DISCUSSION

We believe that the AFB found in these four *D. hybridus* were *M. leprae* because they met the criteria for identification of *M. leprae* as suggested by WHO (¹⁶). Although the mouse foot pad technique was performed only with the material from the animal designated DH76, DH43 and DH146 received bacilli from the same inoculum as DH76. The pyridine test was positive for *M. leprae* with bacilli from all four of the animals, and tissues from each of the sacrificed animals showed typical histopathologic features of lepromatous leprosy.

The seven-banded armadillo has a number of advantages in comparison to the nine-banded armadillo. It easily adapts to life in captivity, although it appears to be very sensitive to any change in food composition and temperature. The seven-banded armadillo reproduces once a year, providing litters of 5–9 animals. The offspring are much easier to handle than animals obtained directly from the wild. The infection with *M. leprae* appears earlier in *D. hybridus* (14.6 months on the average) than in *D. novemcinctus* (24.1 months on the average) in our hands.

At this time, several other *D. hybridus*, most of them bred in captivity, are showing signs of disseminated leprosy.

SUMMARY

Four autochthonous seven-banded armadillos (*Dasypus hybridus*) from Argentina which developed disseminated leprosy are reported. The average time from inoculation to death was 14.6 months. Acid-fast bacilli (AFB) were found in the skin, nerves, spleen, lymph nodes, lungs, meninges, and striated muscle. Several tests were used to prove that the AFB found in the infected animals were *Mycobacterium leprae*: a) failure to grow in standard culture media for

mycobacteria, b) extraction of acid-fastness with the pyridine test, c) patterns of growth in the mouse foot pad, and d) histopathologic features.

RESUMEN

Se reportaron 4 casos de armadillos de 7 bandas (*Dasypus hybridus*) autóctonos de Argentina que desarrollaron lepra lepromatosa diseminada. El tiempo promedio desde la inoculación a su muerte fue de 14.6 meses. Se encontraron bacilos ácido resistentes en la piel, los nervios, el bazo, los ganglios linfáticos, los pulmones, las meninges, y el músculo estriado. Se hicieron varias pruebas para demostrar que los bacilos fueron *Mycobacterium leprae*: a) incapacidad de crecimiento en medios para micobacterias convencionales, b) extracción de la ácido resistencia con piridina, c) patrón de crecimiento en el cojinete plantar del ratón, y d) hallazgos histopatológicos.

RÉSUMÉ

On relate la dissémination de la lèpre chez 4 tatous autochtones à sept bandes (*Dasypus hybridus*) d'Argentine. La période moyenne entre l'inoculation et la mort a été de 14, 6 mois. On a récolté des bacilles acido-résistants dans la peau, les nerfs, la rate, les ganglions lymphatiques, les poumons, les méninges et les muscles striés. On a eu recours à plusieurs épreuves pour confirmer le fait que les bacilles acido-résistants récoltés chez les animaux infectés étaient bien *Mycobacterium leprae*. Les critères ont consisté en a) l'absence de croissance dans milieux de culture standards pour des mycobactéries, b) l'extraction de l'acido-résistance par l'épreuve à la pyridine, c) les profils de croissance dans le coussinet plantaire de la souris, et d) les caractéristiques histo-pathologiques.

Acknowledgments. This project was supported partially by the following institutions: SUBCYT (Science and Technology State Secretary), IMMSEP/World Bank/World Health Organization, and by the National Campaign against Leprosy (Interamerican Development Bank).

We are indebted to Dr. Christine Kien who did the microphotographs.

We thank the animal care keepers Carlos Sarciat and Juan Luis Diaz.

REFERENCES

- BALIÑA, L. M., VALDEZ, R. P., HERRERA, M. DE, COSTA CORDOVA, H., GARCIA, N. and SARCIAT, C. [Disseminated leprosy in *Dasypus hybridus* (seven-banded armadillos). Progress Report.] *Leprosy* 24 (1982) 103–116.
- CONVIT, J., ARANZAZU, N., PINARDI, M. E. and ULRICH, M. Immunological changes observed in indeterminate and lepromatous leprosy patients and Mitsuda-negative contacts after the inocula-

- tion of a mixture of *Mycobacterium leprae* and BCG. Clin. Exp. Immunol. **36** (1979) 214–220.
3. CONVIT, J. and PINARDI, M. E. *M. leprae*; differentiation from other mycobacteria through staining. Int. J. Lepr. **40** (1972) 130–134.
 4. CONVIT, J. and PINARDI, M. E. Inoculation del *M. leprae* en dos especies de armadillos: *D. sabanicola* y *D. novemcinctus*. Acta Cient. Venez. **25** (1974) 51–54.
 5. CONVIT, J., PINARDI, M. E. and ARANZAZU, N. *The Armadillo as an Experimental Model in Biomedical Research*. PAHO Scientific Publication No. 366. Washington, D.C.: Pan American Health Organization, 1978, pp. 41–46.
 6. CUBA, C. A. *Atlas de Histología del Armadillo de 7 Bandas (Dasypus hybridus)*. Buenos Aires: Centro Panamericano de Zoonosis OPS/OMS, 1979, p. 32.
 7. KIRCHHEIMER, W. F. and STORRS, E. Attempt to establish the armadillo (*Dasypus novemcinctus* Linn) as a model for the study of leprosy. Int. J. Lepr. **39** (1971) 693–702.
 8. MAGNIN, P. H. and HASSAN, M. Búsqueda del modelo experimental en animales para la enfermedad de Hansen. (Editorial) Temas Dermatología **2** (1974) 101.
 9. RIDLEY, D. and JOPLING, W. Classification of leprosy according to immunity. Int. J. Lepr. **34** (1966) 255–273.
 10. SHEPARD, C. C. The experimental disease that follows the injection of human leprosy bacilli into foot pads of mice. J. Exp. Med. **112** (1960) 445–454.
 11. SHEPARD, C. C. A kinetic method for the study of the activity of drugs against *Mycobacterium leprae* in mice. Int. J. Lepr. **35** (1967) 429–435.
 12. SHEPARD, C. C. and McRAE, D. H. A method for counting acid-fast bacteria. Int. J. Lepr. **36** (1968) 78–82.
 13. STORRS, E. E. The nine-banded armadillo. A model for leprosy and other biomedical research. Int. J. Lepr. **39** (1971) 703–709.
 14. STORRS, E. E. Leprosy in the nine-banded armadillo. Z. Tropenmed. Parasitol. **24** Suppl. (1973) 53–56.
 15. STORRS, E., KIRCHHEIMER, W. F. and BURCHFIELD, H. P. Development of leprosy in another species of armadillo, *Dasypus hybridus*. 1. Genetic and immunological implications. Am. J. Trop. Med. Hyg. **78** (1975) 216–218.
 16. WORLD HEALTH ORGANIZATION. *A Guide to Leprosy Control*. Geneva: World Health Organization, 1979.