

CORRESPONDENCE

This department is for the publication of informal communications that are of interest because they are informative and stimulating, and for the discussion of controversial matters. The mandate of this JOURNAL is to disseminate information relating to leprosy in particular and also other mycobacterial diseases. Dissident comment or interpretation on published research is of course valid, but personality attacks on individuals would seem unnecessary. Political comments, valid or not, also are unwelcome. They might result in interference with the distribution of the JOURNAL and thus interfere with its prime purpose.

Silastic Implant of the First Dorsal Interosseous Space

TO THE EDITOR:

In Oriental cultures particularly, a scaphoid depression of the first dorsal interosseous muscle contour in the hand is a generally recognized sign of leprosy. This cosmetic deformity marks affected individuals with a serious social stigma. As a result, those affected often seek cosmetic surgery. A folded dermal graft, obtained from the lateral aspect of the buttocks, has been used by some for this purpose. This requires surgery at two sites and, because variable resorption occurs, initial overcorrection is advocated. The final outcome is difficult to predict and reoperation may be necessary. Silicone injections provide no definitive shape and may result in foreign body granuloma formation.

We have recently used silastic implants (Dow Corning) previously developed solely as testicular prostheses to simulate the contour of the first dorsal interosseous muscle. We have implanted such prostheses in 9 individuals thus far, on an ambulatory basis, with uniformly excellent results (Figs. 1 and 2).

We have used child, youth, and small adult sizes of the testicular implants depending on intraoperative esthetic judgment of the optimal size and comparison with the normal side when possible. The prosthesis is placed through a small incision in the first web fold in a pocket adjacent to

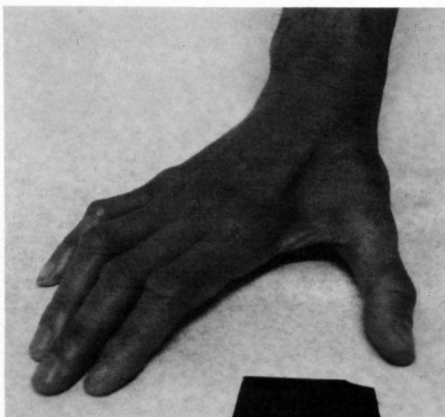


FIG. 1. Pre-operative hand.

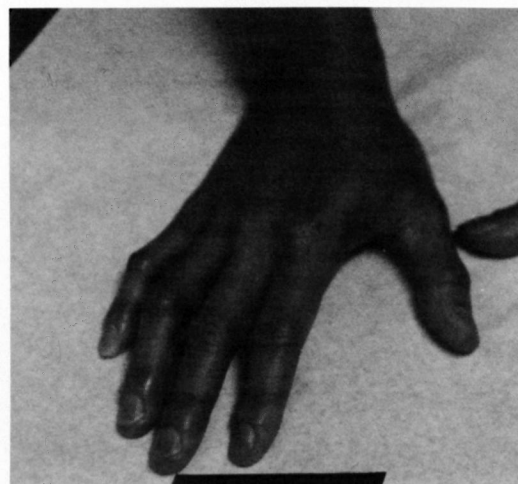


FIG. 2. Post-operative hand.

the second metacarpal. We recommend that others consider utilizing this procedure as a simple alternative for a socially difficult problem.

—Alan G. Zacharia, M.D.

*Orthopedic Surgeon
1500 Southgate Avenue
Suite 114
Daly City, California 94015
U.S.A.*

—Robert H. Gelber, M.D.

*Seton Medical Center
1900 Sullivan Avenue
Daly City, California 94015
U.S.A.*