

Periodic Acid-ethanol Gelatin Methenamine Silver Stain for Demonstrating *M. leprae* and Myelin in Peripheral Nerve Fibers of Leprosy Patients¹

Kiyoshi Harada and Keiji Suzuki²

Grocott (²) introduced a modification of Gomori's chromic acid-methenamine silver stain for demonstrating fungi in tissue sections and smears. Nyka (⁸) employed the Grocott-Gomori stain for demonstrating tubercle bacilli in tissue sections after sublimate fixation with added hydrogen peroxide or periodic acid. Sutter and Roulet (⁹) used the same method to demonstrate leprosy bacilli in sections or in smears of tissues fixed for a long time in Formalin. Harada (^{4,5}) introduced the periodic acid-methenamine silver method for demonstrating mycobacteria in tissue sections after Formalin fixation. This procedure can be used to demonstrate mycobacteria that have lost their acid-fastness by the usual carbol fuchsin stain. Silver impregnation methods are widely used for demonstrating nerve fibers and axons, but could not be used to demonstrate myelin. Recently, Dekura, *et al.* (¹) introduced the periodic acid-gelatin methenamine silver method for demonstrating myelin in peripheral and central nerve fibers in Formalin-fixed tissues.

In this paper, we have endeavored to demonstrate simultaneously *Mycobacterium leprae* and myelin in the peripheral nerves of the skin for studying the host-parasite relationship. After many trials, we recommend the following modification of the periodic acid-methenamine silver procedure.

¹ Received for publication on 22 March 1985; accepted for publication in revised form on 27 September 1985.

² K. Harada, M.D.; K. Suzuki, Technician, Laboratory, National Tamazensiyen Sanatorium, Higashimurayama, Tokyo 189, Japan.

MATERIALS AND METHODS

Skin lesions and sural nerves of human leprosy patients have been used as test materials. As controls, we used cerebellum tissue.

Tissues were fixed in 10% Formalin for 24–48 hr, dehydrated, embedded in paraffin, and cut into 5 μ m sections as usual.

Staining procedure.

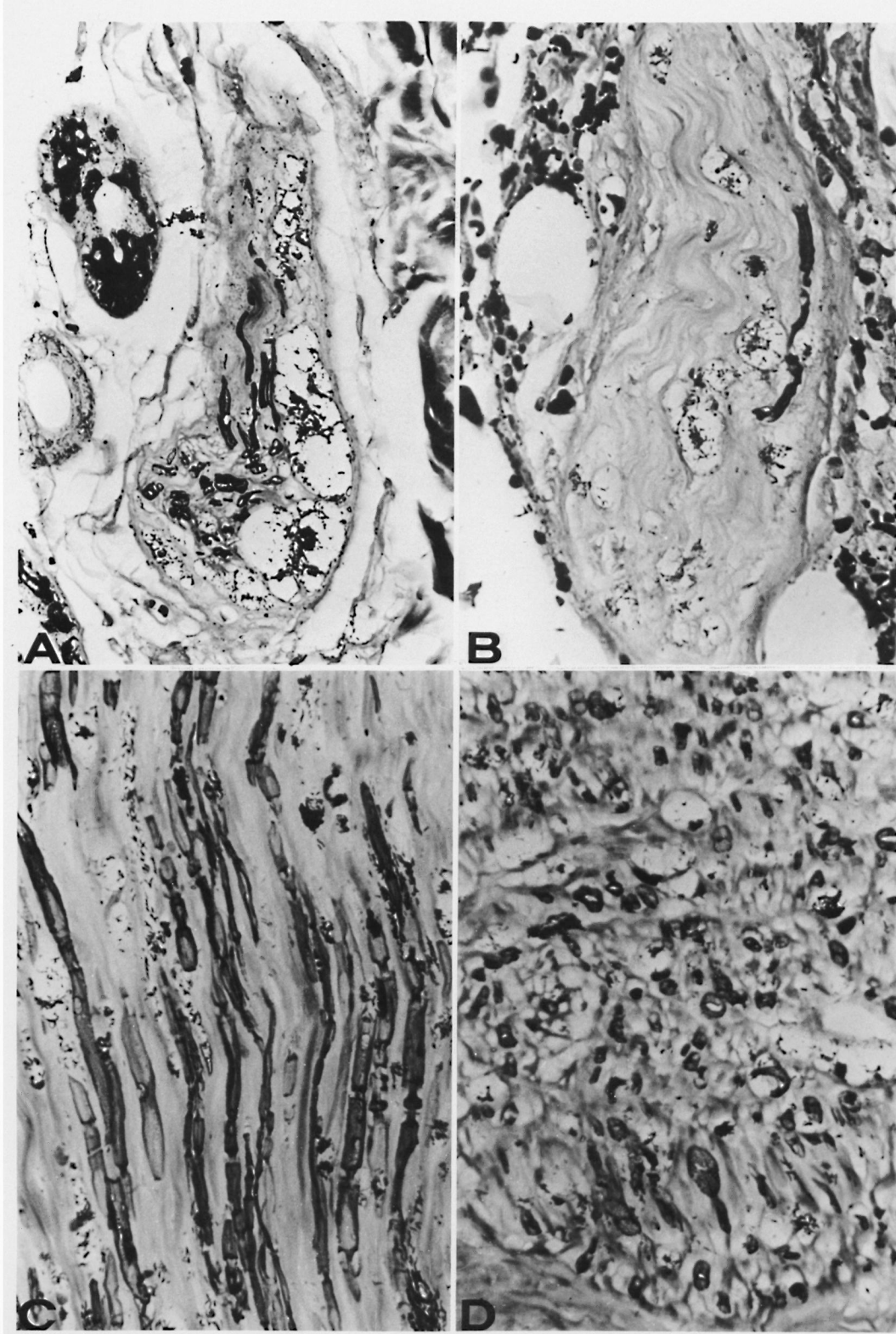
1. Deparaffinize sections in xylene and take to water through alcohols.
2. Oxidize overnight in 10% periodic acid in 80% ethanol.
3. Wash in running water and rinse in three changes of distilled water.
4. Place sections in freshly prepared gelatin methenamine silver solution in a Coplin jar and put in a 60°C oven for 2 hr until sections turn brown to black.

The gelatin methenamine silver solution was prepared as follows: Add 3.75 ml of 5% silver nitrate to 25 ml of 3% methenamine silver and then 20 ml of 2% hot gelatin and 2.5 ml of 5% borax. The gelatin (type 1, Bloom 300; Sigma) should be dissolved by heating in distilled water at 80°C just before use.

5. Rinse in two or three changes of distilled water warmed at 60°C and then successively in several changes of distilled water at close to room temperature.
6. Tone in 0.1% gold chloride for 5–10 min.
7. Rinse in distilled water.
8. Remove unreacted silver with 2% sodium thiosulfate for 2 min.
9. Wash in tap water, nuclear stain with nuclear fast red (nuclear fast red 0.1 g, 5%

FIG. 1. Periodic acid-ethanol gelatin methenamine silver stain for the simultaneous demonstration of *M. leprae* and myelin in peripheral nerves.

A and B. Small nerves in the dermis of lepromatous leprosy, showing hypertrophy of a nerve, a remnant of myelin in a nerve, fragmented bacilli, and globi ($\times 100$).



C. Sural nerve of lepromatous leprosy, longitudinal section, showing myelin, bacilli, and globi ($\times 100$).
D. Cross section of C. Partly deformed myelin, bacilli, and globi can be seen ($\times 100$).

THE TABLE. *Effects of prior extraction and oxidation on the gelatin methenamine silver stain for demonstrating M. leprae and myelin in skin lesions of leprosy.*^a

Prior treatment in step 2	<i>M. leprae</i>	Myelin	Reticulum	Collagen	Elastic fiber	Nucleus	Erythrocytes	Mucin	Melanin
None	-	+ to -	+	++	++	-	++	-	+
80% ethanol overnight	-	++ to -	-	+	++	-	++	-	+
10% periodic acid in 80% ethanol overnight	+++	+++	-	+	++	-	++	+	+
10% periodic acid overnight	++	+	-	++	++	-	+	++	+
1% periodic acid, 10 min	-	+	++	++	+	-	-	+	+
Contrast									
10% periodic acid overnight + methenamine silver (4,5)	+++	-	-	-	++	+	-	++	+

^a - to +++ = intensity of stain.

aluminum sulfate 100 ml) for 15 min, and counterstain with 0.01% methyl blue (art. 16316; Merck) in saturated picric acid aqueous solution for 5 min.

10. Dehydrate rapidly in absolute ethanol, clear in xylene, through terpineol-xylene (1:1), and mount in a resin (we used HSR).

RESULTS

M. leprae, myelin, erythrocytes, and elastic fibers stain black; collagen, partly black. Reticulum is unstained. Nuclei stain orange-red; melanin, sometimes black.

Figure 1 shows the nerve in the skin (A, B) and in the sural nerve of lepromatous leprosy (C, D). The effects of prior extraction and oxidation on the gelatin methenamine silver stain for staining *M. leprae* and myelin are shown in The Table.

In the cerebellum tissue, because of the absence of collagen, myelin could be demonstrated even without prior treatment. In the skin, because of the presence of connective tissue, the identification of myelin is more difficult.

With or without prior ethanol extraction, or after short periods of periodic-acid oxidation, positive reactions were given by myelin and connective tissues to varying lesser degrees, but negative reactions were given by *M. leprae*. After prolonged periodic-acid oxidation, *M. leprae* were intensely stained, but myelin and connective tissues were stained to a lesser degree. After prolonged periodic acid-ethanol oxidation, *M. leprae* and myelin were stained intensely,

but connective tissues stained to a lesser degree.

Too much impregnation will result in *M. leprae*, myelin, erythrocytes, and elastic fibers being blackened, collagen slightly blackened, and the reticulum will be unstained. Therefore, one should terminate treatment with the gelatin-methenamine silver solution when the erythrocytes begin to stain black.

DISCUSSION

The periodic acid-methenamine silver technique (3, 6) demonstrates the finer basement membranes and reticular fibers. If gelatin is added to the methenamine silver solution, myelin can be selectively demonstrated in the central neural system (1). Moreover, even without the aid of periodic-acid oxidation, myelin can be impregnated selectively (8).

The periodic acid-methenamine silver technique, if periodic-acid oxidation is prolonged, demonstrates the mycobacteria intensely and the connective tissues to a variable lesser degree (4, 5). The mechanism of the staining of mycobacteria depends upon the silver reaction with aldehydes produced from the 1-hydroxy-2-amino groups of mycobacterial cell walls by oxidation (5).

In our experiments, after prolonged treatment with periodic acid-ethanol, both myelin and mycobacteria could be impregnated with the gelatin-methenamine silver. Consequently, it is probable that the mechanism of the periodic acid-ethanol gelatin methenamine silver stain depends upon the

silver (aldehyde) reaction for demonstrating mycobacteria and the silver impregnation for myelin.

The pathogen-host relationship in the peripheral nerves and surrounding tissues in the skin can be demonstrated with this procedure.

SUMMARY

We have introduced the periodic acid-ethanol gelatin methenamine silver stain for the simultaneous demonstration of *Mycobacterium leprae* and myelin in the peripheral nerves of leprosy patients.

RESUMEN

Se presenta un método de tinción con ácido peryódico-etanol-gelatina-metamina y plata, para la demostración simultánea de *Mycobacterium leprae* y mielina en los nervios periféricos de los pacientes con lepra.

RÉSUMÉ

On a mis au point une coloration à base d'acide périodique et de méthénamine argentique avec alcool et gélatine, en vue de mettre en évidence simultanément dans les nerfs périphériques des malades de la lèpre *Mycobacterium leprae* et la myéline.

REFERENCES

1. DEKURA, Z., SUZUKI, K., KAWANAMI, K., KASUGA, H., GOTO, Y., YAMAMOTO, E. and OAMI, H. [New myelin staining method. I: The technic of periodic acid-gelatin methenamine silver stain.] *Pathol. Clin. Med.* **1** (1983) 349–353. (in Japanese)
2. GROCOTT, R. G. A stain for fungi in tissue sections and smears using Gomori methenamine silver nitrate technic. *Am. J. Pathol.* **25** (1955) 975–979.
3. GOMORI, G. A. New histochemical test for glycogen and mucin. *Am. J. Clin. Pathol.* **10** (1946) 177–179.
4. HARADA, K. Periodic acid-methenamine silver stain for mycobacteria in tissue sections. *Stain Technol.* **51** (1976) 278–280.
5. HARADA, K. An allochrome periodic acid-methenamine silver stain for demonstrating mycobacteria. *Jpn. J. Lepr.* **48** (1979) 171–175.
6. JONES, D. B. Inflammation and repair of the glomerulus. *Am. J. Pathol.* **27** (1951) 991–1009.
7. KATAOKA, M., ARAI, M., OIZUMI, Y., AKABANE, N., WAKAMATSU, K., MASUDA, K., SATO, J., ISHIZAKI, M., KAWANAMI, K., YAZIMA, G. and DEKURA, Z. [New myelin staining method. II: Gelatin methenamine silver stain, technic and mechanism.] *Pathol. Clin. Med.* **1** (1983) 504–513. (in Japanese)
8. NYKA, W. Studies on *Mycobacterium tuberculosis* in lesions of the human lung. A new method of staining tubercle bacilli in tissue sections. *Am. Rev. Respir. Dis.* **88** (1969) 670–679.
9. SUTTER, E. and ROULET, F. C. Staining *Mycobacterium leprae* in paraffin sections by Gomori methenamine silver method. *Stain Technol.* **40** (1965) 49–51.