

INTERNATIONAL JOURNAL OF LEPROSY

And Other Mycobacterial Diseases

VOLUME 54, NUMBER 2

JUNE 1986

Episodic Edema in Type 2 Lepra Reaction Can Be Caused by Transient Lymphatic Obstruction in the Lymph Node¹

John N. A. Stanley, John M. H. Pearson, and Dennis B. Ridley²

Edema is caused by the accumulation of excessive interstitial fluid. It is a neglected subject in leprosy; it has not, for instance, appeared in the subject index of the *INTERNATIONAL JOURNAL OF LEPROSY* for the past decade. Nevertheless, it is not uncommonly seen in patients with lepra reactions, both type 1 and type 2 (¹). Moreover, it can be damaging. Ulcers of edematous feet and legs are notoriously hard to heal, and the bizarre contractural deformities of the hands and feet seen in "burnt-out cases" indicate the damage that can be caused by fibrosis following chronic edema.

In a normal limb there is rapid turnover of the interstitial fluid, and the absence of edema is the result of balanced flows of fluid

in and out of the interstitial space. The factors controlling these movements (Starling's forces) are intracapillary pressure, tissue pressure, and colloid osmotic pressure. At the arterial (high pressure) end of the capillary bed, the balance favors movement out of the capillary; at the venous end, the lower intravascular pressure and the serum osmotic pressure cause interstitial fluid to enter the capillary. Any fluid tending to accumulate in the interstitial space travels via the lymphatic capillaries and regional lymph nodes to re-enter the circulation via the thoracic duct. The lymphatics are particularly concerned with transport of protein-containing interstitial fluid formed as the result of inflammatory or immune injury to blood vessels back into the general circulation.

The lymphatics of the normal limb appear adequate to carry large flows of protein-containing fluid. A patient with severe type 2 lepra reaction, for instance, may have extensive skin lesions; inflammatory exudate will enter the interstitial space as a result of increased capillary permeability due to the immune response that follows the formation of immune complexes at the site. Nevertheless, it is unusual to see anything more than trivial edema of the hands and feet in such cases. On the other hand, edema

¹ Received for publication on 13 August 1985; accepted for publication in revised form on 17 January 1986.

² J. N. A. Stanley, M.B.B.S., Research Officer, Dhoolpet Leprosy Research Centre, Hyderabad 500006, India (present address: Department of Postgraduate Medicine, North Staffordshire Medical Institute, Stoke on Trent, England). J. M. H. Pearson, D.M., F.R.C.P., Physician, Dhoolpet Leprosy Research Centre, Hyderabad 500006, India. D. S. Ridley, M.D., F.R.C.Path., Consultant Pathologist, Hospital for Tropical Diseases, London NW1 0PE, England (present address: The Bland-Sutton Institute of Pathology, Middlesex Hospital Medical School, London W1P 7PN, England).

Reprint requests to Dr. Pearson.

in type 2 lepra reaction can also occur in the absence of severe skin manifestations.

This paper presents evidence that attacks of edema in type 2 lepra reaction can be caused by transient lymphatic obstruction at the level of the regional lymph nodes.

PATIENTS AND METHODS

The patients included in this study were all receiving outpatient treatment for lepromatous leprosy with type 2 lepra reaction (erythema nodosum leprosum, ENL) at Dhoolpet Leprosy Research Centre in Hyderabad, India. They were entered into the study at the time they were observed to have developed edema of the hands and/or feet. At this time almost all showed active ENL lesions of the skin.

On entry a detailed history was taken, particularly of any previous episodes of edema and their association with reaction and enlarged or tender lymph nodes. The patients were examined with particular reference to the possible presence of such lymph nodes. Skin smears were taken if they had not been done in the previous year.

Enlarged supratrochlear lymph nodes were excised from five patients, four of whom had swollen hands at the time. The fifth had swollen feet and developed edema of the hands with lymphadenopathy in another attack soon after the biopsy. In four more patients, biopsies were taken from edematous skin areas in such a way as to include an underlying subcutaneous vein. No patient was receiving corticosteroids at the time of biopsy. Biopsies were fixed in formaldehyde (40%, 10% v/v), mercuric chloride (2% w/v), and glacial acetic acid (3% v/v) (FMA), and processed for routine histology.

When investigations were completed, the patients were, in most cases, treated with a short course (2–3 weeks) of prednisolone⁽²⁾; the edema usually resolved in a week or less, although attacks often recurred for some months and the patients needed further courses of steroids. None of the patients, however, developed chronic edema during a follow-up period of 6–12 months.

RESULTS

Fourteen patients were included in the study, classified clinically as LL (13) and BL

(1); there was biopsy confirmation in ten cases. They were aged 14–70 years (average age = 34) and had been treated for 1–10 years (average = 4). The bacterial index (BI) at the time of study ranged from 0 to 4.3+ (average = 3.3+). All of the patients were receiving repeated short courses of prednisolone for type 2 reaction, and five were also receiving clofazimine.

The edema was mild in all but one case, and it was nearly always bilateral and symmetrical. ENL lesions were present in almost all of the cases at the time of examination, and were seen on edematous limbs in most cases. However, they were not often severe or extensive. The regional lymph nodes (inguinal for feet, axillary for hands) were enlarged and often tender, even in those patients without ENL lesions on the edematous limbs. The supratrochlear nodes were often enlarged and tender. In three episodes of edema, the state of the lymph nodes was not recorded.

From questioning and follow up, it became clear that lymph nodes could be enlarged and tender in the absence of edema. Indeed, most of the patients in this series developed episodes of lymphadenopathy without edema (24 such episodes were recorded in 52 episodes of lymphadenopathy).

The four biopsies of edematous skin were taken from sites overlying subcutaneous veins, and ENL lesions were avoided. The biopsies showed, in three instances, the features of regressing LL leprosy with no sign of reaction; the fourth was reported as old healed leprosy. All biopsies showed marked dilatation of the lymphatic channels in the upper dermis. Of the four veins, one looked normal apart from the presence of acid-fast bacilli (AFB) in the smooth muscle layer. The other three were edematous, with AFB in the muscle and, in two cases, also in the endothelium. One of the veins was also infiltrated with neutrophils, suggesting the possibility of ENL in the vein wall.

Five lymph nodes were biopsied. They were much enlarged, being usually about five times the normal diameter. Histologically, all of the nodes showed capsular thickening, which was severe in 4 of the 5 biopsy cases. Sometimes the fibrosis extended into the node itself and destroyed the normal

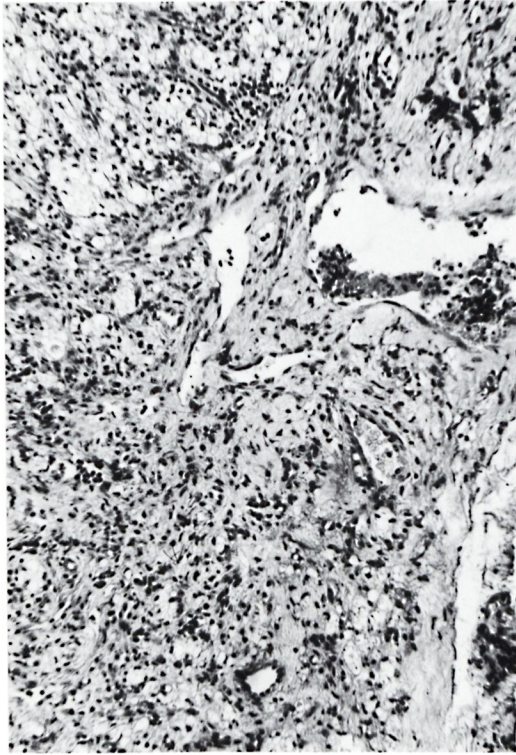


FIG. 1. Thickened fibrosed capsule of lymph node and destruction of the subcapsular sinus by foamy macrophages, cellular infiltration and, probably, previous reaction (H&E $\times 150$).

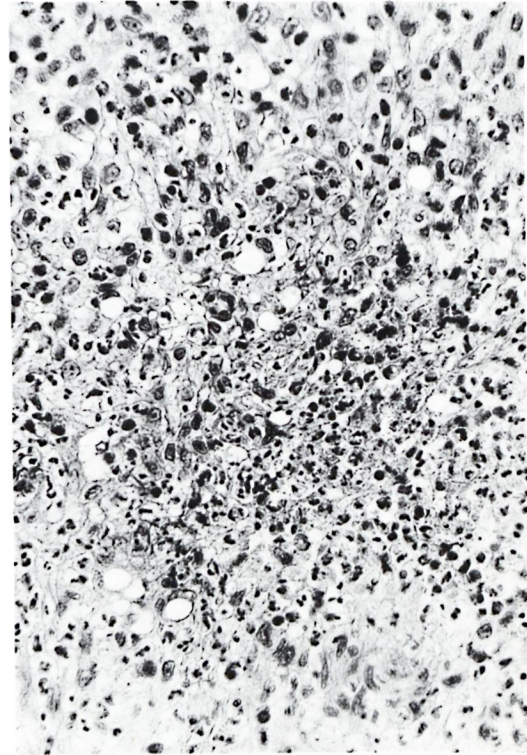


FIG. 2. Characteristic ENL, part of an extensive area of reaction in the cortex (H&E $\times 400$).

demarcation of capsule and node (Fig. 1). In one case the capsule showed a hyaline appearance. The capsular sinuses, by contrast, were narrow and in part obliterated. In one case, a dilated afferent lymphatic channel was seen just outside the capsule.

The nodes themselves had the appearance of lepromatous leprosy, with accumulations of foamy macrophages in the subcapsular sinuses, the paracortical areas, and the medulla. One biopsy showed a focus of classical ENL in the cortex (Fig. 2). One other node showed an area of severe edema and exudate near the subcapsular sinus, and an increase of mast cells in this region (Fig. 3). These changes were reactional but not quite typical of ENL. Two other cases showed some increase of mast cells in the subcapsular area. The patient who did not develop edema of the hands until after the taking of the biopsy showed no reactional changes in the lymph node.

DISCUSSION

Enlarged supratrochlear lymph nodes are commonly present in active lepromatous leprosy. They are not tender, and shrink during treatment so they are seldom found when skin smears become negative.

The supratrochlear and other nodes of the patients in this study were enlarged, and they underwent episodes of pain, tenderness, and further increase in size. A specific localized ENL lesion was observed in one case, and reactional edema in another. However, the constant finding was marked fibrosis and thickening of the capsule, brought about by chronic inflammation in the nodes (as is also the case in other chronic infective conditions). The subcapsular sinuses tended to be compressed against the fibrous capsule by the increased mass of the node which was brought about by the infiltration of foamy macrophages together with some degree of nonspecific reactive change and enhanced by episodes of acute reaction. Lymphatics are low pressure channels, and

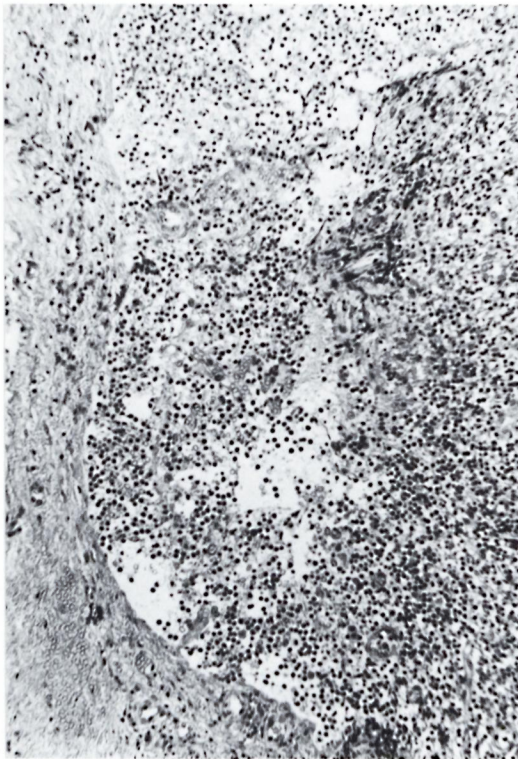


FIG. 3. A reaction in the subcapsular region of a lymph node, characterized by edema, exudate and (not visible in the figure) mast cells. Not so typical of ENL. Note the thickened capsule (H&E $\times 150$).

it would only require a small increase in intranodal pressure to obstruct the flow in the subcapsular sinus. An increase in lymph flow to the node due to ENL in the limb would further increase the likelihood of edema developing.

The nature of the intranodal inflammatory process is not exactly clear. Localized ENL was demonstrated in one case, and could have been present in unsectioned parts of this or other nodes. However, the acute edema, extravasation of red cells, and increase in mast cells in one case were suggestive in some respects of exacerbation reaction (⁴). They were not exacerbation reactions because the AFB were scanty and not solid staining, but possibly the ENL is modified somewhat by the periodic arrival in the node of large amounts of antigen draining from ENL lesions in the limb.

There was good correlation between edema and lymphadenopathy. In every case where the state of the lymph nodes was re-

corded, they were enlarged when edema was present. However, almost half the attacks of lymphadenopathy were not accompanied by edema. This is to be expected, since it is hardly possible that all of the regional nodes could be equally severely affected in every attack. Moreover, the flow of lymph is likely to vary according to the extent of ENL lesions in the limbs.

This study gives no information on the cause of the chronic edema that can develop during or after a type 2 lepra reaction, although one can speculate that extensive postinflammatory fibrosis in the regional lymph nodes could cause persistent edema. However, this study clearly indicates that when patients with type 2 lepra reaction develop lymphadenopathy, the reaction increases the bulk of the nodes. Thus, internal expansion compresses the subcapsular sinus against the unyielding fibrotic capsule of the node, obstructs the flow of lymph into and through the node, and so can and often does cause peripheral edema.

SUMMARY

Fourteen patients with lepromatous leprosy developed attacks of edema of the hands and/or feet associated with attacks of type 2 lepra reaction (erythema nodosum leprosum). The regional lymph nodes were enlarged and often tender when edema was present. Lymph node biopsies in five cases showed compression of the subcapsular sinus against the thickened fibrotic capsule of the inflamed node. It is suggested that this obstructs the inflow of lymph into the regional nodes, thereby causing the edema.

RESUMEN

Catorce pacientes con lepra lepromatosa desarrollaron ataques de edema en los pies y/o manos, asociados con cuadros reaccionales del tipo 2 (eritema nodoso leproso). Cuando hubo edema, los ganglios linfáticos regionales estuvieron agrandados y a menudo reblandecidos. Las biopsias de los ganglios linfáticos de 5 pacientes mostraron compresión del seno subcapsular contra la cápsula fibrótica engrosada de los ganglios inflamados. Se sugiere que ésto obstruye el influjo de linfa a los ganglios linfáticos regionales originando el edema.

RÉSUMÉ

Quatorze malades atteints de lèpre lépromateuse ont développé des épisodes d'oedème aux mains, aux pieds,

aux quatre extrémités, lors d'attaque de réaction lépreuse de type 2 (érythème noueux lépreux). Les ganglions lymphatiques régionaux étaient augmentés de volume, et souvent plus sensibles au toucher lorsqu'il y avait de l'oedème. Les biopsies de ganglions lymphatiques prélevés chez cinq malades ont montré que le sinus sous-capsulaire était comprimé contre la capsule fibreuse épaissie du ganglion enflammé. On suggère que ce mécanisme entraîne une obstruction de la circulation de la lymphe dans les ganglions régionaux, ce qui dès lors produit l'oedème.

Acknowledgments. We thank Dr. Marian Ridley for helpful comments. Dhoolpet Leprosy Research Centre is administered by Victoria Hospital Dichpalli in collaboration with the Medical Research Council (of Great

Britain), and is also supported by the British Leprosy Relief Association (LEPRA).

REFERENCES

1. JOPLING, W. H. Reactions in leprosy. (Letter) *Lepr. Rev.* **41** (1970) 62.
2. PEARSON, J. M. H. The use of corticosteroids in leprosy. *Lepr. Rev.* **52** (1981) 293-297.
3. RIDLEY, D. S. and JOPLING, W. H. Classification of leprosy according to immunity. A five-group system. *Int. J. Lepr.* **34** (1966) 255-273.
4. RIDLEY, D. S. and RIDLEY, M. J. Exacerbation reactions in hyperactive lepromatous leprosy. *Int. J. Lepr.* **52** (1984) 384-394.