

Prophylactic/Therapeutic Effects and Induction of Reversal Reactions with Thymus Transplantation in *Mycobacterium leprae*-infected Nude Mice¹

Kenji Kohsaka, Yasuyo Miyata, Tatsuo Mori, and Tonetaro Ito²

Ever since the establishment of the nude mouse as a model for the study of experimental leprosy (^{2, 4, 5}), there has been a great deal of interest in utilizing these animals for further investigations in the field of leprosy research, particularly in the areas of chemotherapy and immunology. In the present paper, we have studied the effects of thymus transplantation into *Mycobacterium leprae*-infected nude mice and the effects of thymus transplantation on the growth of *M. leprae* in these animals.

MATERIALS AND METHODS

M. leprae. The bacilli were originally obtained from a biopsy of a subcutaneous leproma from a previously untreated lepromatous leprosy patient. They had been passaged six times in nude mice previously and the seventh passage of the bacilli, designated as the Kurume-naha strain, was used as the inoculum. The inoculum was prepared by mincing the infected nude mouse foot pad tissue into fine pieces with scissors, then grinding in a porcelain mortar and pestle, suspending in HAM-F12 tissue culture medium (Nissui Seiyaku, Tokyo, Japan), and centrifuging at $200 \times g$ for 5 min to remove coarse tissue debris. The supernatant was mixed with an equal volume of 1 N NaOH and allowed to stand for 5 min at room temperature. The mixture was then diluted with four volumes of distilled water and centrifuged at $8000 \times g$ for 20 min. The supernatant was discarded and the bacterial pellet washed twice by resuspending in distilled water and recentrifuging at

$8000 \times g$ for 20 min. After washing, the final pellet was resuspended in HAM-F12 medium and diluted to the desired concentration.

Nude mice. Five-week-old BALB/c-*nu/nu* female mice were used. The animals were obtained from CLEA Japan, Inc., and were maintained in a plastic vinyl isolator during the experiment as previously described (⁵).

Thymuses were obtained from newborn female heterozygous mice (BALB/c-*nu/+*) which were locally bred in our laboratory. The newborn animals were sacrificed and the thymus aseptically removed. The thymus tissue was washed in HAM-F12 medium and a freshly prepared whole thymus was injected into one *M. leprae*-infected nude mouse, either intraperitoneally or subcutaneously in the back, using a sterile trocar (inner diameter = 2 mm).

A total of 32 nude mice were infected in both hind foot pads with *M. leprae*. Each foot pad was inoculated with 2.5×10^7 bacilli in a volume of 50 μ l. Fifteen of these animals received 12 monthly injections of thymus tissue (thymus transplantation) as above, beginning 8 days after infection with *M. leprae*. In 10 the thymus injections were administered subcutaneously in the back, and in 5 the injections were given intraperitoneally. The remaining 17 mice served initially as untreated controls in this prophylactic experiment.

Beginning 7.5 months after infection of the mice with *M. leprae*, the remaining 16 untreated animals serving as controls in the prophylactic experiment were used to conduct a therapeutic experiment to determine the effects of thymus transplantation on an established infection. At this time the bacterial load was approximately 1.5×10^9 per foot pad. The 16 animals were divided into two equal groups. The treated group received monthly thymus injections intraperitoneally, as above, for a total of 7

¹ Received for publication on 12 July 1985; accepted for publication in revised form on 19 November 1985.

² K. Kohsaka, Ph.D., Assistant Professor; Y. Miyata, M.Sc., Research Student; T. Mori, M.D., Ph.D., Associate Professor; T. Ito, M.D., Ph.D., Professor, Department of Leprology, Research Institute for Microbial Diseases, Osaka University, 3-1 Yamada-oka, Suita, Osaka, Japan.

TABLE 1. Effect of thymus transplantation on growth of *M. leprae*^a in the nude mouse^b—prophylactic experiment.

Mouse group	Inoculum	Months after inoculation				
		7.5	10	13	15	18.5
Control (N17)	2.5 × 10 ⁷	1.5 × 10 ⁹		7.4 × 10 ⁹	2.9 × 10 ¹⁰	4.0 × 10 ¹⁰
				5.9 × 10 ⁹	2.3 × 10 ¹⁰	3.6 × 10 ¹⁰
				5.2 × 10 ⁹	(6.2 × 10 ⁹) ^c	(2.6 × 10 ¹⁰)
Thymus (s.c.) ^d (N10)	2.5 × 10 ⁷	1.7 × 10 ⁸	3.1 × 10 ⁷	4.3 × 10 ⁷	1.0 × 10 ⁸	1.9 × 10 ⁷
			2.1 × 10 ⁷	3.1 × 10 ⁷	9.2 × 10 ⁷	1.1 × 10 ⁷
			(2.6 × 10 ⁷)	(3.7 × 10 ⁷)	(9.6 × 10 ⁷)	(1.0 × 10 ⁷)
Thymus (i.p.) ^e (N5)	2.5 × 10 ⁷			4.5 × 10 ⁷	3.8 × 10 ⁷	1.5 × 10 ⁷
					2.2 × 10 ⁷	1.2 × 10 ⁷
					(3.0 × 10 ⁷)	(1.4 × 10 ⁷)

^a *M. leprae* = 7th passage in nude mice.

^b Nude mouse = BALB/c-*nu/nu*, female, 5 weeks old.

^c Figures in parentheses = average for number of mice sacrificed.

^d s.c. = subcutaneously.

^e i.p. = intraperitoneally.

months. The remaining 8 mice served as untreated controls for both the prophylactic and therapeutic experiments.

One to three mice were sacrificed at 7.5, 10, 13, 15, and 18.5 months after infection with *M. leprae* from the groups receiving thymus transplantations prophylactically, from the group receiving thymus transplantation therapeutically, and from the untreated control group. At sacrifice, the hind foot pads were removed. The right hind foot pad was processed for bacterial enumerations as described (4), and the left hind foot pad was placed in 20% neutral Formalin for fixation.

Decalcification with EDTA-4Na was done (Sasaki and Kawatsu, personal communication) and the sections stained with hematoxylin-eosin (H&E) and the Fite-Faraco stain.

RESULTS

The results of the bacterial enumerations are shown in Tables 1 and 2. Thymus transplantation prevented the multiplication of *M. leprae* when administered prophylactically to nude mice shortly after infection (Table 1) and exerted a therapeutic effect in animals with established infections (Table

TABLE 2. Effect of thymus transplantation on growth of *M. leprae*^a in the nude mouse^b—therapeutic experiment.

Mouse group	Months of treatment (months after treatment)			
	0 (7.5)	5 (13)	7 (15)	10.5 (18.5)
Control (N8)		7.4 × 10 ⁹	2.9 × 10 ¹⁰	4.0 × 10 ¹⁰
		5.9 × 10 ⁹	2.3 × 10 ¹⁰	3.6 × 10 ¹⁰
		5.2 × 10 ⁹	(6.2 × 10 ⁹) ^c	(2.6 × 10 ¹⁰)
Thymus (i.p.) ^d (N8)	1.5 × 10 ⁹	1.3 × 10 ⁹	8.3 × 10 ⁸	6.7 × 10 ⁸
		1.1 × 10 ⁹	2.7 × 10 ⁸	4.1 × 10 ⁸
		9.0 × 10 ⁸	(5.5 × 10 ⁸)	2.6 × 10 ⁸
		(1.1 × 10 ⁹)	(5.5 × 10 ⁸)	(4.5 × 10 ⁸)

^a *M. leprae* = 7th passage in nude mice.

^b Nude mouse = BALB/c-*nu/nu*, female, 5 weeks old.

^c Figures in parentheses = average for number of mice sacrificed.

^d i.p. = intraperitoneally.

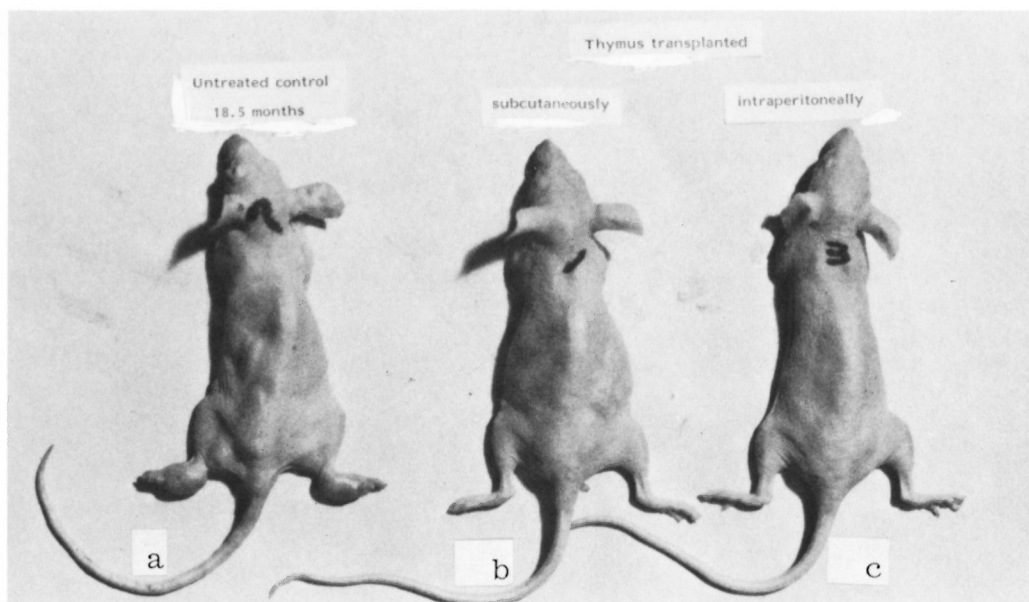


FIG. 1. Prophylactic experiment (at 18.5 months after inoculation). a) = untreated control mouse (swelling of both hind foot pads); b) = thymus-transplanted mouse (subcutaneously, monthly 12 times over 1 year); c) = thymus-transplanted mouse (intraperitoneally, monthly 12 times over 1 year).

2). In both the prophylactic (Fig. 1) and the therapeutic experiments (not shown), thymus transplantation prevented the prominent foot pad enlargement which is characteristic of the late stages of the untreated foot pad infection with *M. leprae* in nude mice.

Histopathologically, the foot pads of the untreated control nude mice showed typical lepromas at 15 and 18.5 months after inoculation with *M. leprae*. Abundant foamy macrophages containing numerous acid-fast bacilli were seen in sections with H&E and Fite-Faraco staining. In contrast, the foot pads of animals which had received thymus transplantation therapeutically showed remarkable round cell infiltrations at 15 and 18.5 months after infection (after 7 and 10.5 months of immunotherapy) (Fig. 2). In some areas there was epithelioid cell formation with lymphocytes surrounding the epithelioid cells. The number of bacilli were reduced, and only a few were seen in some areas. Thus, the histopathological findings revealed the development of reversal reactions in *M. leprae*-infected nude mice receiving thymus transplantation as immunotherapy.

A striking swelling developed in the infected foot pads of the mice receiving thymus transplantations after each injection, beginning with the second transplantation. This occurred in both the animals receiving the transplantations prophylactically and in those receiving transplantations as immunotherapy of established infections. The swelling was noted within a few days after each transplantation, continued for several weeks, and then subsided somewhat before the next transplantation. This swelling was found repeatedly during the course of the experiments but was not associated with an enhancement of the growth of *M. leprae* in the foot pads.

DISCUSSION

Reversal reactions have been induced in *M. leprae*-infected, thymectomized irradiated mice with syngeneic leukocyte infusions by Rees, *et al.* (7) and with isogenic thymus transplantation beneath the kidney capsule by Gaugas, *et al.* (3). Chehl, *et al.* (1) reported successfully inducing reversal reactions in *M. leprae*-infected nude mice by infusing allogeneic splenic leukocytes.

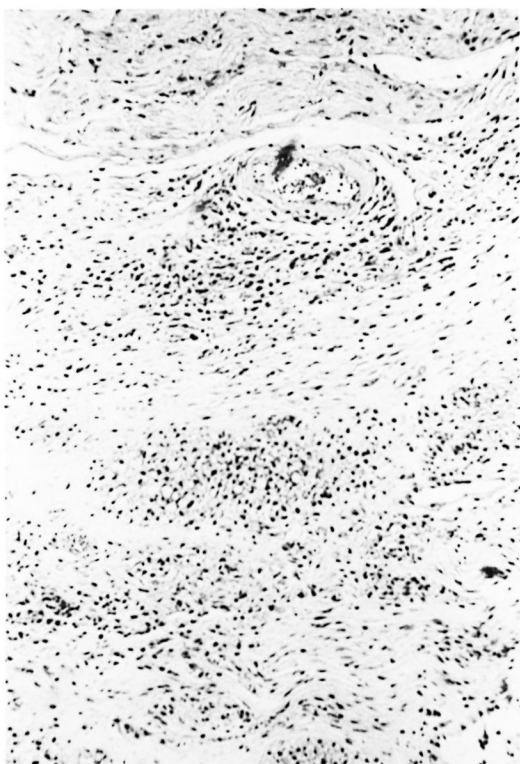


FIG. 2. Therapeutic experiment (at 15 months after inoculation). Histopathological section of foot pad of thymus-transplanted mouse (H&E $\times 100$).

We have now studied the effects of thymus transplantation, subcutaneously or intraperitoneally, on the growth of *M. leprae* in nude mice. When administered prophylactically shortly after infection, thymus transplantation prevents the multiplication of the bacilli. When given as immunotherapy to nude mice with established infections, reversal reactions are induced and the growth of the bacilli is inhibited.

According to Nakamura and Yogi (⁶), nude mice receiving thymus cell grafts showed enhanced growth of *M. leprae* and developed severe lepromatous lesions. In our experiments there seem to be two types of foot pad swelling. There is a progressive foot pad enlargement associated with bacterial growth in the untreated animals on the one hand and, on the other, a more striking swelling occurring shortly after each thymus transplantation which is associated with an inhibition of bacterial multiplication in the treated mice. The latter type of swelling

seems likely to be caused by an interaction between the thymus transplant and the bacteria-loaded foot pad tissues rather than being due to bacterial growth.

SUMMARY

The study results indicated that thymus transplantation was effective in suppressing the growth of *Mycobacterium leprae* in the nude mouse, and also suggested that thymus transplantation was effective as immunotherapy of experimental leprosy in nude mice. The histopathological findings revealed the induction of reversal reactions in those animals receiving thymus transplants.

RESUMEN

Los resultados de este estudio indicaron que el trasplante de timo en el ratón desnudo fue efectivo tanto en la supresión del crecimiento del *Mycobacterium leprae* como en la inmunoterapia de la lepra experimental en este modelo animal. Los hallazgos histopatológicos revelaron el desarrollo de "reacciones reversas" en los animales que recibieron los trasplantes de timo.

RÉSUMÉ

Les résultats publiés ici montrent que la transplantation du thymus est efficace pour supprimer la croissance de *Mycobacterium leprae* chez la souris glabre. Ils suggèrent également que la transplantation thymique est efficace comme immuno-thérapie de la lèpre expérimentale chez cette même souris. Les observations histopathologiques ont montré qu'il se produisait des réactions reverses chez les animaux ayant reçus des transplants de thymus.

Acknowledgments. This study was supported by a grant-in-aid for scientific research, Japanese Ministry of Education, Science and Culture; the Japanese Leprosy Panel of the U.S.-Japan Cooperative Medical Science Program; the Yamada Science Foundation; and the Osaka Dermatological Institute, for which grateful acknowledgments are made. We thank Miss Fumie Kakuda for her technical help.

REFERENCES

- CHEHL, S. K., SHANNON, E. J., JOB, C. K. and HASTINGS, R. C. Reversal reactions in *Mycobacterium leprae*-infected nude mice. Abstract in Int. J. Lepr. 51 (1985) 645.
- COLSTON, M. J. and HILSON, G. R. F. Growth of *Mycobacterium leprae* and *M. marinum* in congenitally athymic (nude) mice. Nature 262 (1976) 399-400.
- GAUGAS, J. M., REES, R. J. W., WEDDELL, A. G. M.

- and PALMER, E. Reversal effect of thymus grafts on lepromatous leprosy in thymectomized-irradiated mice. *Int. J. Lepr.* **39** (1971) 388–395.
4. KOHSAKA, K., MAKINO, M., MORI, T. and ITO, T. Establishment of experimental leprosy in nude mice. *Jpn. J. Bacteriol.* **33** (1978) 389–394.
5. KOHSAKA, K., MORI, T. and ITO, T. Lepromatoid lesion developed in nude mouse inoculated with *Mycobacterium leprae*—animal transmission of leprosy. *Lepro* **45** (1976) 177–187.
6. NAKAMURA, K. and YOGI, Y. The nude mouse as an experimental lepromatous leprosy model; the enhancing effect of thymus cells in infected nude mice. Abstract in *Int. J. Lepr.* **47** (1979) 105.
7. REES, R. J. W. and WEDDELL, A. G. M. Experimental models for studying leprosy. *Ann. N.Y. Acad. Sci.* **154** (1968) 214–236.