

Unusual Histological Lesions in the Eye of a Leprosy Patient¹

Zhou Hui-Min, Shi Zhen-Rong, and Charles K. Job²

Descriptions of the histopathology of eye lesions in leprosy, both in humans and in experimental animals, have rarely appeared in the literature. The lesions reported were almost all lepromatous infiltrations, predominantly in the anterior segment of the eyeball. We had a case of eye involvement in a leprosy patient. In this eye a granulomatous reaction composed of epithelioid cells, lymphocytes and giant cells, infiltrating mainly the anterior segment of the eyeball and also the retina was seen. We report on the unusual features of the reactions in this eyeball of a leprosy patient.

MATERIALS AND METHODS

The eyeball of this male patient, 42 years of age, was submitted to us from a leprosy control unit in Shandong Province, People's Republic of China, in the mid-1960s with only a too brief clinical diagnosis of lepromatous leprosy and a one-sentence description of the patient's ailment: 10 years of pain in the eye and blindness. This was all the information we could obtain.

The eyeball was fixed in Formalin and subsequently dehydrated in graded alcohol and embedded in celloidin, as is our routine. Ten of the serial sections cut, 20 μ m thick each, were stained with hematoxylin and eosin (H&E), and the others have been preserved. In 1986, two old preserved celloidin sections were stained for acid-fast bacilli (AFB) with a modified Fite method.

RESULTS

Histopathology of the eyeball

Conjunctiva. There was only a small strip of conjunctiva attached, and no remarkable change was found.

Cornea. The thickness of the epithelial layer of the cornea was not even, and there was atrophy of Bowman's layer. Neovascularization, distortion of lamellae, and inflammatory cell infiltrations were seen throughout the stroma of the cornea, but most prominently in the superficial stratum.

Sclera. The anterior and superficial part of the sclera was similarly infiltrated as the cornea, but milder. In the area adjacent to the ciliary body, there were abundant lymphocytes, macrophages, and neutrophils. Along the course of the nerves traversing the sclera, granulomas composed of mac-

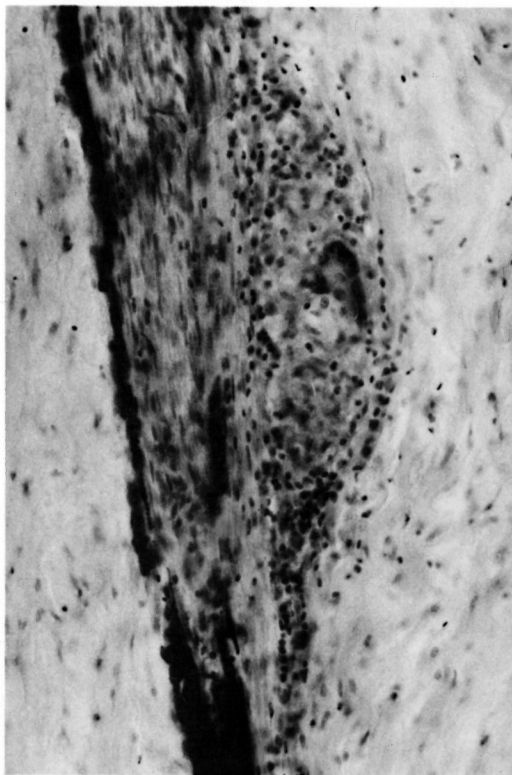


FIG. 1. Posterior part of the sclera, immediately adjacent to the nerve traversing it, showing a granuloma composed of macrophages, epithelioid cells, lymphocytes, giant cells, and some neutrophils. Melanin deposition approximately marks the boundaries of the nerve (H&E \times 180).

¹ Received for publication on 17 October 1986; accepted for publication in revised form on 8 April 1987.

² Dr. H.-M. Zhou, Professor of Pathology; Dr. Z.-R. Shi, Professor of Ophthalmology and Ocular Pathology, Qingdao Medical College, Qindao, People's Republic of China. C. K. Job, M.D., F.R.C.Path., F.A.M.S., Chief, Pathology Research Department, GWL Hansen's Disease Center, Carville, Louisiana 70721, U.S.A.

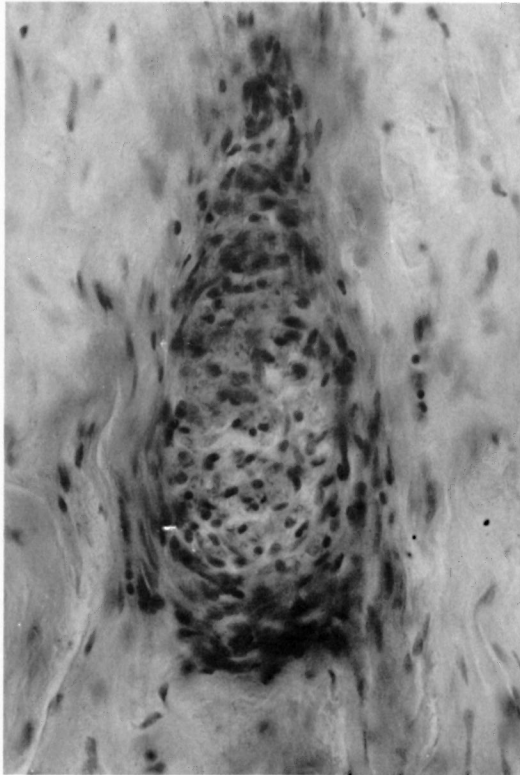


FIG. 2. Section of a nerve in the sclera posterior to the one in Figure 1 and near the optic nerve, showing perineural thickening (H&E $\times 300$).

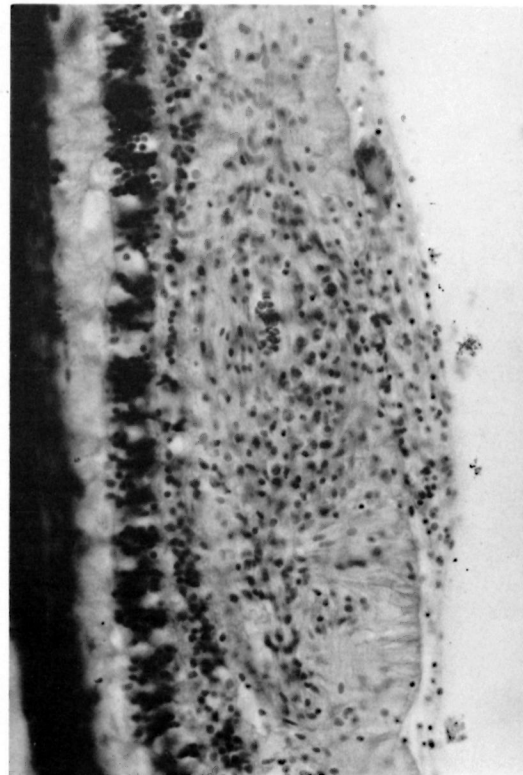


FIG. 3. A small collection of macrophages, epithelioid cells, and lymphocytes in the retina. One giant cell and some macrophages and lymphocytes are seen in the vitreous attaching the retina (H&E $\times 180$).

rophages, epithelioid cells, lymphocytes, and Langhans' giant cells, with some neutrophils, were seen (Fig. 1). Some nerves showed perineural thickening (Fig. 2).

Uvea. Granulomas, with composition similar to those in the sclera, were seen in the ciliary body, iris, and anterior portion of the suprachoroid, but not in the bulk of the choroid. The ciliary body and iris, besides the granulomas, were also densely infiltrated by macrophages, plasma cells, and some neutrophils. There was a diffuse peripheral anterior synechia of the iris with a breakdown of the pigment epithelium, and the posterior surface of the iris was adhered to the lens capsule by a fibrovascular membrane. The pigment epithelium of the ciliary body was disrupted locally.

Retina. Besides other alterations, several small granulomas were seen in the retina (Fig. 3) and in the vitreous attached to the inner surface of the retina, in one of which a Langhans' giant cell was seen. Other al-

terations included edema, flat detachment, disappearance of the ganglia cells, local destruction of the pigment epithelium, and chronic inflammatory cell infiltrations around the blood vessels.

Optic nerve. The optic nerve was atrophic with some lymphocyte infiltrations locally.

Lens. There was a cataract change.

Anterior chamber. The chamber angle was completely obliterated, and the chamber was filled with serous exudate.

Vitreous body. In the vitreous, some lymphocytes, macrophages, and neutrophils were seen. Local fibrosis of the exudate near the ciliary body and some collections of macrophages and epithelioid cells were also observed.

There was no evidence of caseous necrosis in any of the lesions.

Acid-fast staining of the old preserved celloidin sections with a modified Fite method was not satisfactory. The granules

of the mast cells, which almost always stain deep red with this method, were of a very faint pink tint and just recognizable. No AFB were found in the sections.

DISCUSSION

The only clinical information on this patient we could get from a leprosy control unit was the diagnosis of lepromatous leprosy with a 10-year eye problem. Granulomas composed of epithelioid cells, macrophages, lymphocytes, and Langhans' giant cells, with some polymorphonuclear cells were distributed predominantly in the anterior segment of the eye specimen, sparing the bulk of choroid, and were also seen along the course of nerves in the sclera and in the retina.

The lesions in the eyes, and in many other internal organs, reported in the literature were mostly found in lepromatous-type patients and animals with a lepromatous reaction^(1, 2, 4, 5). However, in the testes of some borderline cases in the reactive phase, a tuberculoid granulomatous reaction with AFB has been well documented⁽³⁾. The reaction in the eye of our case was quite similar to that seen in those testes. Although we could not stain our old sections well enough to demonstrate AFB, the perineural thickening of the nerve in the sclera, the granulomatous lesions around it and within the iris and the ancillary body, make the most likely interpretation of the lesions borderline leprosy.

It is well documented that many leprosy patients are complicated with tuberculosis, and some authors consider "that the occasional reports of leprosy in posterior parts of the eye may have been due to syphilis or tuberculosis" rather than leprosy⁽²⁾. But, tuberculosis of the inner eyes is almost always a hematogenous infection; the granulomas are distributed in the iris, ciliary body, choroid, and retina where the blood supply is rich, and show no site preference. The distribution of the lesions in this eye, such as the involvement of the nerves in the sclera, the sparing of the choroid, and the granulomas present preferentially in the anterior segment of the eyeball, make the diagnosis of tuberculosis unlikely. Therefore, it is reasonable to state that this patient had borderline lepromatous disease of the eye.

Leprosy lesions are mainly found in the anterior aspect of the eye, involving the iris, ciliary body, and the anterior aspects of the sclera and episclera. Lesions in the posterior segment of the eyes are extremely uncommon. In a study of 250 leprosy patients, retinal lesions were reported in only two⁽⁶⁾. Therefore, the finding of microgranulomas in the retina of this patient is of special interest.

SUMMARY

A pathological study of an eye from a leprosy patient is reported. In addition to the granulomatous lesions in the anterior aspect of the eye, microgranulomas are demonstrated in the retina of this patient, a very uncommon finding in leprosy.

RESUMEN

Se reporta el estudio patológico de un ojo de un paciente con lepra. Además de las lesiones granulomatosas en la parte anterior del ojo, se demostraron microgranulomas en la retina de este paciente, un hallazgo muy común en lepra.

RÉSUMÉ

On relate ici les résultats d'une étude anatomo-pathologique de l'oeil chez un malade de la lèpre. Outre les lésions granulomateuses notées à l'examen antérieur de l'oeil, on a relevé des microgranulomes dans la rétine de ce malade. Ceci constitue une trouvaille fort inhabituelle dans la lèpre.

REFERENCES

1. DESIKAN, K. V. and JOB, C. K. Report on the study of eye lesions in three autopsied cases of leprosy. *Lepr. India* **42** (1970) 1-3.
2. HOBBS, H. E., HARMAN, D. J., REES, R. J. W. and MCDUGALL, A. C. Ocular histopathology in animals experimentally infected with *Mycobacterium leprae* and *M. lepraemurium*. *Br. J. Ophthalmol.* **62** (1978) 516-524.
3. JOB, C. K. and MACADEN, V. P. Leprous orchitis in reactional borderline cases. *Int. J. Lepr.* **31** (1963) 273-279.
4. POWELL, C. and SWAN, L. Pathological changes observed in 50 consecutive necropsies. *Am. J. Pathol.* **31** (1955) 1131-1147.
5. RIDLEY, D. S. and JOB, C. K. The pathology of leprosy. In: *Leprosy*. Hastings, R. C., ed. New York: Churchill Livingstone, 1985, pp. 127-128.
6. SOMERSET, E. J. and SEN, N. R. Leprosy lesions of the fundus oculi. *Br. J. Ophthalmol.* **40** (1956) 167-172.