

## *Facies Leprosa*: Resorption of Maxillary Anterior Alveolar Bone and the Anterior Nasal Spine in Patients with Lepromatous Leprosy in Mali<sup>1</sup>

Sandy C. Marks, Jr. and Gerard Grossetete<sup>2</sup>

*Facies leprosa*, a term used to describe resorption of bone in the facial region of patients with leprosy, was first introduced by Møller-Christensen and colleagues (9, 11, 12) in a series of reports on the skeletal remains of medieval populations with leprosy in Danish cemeteries. However, these osseous deformities were illustrated but not commented on in Plate III of Hansen's classic work (2) which shows a patient with nodular (lepromatous) leprosy and prominent resorption of the nasal spine and alveolar bone. These observations have confirmed in contemporary patient populations (6, 8, 10, 13, 16, 19-21) and consist of a syndrome of resorption in three areas of the maxilla: a) the hard palate itself; b) its inferior projection, the alveolar bone supporting the maxillary incisors; and c) its anterior extension, the anterior nasal spine. These studies have demonstrated that bone resorption in the anterior maxilla is a characteristic feature of leprosy, particularly of the lepromatous type.

Several clinical studies of *facies leprosa* have been reported. Michman and Sagher (8) examined the anterior nasal spine and maxillary alveolar process in 44 patients with lepromatous, borderline, or tuberculoid disease undergoing treatment in Jerusalem. They reported that advanced resorption occurred only in lepromatous patients, and concluded that resorption of the anterior nasal spine and maxillary alveolar bone are directly related and increase with the duration of the disease. That resorption is greatest in patients with lepromatous leprosy is not surprising, given the concentra-

tions of *Mycobacterium leprae* in the nasal mucosa of these individuals (4). However, Møller-Christensen (10) and Reichart and colleagues (15) in separate studies in Thailand and we (7) in Malaysia failed to find a direct correlation between resorptions in these two anterior projections of the maxilla. Møller-Christensen (10) found the incidence of nasal spine resorption (62.4%) to be much greater than maxillary alveolar resorption (16.3%) in 258 lepromatous patients. Reichart's study of 30 patients found atrophy of only the anterior nasal spine in 7, resorption of both nasal spine and maxillary alveolar bone in 6, and resorption of neither in 11 (15). In Malaysia (7) we found that resorption of bone in these two sites occurred independently in 76 patients with lepromatous leprosy. These discrepancies could be related to the climatic differences between Israel and the Malay peninsula. In Malaysia and Thailand the persistent high humidity keeps nasal secretions from forming dry, hard crusts. In the drier climate of Israel one would expect that crusting of nasal secretions would be more frequent and that removal of crusts by the patient might cause damage to the nasal mucosa. This, in turn, could lead to greater resorption of the nasal skeleton than that seen in the Malay peninsula, where it is always damp throughout the year and where nasal crusting causes much less discomfort to patients.

The purpose of the present report was to evaluate resorption of bone in the nasal spine and alveolar process of the anterior maxilla in patients with lepromatous leprosy in Mali, a country like Israel with a long dry season, and to ascertain if these events are dependent or independent.

### MATERIALS AND METHODS

Thirty-nine patients with lepromatous leprosy at the Institut Marchoux, O.C.C.G.E., Bamako, Mali, were examined

<sup>1</sup> Received for publication on 20 July 1987; accepted for publication on 1 September 1987.

<sup>2</sup> S. C. Marks, Jr., D.D.S., Ph.D., Department of Anatomy, University of Massachusetts Medical School, 55 Lake Avenue North, Worcester, Massachusetts 01655, U.S.A. G. Grossetete, M.D., Institut Marchoux, Bamako, Mali, West Africa.

radiographically and clinically. Lepromatous disease was determined by smears and clinical examination (6). All patients had been or were under treatment with multiple drug therapy, and none exhibited any evidence of relapse. All procedures were explained in detail to each patient who gave informed consent in advance.

Clinical evaluation of the anterior nasal spine was by palpation through facial skin at the base of the nose. We used three categories as described earlier (7): easily palpable, barely palpable, and not palpable. These were recorded as 2, 1, and 0, respectively. The osseous basis for this index of palpability of the anterior nasal spine has been documented radiographically in 20 patients with lepromatous leprosy (7) and 42 patients without leprosy (22). In each instance, those with an easily palpable spine (index of 2) showed a characteristic anterior projection of the maxilla radiographically. Similarly, those without a palpable spine (index of 0) had no anterior osseous projection, and patients in which the spine was barely palpable (index of 1) had an intermediate radiographic image. In addition, we examined the nasal septum of each patient for surface encrustations, and noted the incidence of septal perforations which could be easily identified by shining a light in one nostril while viewing the septum through the other nostril. Loss of alveolar bone in the anterior maxilla was measured radiographically as previously described (20) using a modification of the method of Schei, *et al.* (17). Measurements between definable landmarks (Fig. 1) between the maxillary central incisors to the nearest 0.5 mm were made using an adjustable, pointed calipers and a micrometer (Fig. 1). Alveolar bone loss was calculated and expressed as a percentage of the distance between the cemento-enamel junction and the apical foramen of the maxillary central incisors (20). An oral clinical examination of the maxillary incisor teeth included measurements of periodontal pocket depths, gingival recession, and tooth mobility. For each patient, we recorded the deepest periodontal probing depth in mm, the greatest extent of gingival recession measured in mm from the cervical line to the gingival crest and tooth mobility on a scale of 0-3 (1). These data were used

as indicators of the periodontal condition of the maxillary anterior dentition.

Statistical analysis of the results was by analysis of variance (18).

## RESULTS

The clinical consequences of alveolar bone loss are shown in Figure 2 which illustrates the range of periodontal conditions we encountered. Minimal bone loss (Fig. 2A = 17.5%; 2B = 10.5%) was accompanied by little gingival recession and gingivae with minimal (2A) or moderate (2B) inflammation manifested as swelling and loss of the characteristic surface stippling. In each of these patients maximal periodontal probing depth was less than 3 mm, recession less than 2 mm, and the teeth were not mobile. Advanced alveolar bone loss (2C = 48%) was accompanied by marked recession (7 mm), tooth mobility (2 on a scale of 0-3), and deep periodontal probing depths (6 mm). Notice that this patient (2C) has only one remaining maxillary incisor.

The clinical effects of resorption of the anterior nasal spine on the facial profile are shown in Figure 3. There was little difference in facial profile between those individuals whose anterior nasal spine could be palpated, whether easily (3A) or with difficulty (3B). However, a prominent saddle-nose deformity was present in those without a palpable nasal spine (3C, 3D).

Data from our study are summarized in The Table. We divided our patients into three groups based on the ease of palpation of the anterior nasal spine. While the number of patients in each group is different, their mean ages are similar. As resorption of the anterior nasal spine increases (left to right in The Table), so do the incidence of nasal crustings and perforations of the nasal septum. All patients with septal perforations exhibited nasal encrustations. All of our observations were made early in the annual 10-month dry season when one could expect the incidence of nasal encrustations to be lowest. Thus, our data probably underestimate the incidence of nasal crusts in this population. However, alveolar bone resorption is similar among the three groups, and there are no major differences with respect to periodontal pocket depths, reces-

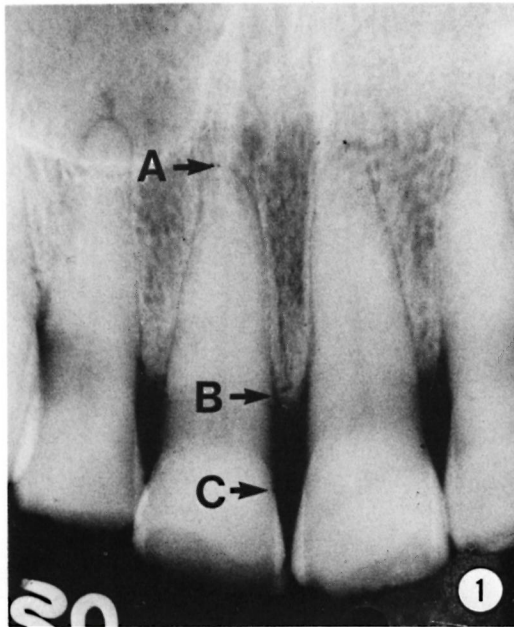


FIG. 1. Representative periapical radiograph of maxillary incisors illustrating landmarks used to calculate resorption of alveolar bone. A = apical foramen, B = crest of alveolar bone, C = cemento-enamel junction. Bone loss, calculated as  $BC/AC \times 100$ , is 28% in this patient. Lower left indicates patient's assigned number, formed in wire and taped to each film prior to exposure (original magnification  $\times 2.6$ ).

sion, or tooth mobility. Thus, there appears to be little correlation between resorption of the nasal spine and resorption of alveolar bone. This hypothesis is supported by the observations that: a) the two patients in Figure 2 with minimal recession and resorption of alveolar bone (2A, 2B) did not have palpable nasal spines; whereas the patient with advanced alveolar bone loss (2C) had a prominent nasal spine, and b) alveolar bone loss was similar for all three patients (Fig. 3; A, B, and C) with varying degrees of nasal spine resorption.

Resorption of the anterior nasal spine and alveolar bone loss have been plotted for each patient in Figure 4. Notice that despite changes in resorption of the nasal spine, the spread of alveolar bone resorption is similar among the groups. Examination of these data by analysis of variance failed to show a correlation between resorption of alveolar bone and the nasal spine. This analysis showed that the probability that they were not related is 92%.

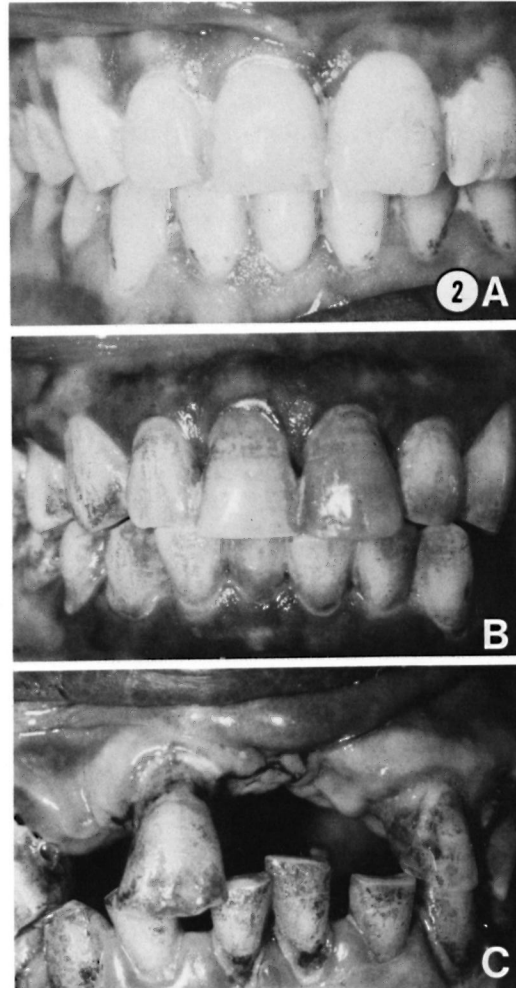


FIG. 2. Photographs of the anterior teeth in three patients illustrating the clinical appearance of minimal (A), moderate (B), and advanced (C) alveolar bone resorption, reflected as gingival recession.

## DISCUSSION

These data show that resorption both of the anterior nasal spine and alveolar bone in the anterior maxilla occurs in patients with lepromatous leprosy in Mali and that these are independent events.

Previous studies have shown that resorption of the anterior nasal spine is a characteristic feature of leprosy<sup>(8-12, 15, 20)</sup>. The resorption of alveolar bone in leprosy is believed to be mediated by osteoclasts<sup>(6)</sup> independent of periodontal disease<sup>(20, 21)</sup>, directly related to the length of untreated disease<sup>(13)</sup> and, by inference, to the presence of the leprosy bacillus. Whether re-

THE TABLE. Summary of observations by patient group.

	Palpability of interior nasal spine		
	2	1	0
Number of patients	19	11	9
Mean age in years (range)	36 (18-57)	32 (26-41)	35 (2-65)
Incidence of			
Nasal crustings	32%	55%	100%
Septal perforation	0	9%	89%
Mean resorption			
Maxillary anterior alveolar bone (range)	27% (3.4-71.2%)	25% (14.2-48.2%)	26.5% (10.5-49%)
Mean			
Pocketing in mm (max. value)	2.9 (6)	3.5 (6)	2.3 (3)
Recession in mm (max. value)	2.8 (10)	2.3 (10)	2.3 (8)
Mobility of maxillary incisors (max. value)	0.7 (2)	0.5 (2)	0.8 (2)

sorption of the anterior nasal spine is by similar mechanisms or results from secondary infections of cartilage and bone in the nasal septum is not known. Bone infections and resorption secondary to cutaneous infections is frequently observed in the extremities in leprosy (<sup>3, 14, 23</sup>), and secondary infection may play an important, though not necessarily a principal, role in damage to nasal cartilage and bone. Thus, local damage to the nasal mucosa could result in

resorption of the underlying cartilage or bone which then might spread to the anterior nasal spine. Our observations that the incidence of nasal encrustations was greater than and preceded septal perforations and nasal spine resorption suggest this may be the case.

Our data and the interpretation that resorption in these two projections of the anterior maxilla occur independently are similar to the conclusions of Møller-Christensen (<sup>10</sup>) and Reichart, *et al.* (<sup>15</sup>), who studied

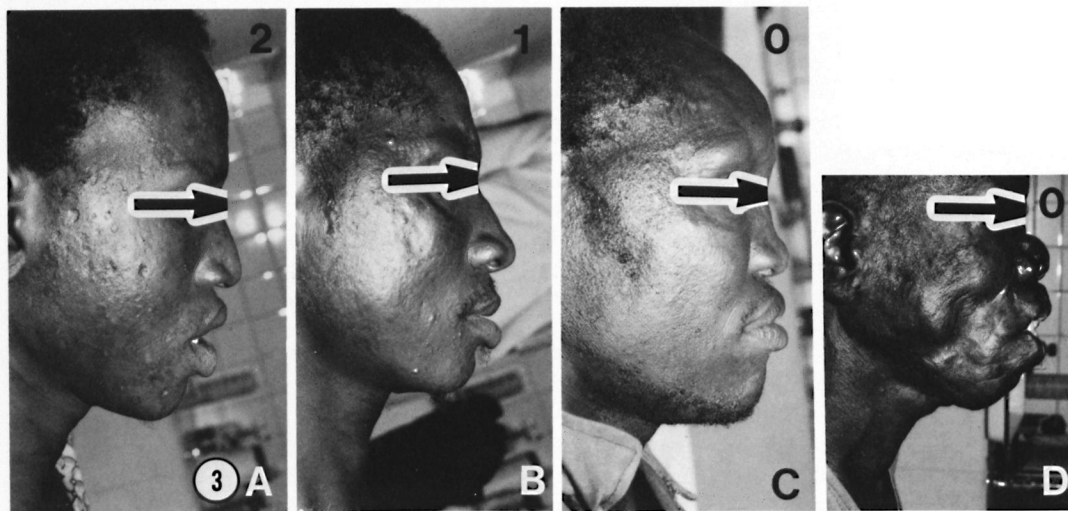


FIG. 3. Photographs of facial profiles illustrating patients with easily palpable (A), barely palpable (B), and nonpalpable (C) anterior nasal spines. These correspond to our numerical indices (2, 1 and 0, respectively) shown in upper right corner of each photograph. These patients' ages were 32, 30, and 31 years, respectively. Note that change in facial profile is imperceptible between A and B but dramatic when the nasal spine is resorbed. (C). Patient in D illustrates the facial deformities characteristic of long-standing nasal spine resorption; patients shown in C and D had large septal perforations.

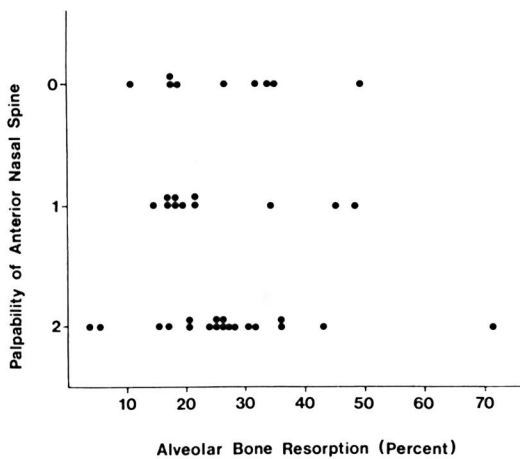


FIG. 4. Graph of resorption of anterior nasal spine plotted against maxillary anterior alveolar bone resorption in 39 patients with lepromatous leprosy. Resorption of anterior nasal spine is expressed as the ease of palpation; 2, 1 and 0 indicating, respectively, that this bony projection could be felt easily, with difficulty, or not at all. Thus, increased resorption is indicated by a higher position on the vertical axis.

populations of lepromatous patients in Thailand. However, this interpretation differs from that of Michman and Sagher<sup>(8)</sup> who concluded that resorption in these two areas is dependent. Our present data suggest that the difference in these studies is not merely one of climate.

### SUMMARY

Resorption of the anterior nasal spine and alveolar bone in the anterior maxilla was measured in 39 patients with lepromatous leprosy in Mali. Bone resorption occurred in both of these sites, but resorption in one did not predict resorption in the other. These data are interpreted to mean that resorptions of bone anterior (nasal spine) or inferior (alveolar bone) to bacillary populations in the nasal mucosa of patients with lepromatous disease in Mali occur independently.

### RESUMEN

Se midió el grado de reabsorción de la espina nasal anterior y del hueso alveolar de la maxila anterior en 39 pacientes con lepra lepromatosa de Mali. La reabsorción ocurrió en ambos sitios y la reabsorción en uno, no predijo la reabsorción en el otro. Estos datos indican que las reabsorciones del hueso anterior (espina nasal) o inferior (hueso alveolar) a la localización

de los bacilos en la mucosa nasal de los pacientes lepromatosos ocurren de manera independiente.

### RÉSUMÉ

On a étudié chez 39 malades du Mali la résorption de l'épine nasale antérieure et de la partie alvéolaire du maxillaire antérieur. On a observé qu'une résorption osseuse survenait en ces deux endroits, mais que la résorption dans l'un ne permettait pas de conclure à la résorption dans l'autre. Ces données permettent de conclure que les résorptions osseuses au niveau de l'épine nasale et de la partie alvéolaire du maxillaire antérieure suite à la colonisation bacillaire de la muqueuse nasale chez les malades atteints de lèpre lépromateuse au Mali, surviennent de manière indépendante.

**Acknowledgments.** This work was supported in part by the Fondation Raoul Follereau (GG) and the Research Fund for Mineral Metabolism at the University of Massachusetts (SCM). We thank the Director and staff of the Institut Marchoux, Bamako, Mali, for their support and assistance and Dr. M. F. R. Waters for valuable discussions. We particularly appreciate the help of Dr. Girard of the Centre Odontostomatologi que de Bamako, the willing participation of our patients, and the hospitality of the R. Boney family. We thank S. Baker and B. Singer for statistical consultation, B. Ek-Rylander, M. Giorgio and C. MacKay for technical assistance, and C. Karlsson and E. Larson for secretarial assistance.

### REFERENCES

1. CARRANZA, F. A., SR. *Glickman's Clinical Periodontology*. 6th ed. Philadelphia: W. B. Saunders, 1984, p. 317.
2. HANSEN, G. A. and LOOFT, C. *Leprosy: In Its Clinical and Pathological Aspects*. Walker, N., trans. Bristol: John Wright and Co., 1985, p. 11.
3. JOB, C. K. Pathology of leprosy osteomyelitis. *Int. J. Lepr.* **31** (1963) 26-33.
4. JOB, C. K., KARAT, A. B. and KARAT, S. The histopathological appearance of leprosy rhinitis and pathogenesis of septal perforation in leprosy. *J. Laryng.* **80** (1966) 718-732.
5. JOPLING, W. H. *Handbook of Leprosy*. 2nd ed. London: Heinemann Medical Books Ltd., 1978.
6. MARKS, S. C., JR. and SUBRAMANIAM, K. The cellular basis for alveolar bone loss in leprosy. *Lepr. Rev.* **49** (1978) 297-303.
7. MARKS, S. C., JR., SUBRAMANIAM, K., TAN, J., NAH, S. H. and WATERS, M. F. R. Resorption of the anterior nasal spine and maxillary anterior alveolar bone in patients with lepromatous leprosy in Malaysia. *Ann Acad. Med. Singapore* (in press).
8. MICHMAN, J. and SAGHER, F. Changes in the anterior nasal spine and the alveolar process of the maxillary bone in leprosy. *Int. J. Lepr.* **25** (1957) 217-222.

9. MØLLER-CHRISTENSEN, V. *Ten Lepers from Naestved in Denmark: A Study of Skeletons from a Medieval Leper Hospital*. Copenhagen: Danish Science Press, Ltd., 1953, pp. 1-160.
10. MØLLER-CHRISTENSEN, V. Changes in the anterior nasal spine and the alveolar process of the maxilla in leprosy; a clinical examination. *Int. J. Lepr.* **42** (1974) 431-435.
11. MØLLER-CHRISTENSEN, V. *Leprosy Changes of the Skull*. Odense, Denmark: Odense University Press, 1978, pp. 1-148.
12. MØLLER-CHRISTENSEN, V., BAKKE, S. N., MELSOM, R. S. and WAALER, E. Changes in the anterior nasal spine and the alveolar process of the maxillary bone. *Int. J. Lepr.* **20** (1952) 335-340.
13. NAH, S. H., MARKS, S. C. and SUBRAMANIAM, K. Relationship between the loss of maxillary anterior alveolar bone and the duration of untreated lepromatous leprosy in Malaysia. *Lepr. Rev.* **56** (1985) 51-55.
14. PATERSON, D. E. Bone changes in leprosy: their incidence, progress, prevention and arrest. *Int. J. Lepr.* **29** (1961) 393-422.
15. REICHART, P., ANANATASAN, T. and REZNIK, G. Gingiva and periodontium in lepromatous leprosy. A clinical, radiological, and microscopical study. *J. Periodontol.* **47** (1976) 455-460.
16. RENDALL, J. R. and MCDUGALL, A. C. Reddening of the upper central incisors associated with periapical granuloma in lepromatous leprosy. *Br. J. Oral Surg.* **13** (1976) 271-277.
17. SCHEI, O., WAERHAUG, J., LOVDAL, A. and ARNO, A. Alveolar bone loss as related to oral hygiene and age. *J. Periodontol.* **30** (1959) 7-16.
18. SNEDECOR, G. W. and COCHRAN, W. G. *Statistical Methods*. 7th ed. Ames, Iowa: Iowa State University Press, 1980, p. 192.
19. SOUTHAM, J. C. and VENKATARAMAN, B. K. Oral manifestations of leprosy. *Br. J. Oral Surg.* **10** (1973) 272-279.
20. SUBRAMANIAM, K. and MARKS, S. C., JR. Alveolar bone loss in leprosy; a clinical and radiological study. *Lepr. Rev.* **49** (1978) 287-296.
21. SUBRAMANIAM, K., MARKS, S. C., JR. and NAH, S. H. The rate of loss of maxillary anterior alveolar bone height in patients with leprosy. *Lepr. Rev.* **54** (1983) 119-127.
22. SUBRAMANIAM, K., MARKS, S. C., JR., NAIR, S. and HO, K. H. Magnitude of maxillary anterior alveolar bone resorption and palpability of the anterior nasal spine in Malaysian adults. *J. Malaysian Soc. Health* **5** (1985) 67-70.
23. WARREN, C. Tarsal bone disintegration in leprosy. *J. Bone Jt. Surg.* **53B** (1971) 688-695.