

Diagnostic Efficacy of Cutaneous Nerve Biopsy in Primary Neuritic Leprosy¹

Mary Jacob and Rachel Mathai²

Primary neuritic leprosy presents clinically as peripheral neuropathy with functional impairment of single or multiple nerves but without two of the cardinal signs of leprosy, i.e., the typical skin lesions and the presence of acid-fast bacilli (5, 14). The diagnosis of this form of leprosy and its differentiation from other causes of peripheral neuropathy becomes difficult since even skin biopsies from anesthetic areas may fail to show histologic changes suggestive of leprosy. Investigations such as nerve conduction velocity and electromyography (EMG) may show sensory-motor deficits suggestive but not diagnostic of leprosy (16).

Cutaneous nerve biopsy is a simple office procedure which does not require any sophisticated equipment (7, 9, 13) and has been found to be useful in the diagnosis of peripheral neuropathy of unknown origin (Jacob, M. A histological study of cutaneous nerves in peripheral neuropathy of unknown etiology. MNAMS Thesis, 1978). It has been used in diagnosing leprosy and in assessing the activity of the disease (6, 8, 11, 15). Studies of nerve pathology have also afforded useful data on the pathogenesis of leprosy (10). However, there are few published reports on the efficacy of routine nerve biopsies in the diagnosis of primary neuritic leprosy among cases seen at a general hospital. This paper describes and reviews the results from such a study done on 77 patients.

MATERIALS AND METHODS

Patients with symptoms of peripheral neuropathy who attended or were referred to the leprosy clinic of the Dermatology Department of the Christian Medical College Hospital, Vellore, India, from 1982 to 1986

were screened for skin changes suggestive of leprosy. Those with hypopigmented patches, positive skin smears, or skin histology consistent with leprosy were excluded from this study. On the basis of the clinical features, the peripheral neuropathy was classified as: 1) pure motor neuropathy, when there was only motor deficit without sensory or autonomic impairment; 2) mononeuritis multiplex, when the neurological deficit was attributable to damage at the level of the nerve trunk(s); and 3) distal polyneuropathy, which formed a heterogeneous group with the following neurological deficits: a) only distal sensory deficit, such as "glove" and/or "stocking" anesthesia; b) patchy sensory deficit on hands or feet; and c) sensory deficit as in a) or b) with motor deficit.

A nerve biopsy from a representative cutaneous nerve was taken for histopathological examination and acid-fast bacilli (AFB) staining. The site of the biopsy depended on the site of the neurological deficit. When "glove-and-stockings" anesthesia was present, the cutaneous branch of the radial nerve was biopsied at the wrist. When only "stocking" anesthesia was present, the cutaneous branch of the common peroneal nerve just medial to the lateral malleolus, or the sural nerve behind the lateral malleolus, was biopsied. If there was a palpable cutaneous nerve in close proximity to an area of sensory loss, such a nerve was chosen. A thin sliver of the main peripheral trunk, such as the ulnar nerve, was taken in a few cases where it was not feasible to biopsy a cutaneous nerve.

The procedure used for the cutaneous nerve biopsy was as follows: A linear mark with gentian violet was made on the skin over the palpated nerve, and the skin was cleansed with alcohol and iodine. After establishing local anesthesia, a transverse incision 1 cm in length was made in the skin and the subcutaneous tissue was teased with an artery forceps until the nerve was iden-

¹ Received for publication on 26 May 1987; accepted for publication in revised form on 17 September 1987.

² M. Jacob, M.B.B.S., M.N.A.M.S., Associate Professor; R. Mathai, M.B.B.S., D.D., F.R.C.P.(G.), Professor, Department of Dermatology, Christian Medical College Hospital, Vellore 632004, India.

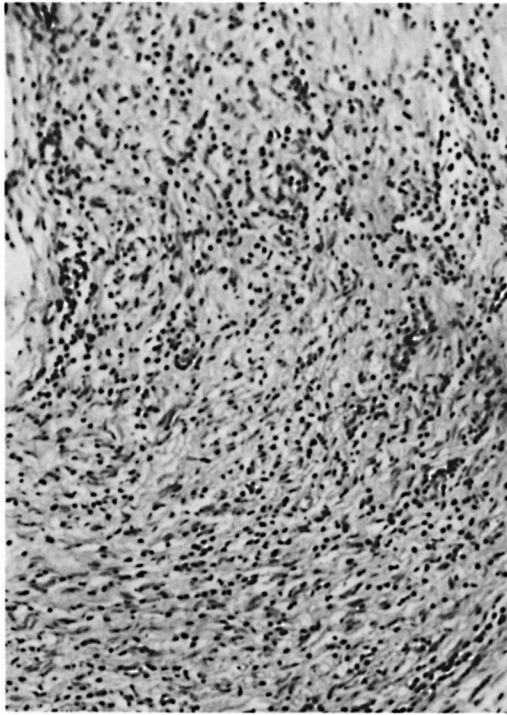


FIG. 1. Lepromatous type of leprosy neuritis [hematoxylin and eosin (H&E) $\times 160$.].

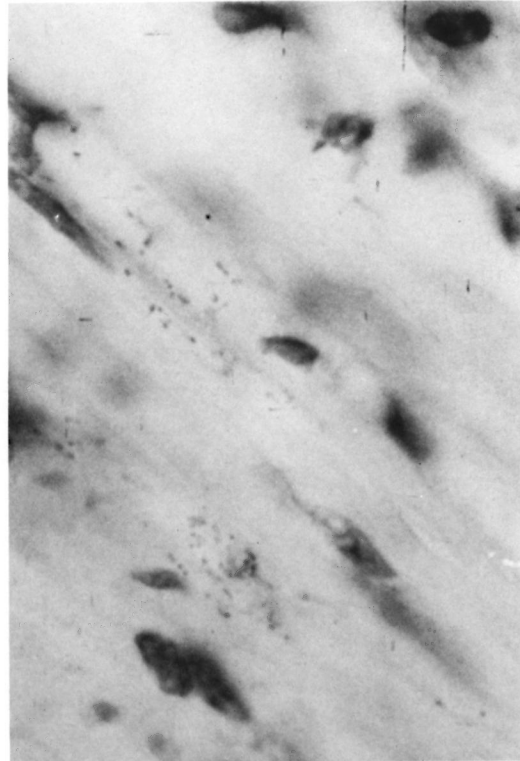


FIG. 2. Acid-fast bacilli in the nerve in lepromatous type of leprosy neuritis (modified Fite-Faraco $\times 1600$).

tified. The nerve was lifted with a cotton suture and a 1-cm piece of the nerve was sliced with a scalpel and put into Formalin solution. The skin was closed with cotton sutures, and the nerve tissue was sent for processing and staining. AFB staining by a modified Fite-Faraco method and stains for axon and myelin were done.

Wherever indicated, investigations such as a glucose tolerance test, an X-ray of the spine, a collagen workup, electromyography, and nerve conduction studies were done to rule out other possible causes of peripheral neuropathy.

A histological diagnosis of indeterminate leprosy was made when the nerve showed lymphocytic infiltration; tuberculoid leprosy, when an infiltrate of epithelioid cells with or without giant cells and lymphocytes was seen; borderline leprosy, when in addition to the above infiltrate some foam cells were present; and lepromatous leprosy, when macrophages filled with AFB and a round cell infiltrate were observed^(10, 12) (Figs. 1 and 2). When the biopsied nerve showed a mononuclear infiltrate with fibrosis and hy-

alinization, a presumptive diagnosis of leprosy neuritis was made (Fig. 3).

RESULTS

A total of 77 patients, 57 males and 20 females, were studied. The youngest patient was 10 years old; the oldest was 67. All but two were older than 16 years. Forty-eight (62.3%) had distal polyneuropathy, 25 (32.5%) had mononeuritis multiplex, and 4 (5.2%) had pure motor neuropathy.

In 48 of the 77 patients (62%), the superficial branch of the common peroneal nerve was biopsied; in 16 (21%), the radial cutaneous nerve. Other nerves studied were the sural (6), the ulnar cutaneous (4), and one each of the ulnar, the supratrochlear, and a cutaneous nerve on the dorsum of the hand.

Thirty-eight of the 77 patients (49.4%) were confirmed to have leprosy on the basis of nerve biopsy. The histological confirmation of leprosy by age is shown in Table 1. No significant correlation by age was observed. However, both patients younger than

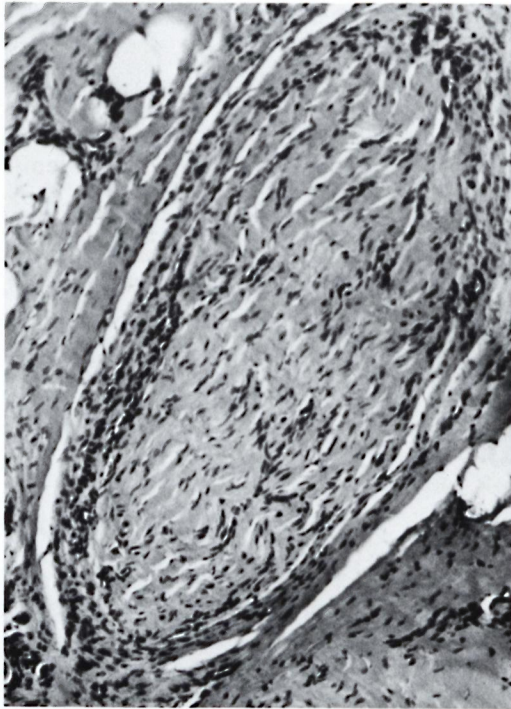


FIG. 3. Hyalinized nerve fascicle with lymphocytic infiltration (H&E $\times 160$).

17 years of age had leprosy proven by nerve biopsy, while none of the six patients older than 60 showed histological evidence of leprosy. The male : female ratio was similar to the histologically confirmed group compared to those who did not have histological evidence of leprosy.

Fourteen of 25 patients (56%) with mononeuritic multiplex and 24 out of 48 patients (50%) with distal polyneuropathy had histological evidence of leprosy as compared to none of the four patients with pure motor neuropathy.

Seven of nine patients (78%) with "glove-and-stocking" anesthesia had leprosy confirmed histologically as compared to only

TABLE 1. *Histological confirmation of leprosy according to age.*

Age group (yr)	No. patients	Leprosy confirmed	
		No.	%
16 or younger	2	2	100.0
17-40	35	17	48.6
41-60	34	19	55.9
61 and older	6	—	0.0
Total cases	77	38	49.4

TABLE 2. *Histological diagnosis of leprosy and presence of acid-fast bacilli (AFB) in biopsy.*

Leprosy type	Leprosy confirmed		AFB present	
	No.	%	No.	%
LL	5	13.1	5	100.0
BL	5	13.1	5	100.0
BT	2	5.3	2	100.0
TT	8	21.1	2	25.0
Indeterminate	7	18.4	2	28.6
Unspecified	11	29.0	2	18.2
Total	38	100.0	18	47.4

12 of 25 patients (48%) with patchy sensory deficit; 5 of 11 patients (45.5%) who had only "stocking" anesthesia were confirmed to have leprosy.

The entire leprosy spectrum was observed in the nerve biopsies, as presented in Table 2. Of the 38 patients with confirmed leprosy, 10 (26.3%) were in the lepromatous end of the spectrum and all showed AFB in the nerve. Of the eight cases of tuberculoid leprosy, three showed segmental necrotizing granulomatous neuritis. There were 11 patients (28.9%) whose classification could not be specified histologically.

Fifty-four (70.1%) of the 77 patients had thickened nerves as judged by palpation. Of these, only 35 (64.8%) had leprosy confirmed by biopsy. Among the 23 who had clinically normal nerves, three (13%) had changes suggestive of leprosy.

The biopsies of 39 patients (50.6%) showed no evidence of leprosy. Eleven (28.2%) of the 39 patients showed demyelination and axonal loss but no evidence of inflammation or AFB in the sections. Of these 11 patients, 6 patients who were >50 years old were found to have diabetes mellitus; 1 was diagnosed as having hereditary sensory neuropathy; 1 had a demyelinating disease based on clinical and EMG findings. No cause was found in the remaining three patients. Two patients (ages 42 and 60) showed hyalinization of nerve. There were two patients, aged 32 and 33, whose nerve biopsy showed vasculitis; further laboratory investigations revealed that one had polyarteritis nodosa. In 24 (61.6%) out of the 39 cases, there was no significant histological change in the nerves. Nine (37.5%) of these nerves were clinically enlarged.

DISCUSSION

Peripheral neuropathy is caused by a variety of factors that include infections, metabolic or nutritional disorders, drug reactions, and hereditary diseases (¹⁶). Among infections, leprosy ranks the highest since one of the basic features of *Mycobacterium leprae* is its neurotropism (⁴). Thus, in regions endemic for leprosy, there is a tendency to attribute it as the cause of peripheral neuropathy without adequate investigation.

Clinically, leprous neuropathy mimics other types of peripheral neuropathy (Jacob, M. A histological study of cutaneous nerves in peripheral neuropathy of unknown etiology. MNAMS Thesis, 1978). In the present series, nerve biopsy confirmed the diagnosis of leprosy in about half of the patients and five of them had lepromatous leprosy (LL). Lepromatous leprosy presenting as primary neuritic leprosy is not often reported but its existence has been documented by other workers (^{2,3,6}). It is not possible to have false-positive results since the histological features in the nerve are highly specific in leprosy (¹⁰). On the other hand, false-negative results can be attributed to any of the following reasons: a) Even though the nerve subjected to biopsy is carefully chosen, that particular nerve may not have been affected; b) the disease may be in its early stages, causing symptoms without showing demonstrable pathological changes, particularly in the cutaneous nerves; such a situation arises more in mononeuritis multiplex than in distal polyneuropathy; and c) changes such as fibrosis and hyalinization or demyelination and axonal degeneration without inflammation are not conclusive evidence of leprosy.

A repeat biopsy from another site and/or at a later date can be rewarding. In four of our patients a second nerve biopsy was performed and in two of these, lesions diagnostic of leprosy were seen.

It is known that despite extensive investigations, the etiology of peripheral neuropathy remains unknown in about a quarter of the cases, even in a highly specialized center (¹). Pannikar, *et al.* (¹⁵) diagnosed primary neuritic leprosy in 11 out of 30 patients with peripheral neuropathy based on cutaneous nerve biopsy alone. Our experience has been better: in 50% of our patients,

a diagnosis of leprosy was established with nerve biopsy alone. In 20% of our patients, another diagnosis, such as diabetes mellitus, vasculitis due to collagen disorders, spinal canal stenosis, and demyelinating diseases, could be established. In a hyperendemic area, leprosy may coexist with other common diseases, such as diabetes mellitus, and not-so-common conditions, such as collagen vascular diseases, spinal canal stenosis, etc. Thus, a positive finding of another etiological factor should not exclude a clinical suspicion of leprosy. In hyperendemic areas, it would be wise to treat a patient for leprosy, even if the nerve biopsy is inconclusive, provided the clinical suspicion is high and detailed investigations for other causes of peripheral neuropathy yield negative findings.

The duration of symptoms did not correlate with the severity of nerve damage as seen histologically. Contrary to expectation, some patients whose symptoms were present only for 2–3 months showed hyalinization of the biopsied nerve. Others with a long duration of symptoms showed inflammatory changes in the nerve with its structure still preserved. Thickening of a nerve as judged clinically was also misleading as a diagnostic criterion.

The present study has shown that a biopsy of cutaneous nerve is a highly rewarding test in establishing a diagnosis of primary neuritic leprosy.

SUMMARY

The role of nerve biopsy in the diagnosis of primary neuritic leprosy was evaluated in a study of 77 patients who had symptoms of peripheral neuropathy without hypopigmented patches, positive skin smears, or a skin biopsy consistent with leprosy. A biopsy of a representative cutaneous nerve near the site of the neurological deficit was taken for histopathological examination and acid-fast staining. Nearly half of the patients had leprosy confirmed by nerve biopsy, and the entire spectrum of leprosy was represented. No significant relationship was seen by age or sex or type of neuropathy. The duration of symptoms did not correlate with the severity of nerve damage as seen histologically. The probability of false-positive or false-negative results is discussed in light of clinical management. Being a relatively

simple office procedure, a cutaneous nerve biopsy is strongly recommended as an important diagnostic tool, particularly for primary neuritic leprosy.

RESUMEN

Se hizo un estudio sobre la utilidad de la biopsia de nervios para establecer el diagnóstico de la lepra neurítica primaria en 77 pacientes con síntomas de neuropatía periférica pero sin manchas hipocrómicas, sin bacilos en linfa cutánea y sin biopsias dérmicas indicativas de lepra. En cada caso, se tomó una biopsia de un nervio cutáneo cercano al sitio del déficit neurológico para su examen histopatológico y bacteriológico (bacilos ácido-resistentes). Casi la mitad de los pacientes tuvieron lepra confirmada por la biopsia del nervio y todo el espectro de la lepra estuvo representado. No se observó ninguna relación significativa entre edad, sexo o tipo de neuropatía. La duración de los síntomas no correlacionó con la severidad del daño nervioso establecida histológicamente. Se discute la probabilidad de resultados falso-positivos o falso-negativos en función del manejo clínico de los casos. Siendo la biopsia de nervios cutáneos un procedimiento de gabinete relativamente simple, su práctica se recomienda como un importante medio de diagnóstico, particularmente para la lepra neurítica primaria.

RÉSUMÉ

On a évalué la contribution de la biopsie des nerfs pour le diagnostic de la lèpre neuritique primaire, au cours d'une étude menée chez 77 malades qui présentaient des symptômes de neuropathies périphériques sans macules hypopygmentées, dont les frottis cutanés étaient positifs, ou dont la biopsie cutanée était compatible avec la lèpre. On a soumis à un examen histopathologique et à une coloration acido-résistante une biopsie de nerf cutané, prélevée près du site d'un déficit neurologique. Près de la moitié des malades présentaient une lèpre confirmée par la biopsie nerveuse. Le spectre entier de la lèpre était représenté. Aucune relation significative n'a été observée en ce qui concerne l'âge, le sexe, ou le type de lésion nerveuse. La durée des symptômes n'était pas en corrélation avec la gravité de l'atteinte nerveuse telle qu'elle apparaissait à l'examen histologique. La probabilité d'obtenir des résultats faussement positifs ou faussement négatifs est discutée à la lumière des mesures cliniques qui avaient été prises. La biopsie des nerfs cutanés, une technique relativement simple à utiliser dans un cabinet de consultation, est recommandée fortement comme outil diagnostique, particulièrement pour le diagnostic de la lèpre neuritique primaire.

Acknowledgments. We are grateful to Prof. Sushil M. Chandi and the Pathology Department for histo-

logical studies, and to Prof. P. S. S. Rao and the Biostatistics Department for statistical help.

REFERENCES

1. ADAMS, R. D. and VICTOR, M. Diseases of the peripheral nerves. In: *Principles of Neurology*. 3rd ed. Adams, R. D. and Victor M., eds. New York: McGraw Hill Book Company, 1985, chap. 45, p. 960.
2. BASOMBIO, G. and BOSQ, F. J. Lepromatous leprosy with pure neural onset. Abstract in *Int. J. Lepr.* **29** (1961) 535.
3. CHANDI, S. M. *Studies on the pathology of leprosy neuritis*, Ph.D. thesis. Madras University, Madras, 1984.
4. CHAROSKY, C. B., GATTI, J. C. and CARDAMA, J. E. Neuropathies in Hansen's disease. *Int. J. Lepr.* **51** (1983) 576-586.
5. DHARMENDRA. The Indian classification. In: *Leprosy*. Vol. 1. Dharmendra, ed. Bombay: Kothari Medical Publishing House, 1978, chap. 3, pp. 330-340.
6. DHARMENDRA, RAMANUJAM, K. and RAMU, G. Pure polyneuritic leprosy of tuberculoid type. *Lepr. India* **38** (1966) 152-158.
7. DYCK, P. J. and TOFGREN, E. P. Nerve biopsy: choice of nerve, method, symptoms and usefulness. *Med. Clin. North Am.* **52** (1968) 885-893.
8. ENNA, C. D., JACOBSON, R. R. and MANSFIELD, R. E. An evaluation of sural nerve biopsy in leprosy. *Int. J. Lepr.* **38** (1970) 278-281.
9. HAIMANOT, R. T., MSHANA, R. N., MCDUGALL, A. C. and ANDERSEN, J. G. Sural nerve biopsy in leprosy patients after varying periods of treatment: histopathological and bacteriological findings on light microscopy. *Int. J. Lepr.* **52** (1984) 163-170.
10. JOB, C. K. and DESIKAN, K. V. Pathologic changes and their distribution in peripheral nerves in lepromatous leprosy. *Int. J. Lepr.* **36** (1968) 257-270.
11. JOPLING, W. H. Borderline (dimorphous) leprosy maintaining a polyneuritic form for eight years: a case report. *Trans. R. Soc. Trop. Med. Hyg.* **50** (1956) 478-480.
12. LIU, T. C. and QUI, J. S. Pathological findings on peripheral nerves, lymph nodes and visceral organs of leprosy. *Int. J. Lepr.* **52** (1984) 377-383.
13. MATHAI, R. Challenges in leprosy—a clinician's overview (Ambady oration 1982). *Indian J. Dermatol. Venereol.* **48** (1982) 4-13.
14. NOORDEEN, S. K. Epidemiology of polyneuritic type of leprosy. *Lepr. India* **44** (1972) 90-96.
15. PANNIKAR, V. K., ARUNTHATHI, S., CHACKO, C. J. G. and FRITSCHI, E. P. A clinico-pathological study of primary neuritic leprosy. *Lepr. India* **55** (1983) 212-221.
16. WORLD HEALTH ORGANIZATION STUDY GROUP. Peripheral neuropathies. WHO Tech. Rep. Ser. 654, 1980, p. 61.