

13. JIMENEZ, J. and LARSSON, L. Heating cells in acid methanol for 30 min without freeze-drying provides adequate yields of fatty acids and alcohols for gas chromatographic characterization of mycobacteria. *J. Clin. Microbiol.* **24** (1986) 844–845.
14. KIEHN, T. E., EDWARDS, F. F., BRANNON, P., TSANG, A. Y., MAIO, M., GOLD, J. W. M., WHIMBEY, E., WONG, B., McCLATCHY, J. K. and ARMSTRONG, D. Infections caused by *Mycobacterium avium* complex in immunocompromised patients: diagnosis by blood culture and fecal examination, antimicrobial susceptibility tests, and morphological and seroagglutination characteristics. *J. Clin. Microbiol.* **21** (1985) 168–173.
15. LARSSON, L., DRAPER, P. and PORTAELS, F. Use of gas chromatography to differentiate *Mycobacterium leprae* from cultivable armadillo-derived mycobacteria, *M. avium/intracellulare*, and *M. lepraemurium* by analysis of secondary alcohols. *Int. J. Lepr.* **53** (1985) 441–446.
16. LARSSON, L. and ODHAM, G. Injection principles on capillary gas chromatographic analysis of bacterial fatty acids. *J. Microbiol. Meth.* **3** (1984) 77–82.
17. LÉVY-FRÉBAULT, V., PANGNON, B., BURÉ, A., KATLAMA, C., MARCHE, C. and DAVID, H. L. *Mycobacterium simiae* and *Mycobacterium avium-M. intracellulare* mixed infection in acquired immune deficiency syndrome. *J. Clin. Microbiol.* **25** (1987) 154–157.
18. MINNIKIN, D. E., MINNIKIN, S. M., PARLETT, J. M., GOODFELLOW, M. and MAGNUSSON, M. Mycolic acid patterns of some species of *Mycobacterium*. *Arch. Microbiol.* **139** (1984) 225–231.
19. PORTAELS, F. Le SIDA et les mycobactéries atypiques. *Ann. Soc. Belg. Med. Trop.* **67** (1987) 93–116.
20. PORTAELS, F., DE MUYNCK, A. and SYLLA, M. P. Selective isolation of mycobacteria from soil: a statistical analysis approach. *J. Gen. Microbiol.* **134** (1988) 849–855.
21. ROTH, R. I., OWEN, R. L., KEREN, D. F. and VOLBERDING, P. A. Intestinal infection with *Mycobacterium avium* in acquired immune deficiency syndrome (AIDS). *Dig. Dis. Sci.* **30** (1985) 497–504.
22. SCHNEEBAUM, C. W., NOVICK, D. M., CHABON, A. B., STRUTYNSKY, N., YANCOVITZ, R. and FREUND, S. Terminal ileitis associated with *Mycobacterium avium-intracellulare* infection in a homosexual man with acquired immune deficiency syndrome. *Gastroenterology* **93** (1987) 1127–1132.
23. STACEY, A. R. Isolation of *Mycobacterium avium-intracellulare-scrofulaceum* complex from faeces of patients with AIDS. *Br. Med. J.* **293** (1986) 1194.
24. VALERO-GUILLEN, P., MARTIN-LUENGO, F., LARSSON, L., JIMENEZ, J., JUHLIN, I. and PORTAELS, F. Fatty and mycolic acids of *Mycobacterium malmoense*. *J. Clin. Microbiol.* **26** (1988) 153–154.
25. WAYNE, L. G. The atypical mycobacteria: recognition and disease association. *Crit. Rev. Microbiol.* **12** (1985) 185–222.
26. WOLINSKY, E. Nontuberculous mycobacteria and associated diseases. *Am. Rev. Respir. Dis.* **119** (1979) 107–159.
27. WOLINSKY, E. and RYNEARSON, T. K. Mycobacteria in soil and their relation to disease-associated strains. *Am. Rev. Respir. Dis.* **97** (1968) 1032–1037.
28. YOUNG, L. S., INDERLIED, C. B., BERLIN, O. B. and GOTTLIEB, M. S. Mycobacterial infections in AIDS patients with an emphasis on the *Mycobacterium avium* complex. *Rev. Infect. Dis.* **8** (1986) 1024–1033.

## Comedones Induced by Coconut Oil in a Borderline Tuberculoid Lesion

### TO THE EDITOR:

A 42-year-old female presented with a hypopigmented anesthetic patch over her left knee of 1½ years duration. Diagnosed as a case of tuberculoid leprosy, she had been treated with monthly rifampin and daily dapsone for 13 months. She had been advised to discontinue treatment, and she came to us for a second opinion.

On examination, comedones were observed over the hypopigmented, anesthetic, borderline tuberculoid lesion (Fig. 1). The comedones could be extracted with a comedo extractor. A biopsy stained with hematoxylin and eosin (H&E) showed a compact, perineural and periadnexal epithelioid granuloma in the reticular and deeper der-

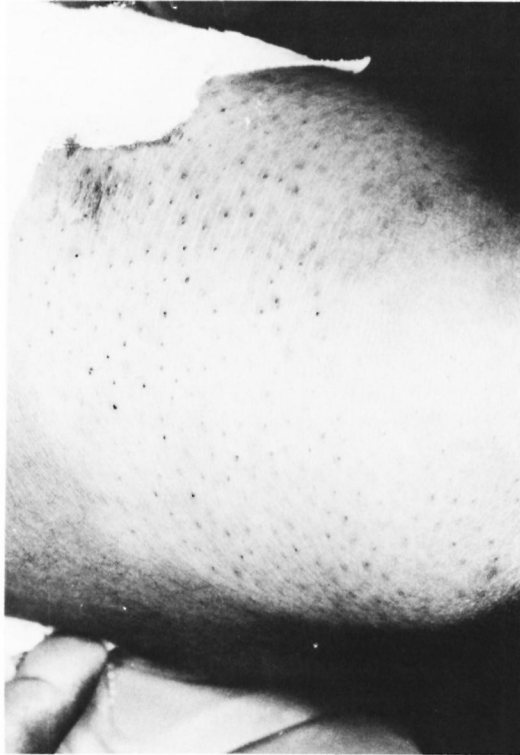

FIG. 1. Borderline tuberculoid lesion showing comedones.

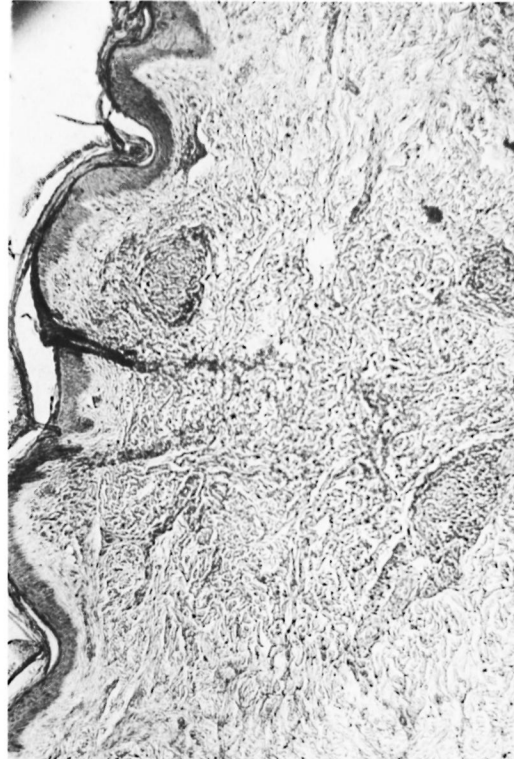


FIG. 2. Tuberculoid granuloma with follicular plugging (H&E  $\times 10$ ).

mis. The epidermis showed hyperkeratosis and follicular plugging (Fig. 2).

The patient stated that she was in the habit of massaging coconut oil over the affected site because the skin was dry. Cutting-oil<sup>(2)</sup> and various cosmetics<sup>(1)</sup> are known to be comedogenic. The comedogenicity of coconut oil has not to our knowledge been reported. The presence of comedones in a leprosy lesion where atrophy of the appendages occurs is another interesting finding.

—C. R. Srinivas, M.D.

Reader  
Department of Dermatology  
and Venereology

—Ambrish Padhee

Assistant Professor  
Department of Pathology

—C. Balanchandran, M.D.

Assistant Professor  
Department of Dermatology  
and Venereology

—S. D. Shenoy, M.D.

Lecturer  
Department of Dermatology  
and Venereology

—Sandhya Acharya, M.B.B.S.

Resident  
Department of Dermatology  
and Venereology

—K. Ramnarayan, M.D.

Associate Professor  
Department of Pathology  
Kasturba Medical College  
and Hospital  
Manipal 576119, India

#### REFERENCES

1. BRONAUGH, R. L. and MAIBACH, H. I. Primary irritant, allergic contact, phototoxic and photoallergic reactions to cosmetics and tests to identify problem products. In: *Principles of Cosmetics for Dermatologists*. Frost, P. and Horwitz, S. N., eds. Toronto: C. V. Mosby Company, 1982, pp. 223–243.
2. CRONIN, E. Miscellaneous occupational. In: *Contact Dermatitis*. Cronin, E. London: Churchill Livingstone, 1980, pp. 839–878.