

INTERNATIONAL JOURNAL OF LEPROSY

And Other Mycobacterial Diseases

VOLUME 56, NUMBER 4

DECEMBER 1988

Reactional States in the Nasal Mucosa: A Clinical and Histopathological Study¹

Anand Job and Chinoy J. G. Chacko²

The nose in leprosy has been extensively studied with regard to the spread of this disease through droplet infection (7). In addition, involvement of the nasal mucosa in early cases of leprosy has been reported (2). In clinical studies it is found that the nasal mucosa is affected in all patients with advanced lepromatous disease (1). In tuberculoid disease, however, only patients with external nose lesions show extension of the lesions to the nasal mucous membrane, especially during the reactive phase (8,9).

In our study the gross and microscopic changes in the nasal mucosa during reactive phases are described.

MATERIALS AND METHODS

Our study was conducted on 20 leprosy patients with reactions admitted to the Schieffelin Leprosy Research and Training Centre, Karigiri, India. The patients were clinically, bacteriologically, and histopath-

ologically examined to arrive at their classifications (4).

The nose was examined clinically for septal perforation, hypertrophy or atrophy of the turbinates, ulceration, and congestion (Table 1). Nasal biopsies were obtained from the anterior ends of both interior turbinates using a Takahashi nasal biopsy forceps after surface application of 2% xylocaine with 1:200,000 adrenaline for 5 min. The specimens were fixed in Zenker-formol for 4 hr, transferred to 70% alcohol, and processed for paraffin sections. Sections of 5 μ m thickness were cut and stained with hematoxylin and eosin (H&E) as well as a modified Fite's stain (6). Microscopic evidence for erythema nodosum leprosum (ENL) and reversal reaction was looked for. All of the patients were biopsied prior to instituting treatment for the reaction.

RESULTS

The age of the patients ranged from 22 to 67 years. There were 19 males and 1 female. Duration of illness ranged from 3 months to 19 years. Fifteen patients had received dapsone on a daily dosage of 50 mg to 100 mg for periods varying from 6 months to 11 years. One patient had been on a daily dosage of 75 mg of dapsone and 100 mg of clofazimine for 3 years. Another patient had

¹ Received for publication on 12 January 1987; accepted for publication in revised form on 22 July 1988.

² A. Job, M.S., D.L.O., Lecturer, Department of E.N.T., Christian Medical College and Hospital, Vellore 632004, South India. C. J. G. Chacko, M.D., Ph.D., Professor of Pathology, Christian Medical College and Hospital, Vellore and Radda Barnen Research Laboratories, Schieffelin Leprosy Research and Training Centre, Karigiri 632106, India.

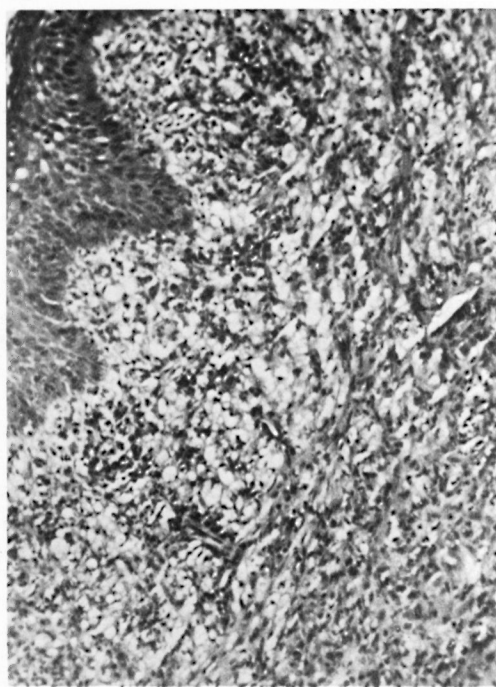


FIG. 1. Nasal mucosa of borderline lepromatous patient showing squamous metaplasia of the lining epithelium and extensive infiltration of the subepithelial tissue with foamy macrophages, few lymphocytes, and numerous neutrophils (H&E $\times 200$).

received 100 mg of dapsone for 3 months and 600 mg of rifampin for 3 weeks: One patient had had no treatment, and the treatment details for two other patients were not known.

Ten patients with lepromatous leprosy and four with borderline leprosy in ENL were studied. Grossly, the nasal cavities showed congestion, mucopurulent discharge, crusts, hypertrophy and atrophy of turbinates. A septal perforation was observed in one patient. The nasal mucosa appeared normal in four patients. All six patients with reversal reaction showed all of the above changes except for atrophy of the turbinates and septal perforation (Table 1).

Of the 14 patients in ENL, 6 of them showed microscopic evidence of edema of the nasal mucosa, and in 10 polymorphonuclear leukocytic infiltration was observed (Fig. 1). Vasculitis was seen in two patients (Fig. 2, Table 2).

Histopathological changes in the nasal mucosa, indicating reversal reaction, were

TABLE 1. Gross findings in the nasal cavities.

Nasal findings on anterior rhinoscopy	Patients with	
	ENL (N = 14)	Reversal reaction (N = 6)
Congestion of nasal mucosa	3	2
Mucopurulent discharge	4	2
Crusts in nasal cavity	4	1
Inferior turbinate hypertrophy	2	2
Atrophy of turbinates	4	0
Septal perforation	1	0
Normal appearance of nasal mucosa	4	2

present in only 2 of the 6 patients studied. There was edema with epithelioid cells in both, and poorly formed giant cells in one (Fig. 3, Table 3). Of these two patients, one had an exacerbation of existing skin lesions on the external nose and on other parts of the body; in the other patient, apparently new skin lesions appeared on different parts of the body, including the skin of the nose.

DISCUSSION

Reactions are defined as clinically apparent, acute inflammatory episodes which occur during the course of the chronic infection of humans with *Mycobacterium leprae* (3). They are noted in approximately 25% of untreated leprosy patients and in approximately 50% of leprosy patients being treated with effective chemotherapy (3). Reactions are considered to be the most frequent medical complications of leprosy and their sequelae are said to account for most of the deformity and disability (3). Recurrent crops of ENL lesions occur time and time again in areas with the highest concentration of *M. leprae*, these sites being the cooler areas of the body. Since the nasal mucosa has a temperature range from 32°C to 34.4°C, it is a favorable site for the multiplication of the leprosy bacilli (3).

On clinical examination of the nasal cavity, no elevated nodules were seen as in ENL lesions on the skin and hence the most bacillated area, the anterior ends of the interior turbinates (1) showing congestion and hypertrophy, were biopsied. Ten out of the 14 patients biopsied showed microscopic evidence of ENL. Hypertrophy of the interior turbinate may have been caused by

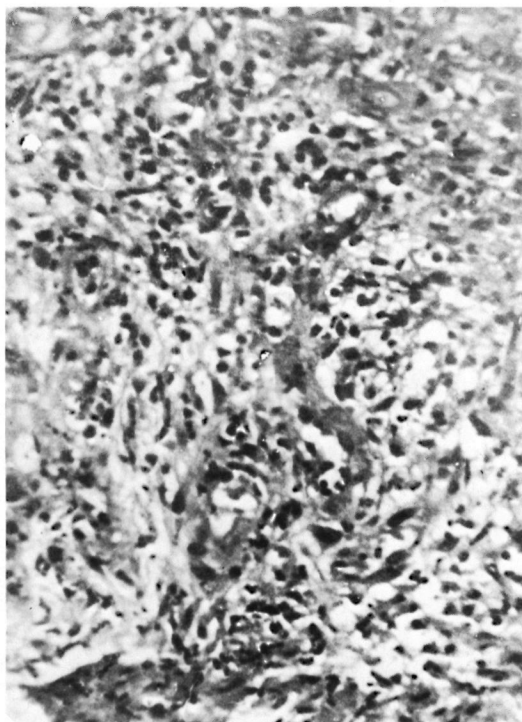


FIG. 2. Nasal mucosa showing numerous neutrophils infiltrating the tissue and a few capillaries showing vasculitis in ENL (H&E $\times 200$).

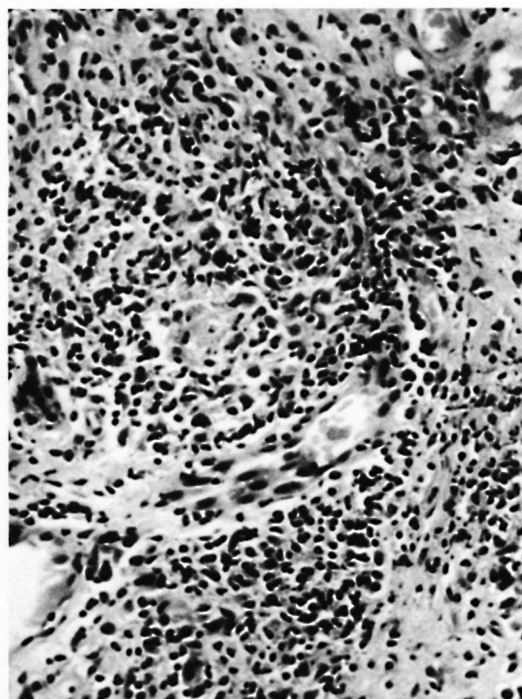


FIG. 3. Nasal mucosa showing a collection of epithelioid cells and a poorly formed giant cell (H&E $\times 200$).

an acute inflammatory reaction due to ENL. ENL with ulceration of the nasal mucosa has been reported earlier (⁵).

Reversal reactions in skin patches and nerves are well documented both clinically and histologically (^{3,9}). In this study, the histological evidence of reversal reaction is recorded for two patients, one with an up-grading reaction and the other with a down-grading reaction, both patients presenting with skin lesions on the external nose at the time of nasal biopsy. It is possible that the nasal mucosal lesions could be an extension of the skin lesions reported by earlier workers (^{8,9}).

The sequelae of reversal reaction in the skin are ulceration and scarring; in the nerves, destruction of axons and paralysis. However, in the nasal mucosa there was no obvious destruction of the mucosa or cartilage.

TABLE 2. *Microscopic findings in nasal mucosa of patients with ENL reactions.*

	Type of leprosy		Total
	Lepromatous	Borderline lepromatous	
No. patients	10	4	14
Edema	5	1	6
Polymorphonuclear leukocyte infiltration	6	4	10
Vasculitis	0	2	2

TABLE 3. *Microscopic findings in nasal mucosa of patients with reversal reactions.*

	Type of leprosy	
	Borderline lepromatous	Borderline tuberculoid
No. patients	2	0
Edema	2	—
Epithelioid cells, lymphocytes, and plasma cells	2	—
Langhan's giant cells	1	—

SUMMARY

Twenty leprosy patients in the reactive phase of the disease were studied clinically and histologically for evidence of reactive lesions in the nasal mucosa. Ten of 14 patients with erythema nodosum leprosum

(ENL) showed characteristic polymorphonuclear leukocytic infiltration and two patients showed vasculitis. The histological changes of reversal reactions in the nasal mucosa, one with upgrading reaction and the other with downgrading reaction, are reported.

RÉSUMEN

Veinte pacientes en la fase reactiva de la enfermedad se estudiaron clínica- e histológicamente para buscar evidencias de lesiones reactivas en la mucosa nasal. Diez de 14 pacientes con eritema nodoso leproso (ENL) mostraron infiltrados de leucocitos polimorfonucleares característicos y 2 pacientes mostraron vasculitis. También se describen los cambios histológicos de reacciones reversas en la mucosa nasal, una con reacción de mejoría y la otra con reacción de empeoramiento.

RÉSUMÉ

On a étudié des points de vue clinique et histologique 20 malades de la lèpre en phase réactive de la maladie, afin de mettre en évidence des lésions réactives dans la muqueuse nasale. Dix des 14 malades souffrant d'érythème noueux lépreux (ENL), ont révélé une infiltration caractéristique par des leucocytes polymorphonucléaires. En outre, deux malades présentaient une vasculite. On a observé au niveau de la muqueuse nasale de ces deux derniers malades les modifications histologiques caractéristiques de la réaction réverse, chez l'un une réaction "upgrading" et chez l'autre une réaction "downgrading."

REFERENCES

1. BARTON, R. P. E. A clinical study of the nose in lepromatous leprosy. *Lepr. Rev.* **45** (1974) 135-144.
2. CHACKO, C. J. G., BHANU, T., VICTOR, V., ALEXANDER, R., TAYLOR, P. M. and JOB, C. K. The significance of changes in the nasal mucosa in indeterminate, tuberculoid and borderline leprosy. *Lepr. India* **51** (1979) 8-22.
3. HASTINGS, R. C. Clinical aspect of leprosy—reactional episodes. In: *Proceedings of the XI International Leprosy Congress, Mexico City, November 13-18, 1978*. Latapi, F., et al., eds. Amsterdam: Excerpta Medica, 1980, pp. 85-90.
4. JOB, C. K. and CHACKO, C. J. G. A simplified 6-group classification of leprosy. *Lepr. India* **54** (1982) 26-32.
5. JOB, C. K., KARAT, A. B. A. and KARAT, S. The histopathological appearance of leprosy rhinitis and pathogenesis of septal perforation in leprosy. *J. Laryngol. Otol.* **80** (1966) 718-731.
6. JOB, C. K., KIRCHHEIMER, W. F. and SANCHEZ, R. Borderline leprosy in an experimentally infected armadillo. *Int. J. Lepr.* **50** (1982) 488-493.
7. PEDLEY, J. C. The nasal mucosa in leprosy. *Lepr. Rev.* **44** (1973) 33-35.
8. RAMU, G. and DHARMENDRA. Acute exacerbations in leprosy. In: *Leprosy Vol. I*. Dharmendra, ed. Bombay: Kothari Publishing House, 1979, pp. 108-139.
9. RIDLEY, D. S. and JOB, C. K. The pathology of leprosy. In: *Leprosy*. Hastings, R. C., ed. New York: Churchill Livingstone, 1985, pp. 100-133.