

Multiple Neurofibromatosis with Histoid Leprosy

TO THE EDITOR:

We wish to share our recent experience of histoid leprosy occurring in a patient with multiple neurofibromatosis.

A 30-year-old male was seen for multiple nodules distributed all over the body. The nodules were soft-to-firm in consistency. There were café-au-lait spots and axillary freckling compatible with a clinical diagnosis of multiple neurofibromatosis. The patient complained of impairment of sensation over the hands, feet, forearms and legs. The ulnar nerves and lateral popliteal nerves showed uniform thickening on both sides. There were no hypopigmented macules or patches. On close examination, skin-colored papules ranging in size from 2 mm to 5 mm in diameter were seen on both sides of the patient's neck (Fig. 1). Some of the papules showed central umbilication suggestive of histoid leproma, which was confirmed by skin biopsy (Fig. 2). A slit-skin smear examination from these papules showed multiple solid forms of acid-fast bacilli. The patient was treated with a daily triple-drug antileprosy regimen and is beginning to show signs of favorable response.

The occurrence of lepromatous leprosy with multiple neurofibromatosis has been reported (2). But our case of histoid leprosy occurring in association with multiple neurofibromatosis appears to be the first report, to the best of our knowledge. Students are often taught that one of the differential di-

agnoses for histoid leprosy is neurofibromatosis. It is also known that neurofibromatosis by itself can show nerve thickening (1). Therefore, we wish to highlight that it is worthwhile to undertake an astute clinical examination in all cases of multiple neurofibromatosis, particularly in endemic countries like India, to look for histoid leprosy. We also suggest that, while solitary nodules of neurofibroma are also known as molluscum fibrosum, the solitary papules and nodules of histoid leprosy may be called "molluscum leprosum."

—Jayakar Thomas, M.D.

Assistant Professor

—N.C. Wilson, M.B., B.S.

Postgraduate Student

—S. Parimalam, M.B., B.S.

Postgraduate Student

—S.M. Augustine, M.D.

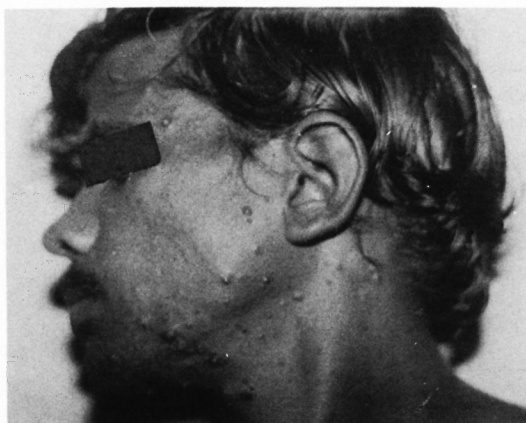

FIG. 1. Nodules of neurofibromatosis with papules of histoid leprosy are apparent on the side of the neck.

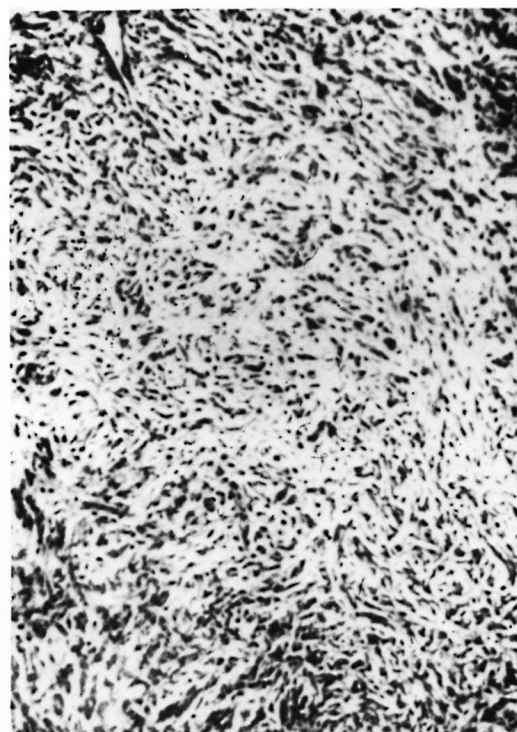


FIG. 2. Histopathology of a histoid lesion showing arrangement of spindle-shaped cells in wavy bands (hematoxylin-eosin $\times 100$).

Additional Professor

—T.C. Muthuswami, M.D.

Professor

*Department of Dermatology and Leprosy
Government General Hospital
Madras 600 003, India*

Eisen, A. Z., Wolff, K., *et al.*, eds. New York: McGraw-Hill Book Company, 1987, 3rd ed., pp. 2022–2062.

2. JOSEPH, M. S. Von Recklinghausen's disease with diffuse lepromatous leprosy—a case report. *Indian J. Lepr.* **57** (1985) 872–875.

REFERENCES

1. ADAMS, R. D. Neurocutaneous diseases. In: *Dermatology in General Medicine*. Fitzpatrick, T. B.,