

Nocardia farcinica Pleuritis in a Lepromatous Patient with Severe Necrotizing Reaction: an Unusual Presentation¹

S. Arunthathi, Gigi Ebenezer, Ebenezer Daniel, and
Samuel Thompson Sugumaran²

Lepromatous leprosy patients may be immunocompromised due to the extensive severity of the disease and due to the use of steroids and other immune suppressive drugs to treat repeated reactions. These immunocompromised patients have an increased risk of opportunistic infections. Pulmonary tuberculosis is not uncommon among leprosy patients, and some of them may be due to an immunocompromised condition. Chest infection with *Mycobacterium fortuitum* has been reported⁽²⁾. Fungal infections^(4,5) and rare viral infections⁽¹⁾ have also been reported in leprosy patients. We report here a lepromatous leprosy patient with a severe, necrotizing erythema nodosum leprosum (ENL) reaction who developed pulmonary infection with *Nocardia farcinica*, a rare bacterial opportunistic organism.

CASE REPORT

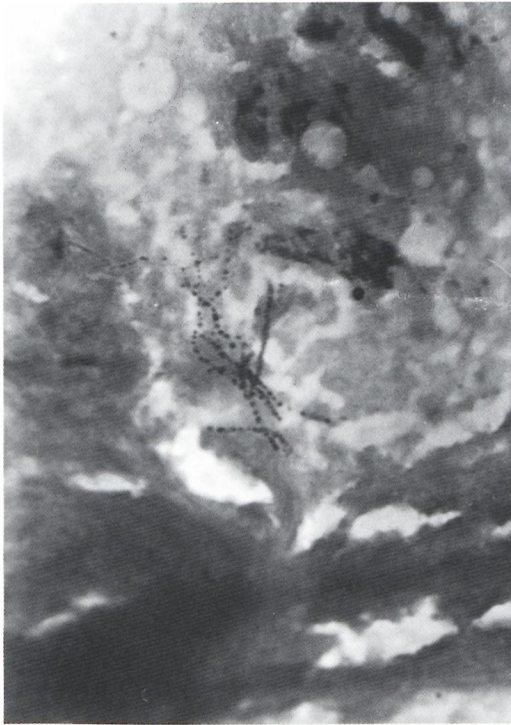
A 35-year-old male presented in August 1998 at the Schieffelin Leprosy Research and Training Center, Karigiri, India, with severe generalized body pain, fever and pustules all over the body. He had widespread, severe, necrotizing lesions with punched out ulcers all over the body, anesthesia over the right hand, and his skin smears showed an average bacterial index (BI) of 3.40+. He had been diagnosed as an LL patient and had been receiving mul-

tidrug therapy for multibacillary patients (MB-MDT) from January 1997. He developed cutaneous nodules which ulcerated frequently. This was treated with several courses of steroids and thalidomide, and 19 doses of MDT were completed but dapsone was stopped due to anemia.

The patient was admitted with a diagnosis of lepromatous leprosy with severe, necrotizing, pustular ENL. He was started on injectable Decadron (2 ml) and oral steroids (60 mg). Since his reaction was not controlled with injectable or oral steroids, thalidomide 100 mg three times daily and clofazimine 100 mg three times daily were started. The reason for the injectable steroids was to obtain a quicker response since the patient's general condition was poor. Three weeks later the patient developed sudden chest pain which was not associated with cardiac symptoms. A chest X-ray showed signs of pleural effusion. The white blood total count was 10,000 per cu mm, and the ESR was over 150 mm at 1 hr. All other investigations, including liver function tests, kidney function tests, hemoglobin and blood sugar levels, were found to be within normal limits. A pleural tap was done twice and a thick fluid was aspirated. After the last aspiration a drainage tube was inserted. The patient was started on anti-tuberculosis therapy with rifampin 450 mg, isoniazid 300 mg, and intramuscularly injected streptomycin 0.75 mg. Sputum was negative for acid-fast bacilli (AFB) on five consecutive days but the smear examination done on the pleural fluid extract showed gram-positive, thinly branched filaments (The Figure). A diagnosis of *Nocardiosis asteroides* was made. The pleural fluid sent for culture grew organisms that were diagnosed as *Nocardia*. Purified isolates of the

¹Received for publication on 20 June 2000. Accepted for publication in revised form on 16 April 2001.

²S. Arunthathi, M.D., Head, Department of Medicine; S. T. Sugumaran, M.B.B.S., D.P.M., Specialist, Department of Medicine; G. Ebenezer, M.D., Head, Department of Histopathology; E. Daniel, M.S., D.O., Head, Department of Ophthalmology, Schieffelin Leprosy Research and Training Center, Karigiri, Vellore District, Tamil Nadu, India 632 106.



THE FIGURE. Gram stain of pleural fluid showing thin beaded filaments ($\times 1000$).

organism grown on culture were sent to the Communicable Disease Center at Atlanta, Georgia, U.S.A., where they were later identified as *Nocardia farcinica*.

Improvement was interspersed with a number of setbacks. Dapsone caused anemia, for which the patient was given a blood transfusion. Due to the increased and prolonged dosage of oral and injectable steroids the patient developed gastritis. Because of this, clofazimine had to be stopped for a short duration but was added again when the patient developed an ENL reaction.

Bilateral posterior subcapsular cataract developed in both eyes as a result of the prolonged steroid therapy. In one eye a cataract extraction was done and postoperatively there was severe cystoid macular edema which had to be treated with an increased dosage of oral steroids. The other eye operated on after 7 months did not develop any postoperative complication. The patient was treated with amikacin and crystalline penicillin since the *Nocardia* species identified in the pleural aspirate was sensitive to amikacin. The patient also received

crystalline penicillin since pus from the pleural cavity grew *Actinomadura actinomycete*. Sputum culture showed heavy growth of *Pseudomonas aeruginosa* and *Candida albicans*. He also received anti-tuberculosis treatment. He completed 2 years of antileprosy treatment. His reactions gradually subsided with prolonged steroid and clofazimine treatment. He has not had any ENL reaction for the past 9 months.

DISCUSSION

The case study is of a lepromatous leprosy patient with a high bacterial load who had been started on MDT. Two months after MDT was started the patient developed ENL nodules which ulcerated frequently. The patient developed pleuritis. Steroids are known to suppress the natural immune mechanism. In such a state the patient is at risk for opportunistic infections. This case report is presented because of the diverse clinical presentations and the therapeutic dilemmas that were encountered while treating the patient. It is also of interest because of the unusual organism cultured from the pleural fluid.

The aspirated pleural fluid showed thinly filamented, branching, fragmented gram-positive organisms. Culture showed that the organisms belonged to the *Nocardia* species and the type was initially reported as *Nocardia asteroides*. Nocardiosis is an opportunistic fungal infection usually caused by infection with *N. asteroides* which is found in soil and water. It is usually found in patients with compromised cellular immunity. In this patient severe necrotizing ENL and large doses of immunosuppressive drugs must have created an environment that was conducive to the growth of *Nocardia*. Less frequently, nocardiosis is caused by infection with *N. brasiliensis* or *N. otitidiscaviarum*. Infection with other species of *Nocardia* is very rare. The fungal isolate was sent for further investigation to the Communicable Disease Center at Atlanta and was identified as *N. farcinica*. *N. farcinica* is a gram-positive, acid-fast pleomorphic bacillus associated with acute and disseminated infection. Differentiation of *N. farcinica* from the other members of the *N. asteroides* complex is important because of the high level of antibiotic resistance associated with this species. In this LL pa-

tient, it was found to be resistant to ampicillin, erythromycin, sulfamethazole-trimethoprim, cephalixin, cephalosporin and vancomycin. It was susceptible to amikacin and minocycline. *N. farcinica* is identified routinely by biochemical and antibiotic susceptibility profiles and, alternatively, may be identified as well as subspecies by ribotyping. When compared with other members of the *N. asteroides* complex isolated from clinical specimens, *N. farcinica* exhibits increased dissemination, virulence, and antibiotic resistance^(7,8)

There is also evidence of an increasing incidence of disease caused by *N. farcinica*⁽³⁾. *N. farcinica* is differentiated from other members of the *N. asteroides* complex by equal growth at 35°C and 45°C, cefotaxime resistance, acid production from L-rhamnose, and positive results for one or two additional tests (hydrolysis of acetamide or resistance to cefamandole and tobramycin). These tests may take as long as 4 weeks to complete. *N. farcinica* is also an interesting organism because it has long been known that there is serological crossreactivity between *M. leprae* and *Nocardia*⁽⁶⁾.

While he was being treated with frequent oral and injectable steroids, the patient developed other complications that are common with prolonged steroid use. The gastritis needed to be treated with an H2 receptor antagonist and because clobazimine is a known gastric irritant, this drug had to be discontinued until the gastritis subsided. The bilateral, steroid-induced cataracts which developed had to be treated with surgical removal of the lens. In the first eye which was operated on, the patient developed severe cystoid macular edema and had to be treated with oral steroids. However, the other eye, which had an intra-ocular lens implanted, remained quiet with good vision in the immediate postoperative period as well as 7 months later. The outcome of the pulmonary infection has been excellent with considerable radiological clearance. The patient's general condition has improved; he is reaction free and comes regularly for follow up.

SUMMARY

A young, male, lepromatous leprosy patient with a severe necrotizing erythema

nodosum leprosum reaction treated with prolonged oral steroids and thalidomide developed pleuritis that was caused by a rare opportunistic pathogen, *Nocardia farcinica*. This organism was resistant to most antibiotics but was susceptible to amikacin and minocycline. During the course of treatment the patient developed severe gastritis which necessitated the removal of clobazimine and the inclusion of an H2 receptor antagonist. Bilateral steroid-induced cataracts needed surgical correction. This case is being presented for its rare opportunistic bacterial infection and for the multiple complications which made treatment difficult.

RESUMEN

Un joven paciente con lepra lepromatosa, tratado con esteroides orales y talidomida debido a que presentaba una grave reacción leprosa tipo critema nodoso leproso, desarrolló pleuritis causada por *Nocardia farcinica*, un raro patógeno oportunista. Este organismo fue resistente a la mayoría de los antibióticos pero fue susceptible a la amikacina y a la monocielina. Durante el curso del tratamiento, el paciente desarrolló gastritis severa que ameritó la suspensión de la clobazimina y la inclusión de un antagonista del receptor H2. Debido al tratamiento esteroide, el paciente también desarrolló cataratas bilaterales que requirieron de tratamiento quirúrgico. Este caso se presenta por la infección con el raro microorganismo oportunista, y por las múltiples complicaciones que dificultaron el tratamiento del paciente.

RÉSUMÉ

Un jeune homme, souffrant de lèpra lépromateuse compliquée d'une sévère réaction nécrosante à type d'érythème noueux lépreux, et qui avait été traité de façon prolongée par voie orale avec des corticoïdes et la thalidomide, a développé une pleurésie provoquée par un germe opportuniste rare: *Nocardia farcinica*. Ce germe était résistant à la plupart des antibiotiques, mais était sensible à l'Amikacine et la Minocycline. Pendant le traitement, le patient a présenté une sévère gastrite, qui a motivé l'arrêt de la Clobazimine et la prescription d'un antagoniste des récepteurs histaminiques de type 2 (H2). Une cataracte bilatérale induite par les corticoïdes a dû être corrigée chirurgicalement. La présentation de ce cas clinique a été motivée par la description d'une rare surinfection bactérienne opportuniste et par l'aspect important des effets secondaires qui ont compliqué le traitement.

Acknowledgment. We acknowledge Dr. Mary Mathews, Professor of Microbiology, Christian Medical College, Vellore, India, and Dr. June Brown, Microbiologist, Centers for Disease Control and Preven-

tion, Atlanta, Georgia, U.S.A., for their contributions in identifying the organism.

REFERENCES

1. JACYK, W. K. and LECHNER, W. Epidermodysplasia verruciformis in lepromatous leprosy. Report of 2 cases. *Dermatologica* **168** (1984) 202–205.
2. KATOCH, K., KATOCH, V. M., DUTTA, A. K., SHARMA, V. D. and RAMU, G. Chest infection due to *M. fortuitum* in a case of lepromatous leprosy—a case report. *Indian J. Lepr.* **57** (1985) 399–403.
3. MCNEIL, M. M. and BROWN, J. M. The medically important aerobic actinomycetes: epidemiology and microbiology. *Clin. Microbiol. Rev.* **7** (1994) 357–417.
4. MEYERS, W. M., DOOLEY, J. R. and KWON-CHUNG, K. J. Mycotic granuloma caused by *Phialophora repens*. *Am. J. Clin. Pathol.* **64** (1975) 549–555.
5. PAVITHRAN, K. Chromoblastomycosis in a residual patch of leprosy. *Indian J. Lepr.* **60** (1988) 444–447.
6. RIDELL, M. Crossreactivity between *Mycobacterium leprae* and various actinomycetes and related organisms. *Int. J. Lepr.* **51** (1983) 185–190.
7. WALLACE, R. J., JR., BROWN, B. A., BROWN, J. M. and MCNEIL, M. M. Taxonomy of *Nocardia* species. *Clin. Infect. Dis.* **18** (1994) 476–477.
8. WALLACE, R. J., JR., STEELE, L. C., SUMTER, G. and SMITH, J.-M. Antimicrobial susceptibility patterns of *Nocardia asteroides*. *Antimicrob. Agents Chemother.* **32** (1988) 1776–1779.