

INTERNATIONAL JOURNAL OF LEPROSY

and Other Mycobacterial Diseases

VOLUME 70, NUMBER 2

JUNE 2002

MR Imaging of Neuropathic Feet in Leprosy Patients With Suspected Osteomyelitis¹

Mario Maas, Erik J. Slim, Agnes F. Heeksma, Ad J. van der Kleij,
Erik M. Akkerman, Gerard J. den Heeten, and William R. Faber²

The invasion by *Mycobacterium leprae* of Schwann cells with the resulting peripheral nerve damage can lead to a so-called neuropathic foot. Ulceration and infection (cellulitis or osteomyelitis) are important complications. Repeated injury secondary to the neuropathy may lead to tarsal disintegration with osteolysis, fragmentation and progressive bone resorption. In extreme cases, dissolution of the mid-foot results in separation of the forefoot and the hindfoot, changing all biomechanics and weight bearing areas (^{1, 11, 12, 22}). The neuro-osteoarthropathy in the foot is a cause of considerable morbidity in leprosy (^{9, 12, 22, 26}). Therefore, when a patient with a neuropathic foot presents himself with a warm foot, it is a clinical

challenge to discriminate between neuro-osteoarthropathy and an ongoing osteomyelitis. Especially, this is difficult in the presence of an ulcer, because an ulcer itself leads to increased local temperature (^{10, 22}).

Various diagnostic modalities have been investigated in the analysis of osteomyelitis in neuropathic feet (^{5, 13, 24, 28}). Magnetic Resonance Imaging (MRI) has been described as an important modality to assess osteomyelitis in the neuropathic foot of diabetic patients (^{16, 18, 19, 20, 27}). Tissue characterization and spatial resolution facilitate identification of associated soft tissue pathology (^{2, 3, 4, 16, 30}). To detect subtle bone marrow pathology, such as a low-grade chronic infection, it is mandatory to use fat-suppression sequences with the use of contrast administration (^{19, 20, 21}). A homogeneous fat-suppression in the entire field of view, both before and after intravenous contrast material (Gadolinium-chelate [Gd]), is required to avoid artifacts and misreading (²³). This can adequately be achieved by the use of Two Point Dixon Chemical Shift Imaging (TPDCSI) (^{14, 19}).

The radiological literature available on MRI and osteomyelitis in neuropathic feet nearly exclusively concerns diabetic foot pathology, being the most frequent cause of neuropathic feet in the western world.

¹ Received for publication on 8 March 2002. Accepted for publication on 13 May 2002.

² Mario Maas, M.D.; Erik J. Slim, M.D.; Erik M. Akkerman, Ph.D., and Gerard J. den Heeten, M.D., Department of Radiology, Suite G1-231; William R. Faber, M.D., Department of Dermatology; and Ad J. van der Kleij, M.D., Department of Surgery, Academic Medical Center, Meibergdreef 9, 1105 AZ Amsterdam Zuidoost, The Netherlands. Erik J. Slim, M.D. and Agnes F. Heeksma, M.D., Department of Rehabilitation, Jan van Breemen Institute, Amsterdam, The Netherlands.

Reprint requests to Dr. M. Maas, at above address. Telephone: 31-20-5668698; FAX: 31-20-5669119; or e-mail: m.maas@amc.uva.nl

However, leprosy is an important cause of neuropathic feet worldwide. According to the latest World Health Organization (WHO) information at the end of 2000, 597,232 cases were on treatment, and 719,330 new cases were reported (²⁹).

Literature concerning MRI and leprosy is scarce. Recently, an MRI study of neuropathic leprosy feet without clinical signs of inflammation was published (¹⁵). As far as we know, no papers concerning the use of MRI in neuropathic leprosy feet, clinically suspected of osteomyelitis, exist. In this paper we present our results with MRI in leprosy patients with neuropathic feet clinically suspected of having osteomyelitis. The purpose of this study was to analyze the value of MRI in diagnosing osteomyelitis as a single diagnostic procedure. The MRI findings are compared to the signs described in literature for evaluating osteomyelitis. These MRI results were compared to the gold standard (bone biopsy or bone culture) or, when no gold standard was available, the MRI results were compared to the clinical outcome after 6 months.

MATERIALS AND METHODS

Patients. We retrospectively evaluated all consecutive MRI studies, following the Dixon protocol (see later) of the foot in leprosy patients performed in the period 1994–2000. All patients had long-standing neuropathic foot pathology and were clinically suspected of having inflammation; they had a neuropathic warm, swollen foot that did not respond to conservative weight reduction therapy. A neuropathic foot was defined as a foot in which one or more of the neuronal functions, i.e., sensory, motor function or autonomic functions, was disturbed (consensus of the Dutch Neuropathic Foot Society) (⁷). Furthermore, the clinical follow up had to cover a period of 6 months.

Clinical criteria. Patient charts were reviewed for clinical information concerning leprosy classification (²⁵), presence and location of an ulcer and clinical signs of inflammation. Twelve patients with neuropathic feet clinically suspected of having osteomyelitis were investigated, and 19 MRI studies were performed. The patients were classified as borderline lepromatous ($n = 3$), borderline tuberculoid ($n = 1$), and at the lepromatous side of the spectrum ($n = 8$).

TABLE 1. Results of clinical follow-up in diagnosing osteomyelitis.

Event	Gold standard	Clinical outcome
1		Pos
2		Pos
3	Pos	
4	Pos	
5	Pos	
6		Pos
7		Pos
8		Pos
9	Pos	
10		Pos
11	Pos	
12	Pos	
13		Neg
14		Pos
15		Neg
16	Pos	
17	Pos	
18		Pos

The gold standard for the diagnosis of osteomyelitis was a positive culture and/or histopathology taken from bone material. Clinical outcome after a 6-month follow-up was retrospectively evaluated in cases where histopathology or culture was not available or not conclusive. A combination of clinical criteria was evaluated in a consensus reading by a dermatologist (WRF), a physiatrist (AFH) and a surgeon (AjvdK). The clinical criteria evaluated were the response on antibiotic treatment, the nature of the surgical treatment when performed, the persistent signs of inflammation, the status of the ulcer, and the change in deformity.

Diagnostic criteria (MRI). A total number of 24 MRI studies in 12 adult leprosy patients (9 male, 3 female; mean age 63 years, age range 45 years–81 years) were included for evaluation. Of these 24 MRI studies, 18 were performed because of clinical suspicion of osteomyelitis. Follow-up MRIs were performed in 6 patients.

MRI. MRI examination was performed using a 1.5 Tesla Vision (Siemens, Erlangen, Germany). All MRI studies were performed following the Dixon protocol (^{6, 14, 15}). This protocol consisted of: Sagittal Turbo-STIR (short tau inversion recovery) (3 mm), T1-weighted Dixon sequence with in- and opposed-phase images, sagittal dual echo T2-Weighted FSE (Fast Spin Echo) (3 mm); after the intravenous administration of

TABLE 2. Primary MRI signs: number of positive findings on various MRI sequences.

Positive primary sign	Number (%) of MRIs
T1	16 (88.9%)
T2	13 (72.2%)
STIR	13 (72.2%)
Contrast	17 (94.4%)

Gadolinium chelate (0.1 mmol/kg of body weight) T1-weighted Dixon sequence with in- and opposed-phase images (^{6, 14, 15}).

To evaluate the MRI studies, signs were used as described in literature concerning diabetic neuropathic feet (^{16, 19, 20, 27}). Typical, primary MRI signs are decreased marrow signal intensity on T1-weighted images, increased signal intensity on fat suppressed T2-weighted and/or fast STIR images, and focal marrow enhancement after gadolinium-enhanced fat-suppressed T1-weighted images (^{14, 17, 20, 21, 28}). Secondary MRI signs are: the presence of a cutaneous ulcer, cellulitis, a soft tissue mass, a soft tissue abscess, a sinus tract, and cortical interruption (^{21, 30}). One musculoskeletal radiologist (MM) retrospectively evaluated the images blinded to all clinical information except the knowledge of clinical suspicion for osteomyelitis. The signal intensity of the bone marrow on T1-weighted in and out of phase Dixon images, fast STIR images and gadolinium enhanced T1-weighted in and out of phase Dixon images (primary signs) was classified as normal or abnormal on a data collecting form. The secondary signs were classified as present or absent. Furthermore, the site of involvement was noted (medial arch, central compartment or lateral arch) (^{8, 12}).

RESULTS

Clinical findings. In 8 patients there was one event of suspected osteomyelitis. In four patients there were multiple events of suspected osteomyelitis; in three patients there were two events of suspected osteomyelitis, and in one patient there were four events of suspected osteomyelitis. The foot of involvement was 6 times for the right and 12 times for the left. The location of the ulcer was at the lateral side 14 times, at the medial side two times, and an ulcer

TABLE 3. Presence of positive secondary MRI signs.

Positive secondary sign	Number (%) of MRIs
Cellulitis	18 (100%)
Ulcer	18 (100%)
Cortical interruption	17 (88.9%)
Sinus tract	5 (27.7%)
Soft tissue abscess	3 (16.6%)
Soft tissue mass	2 (11.1%)

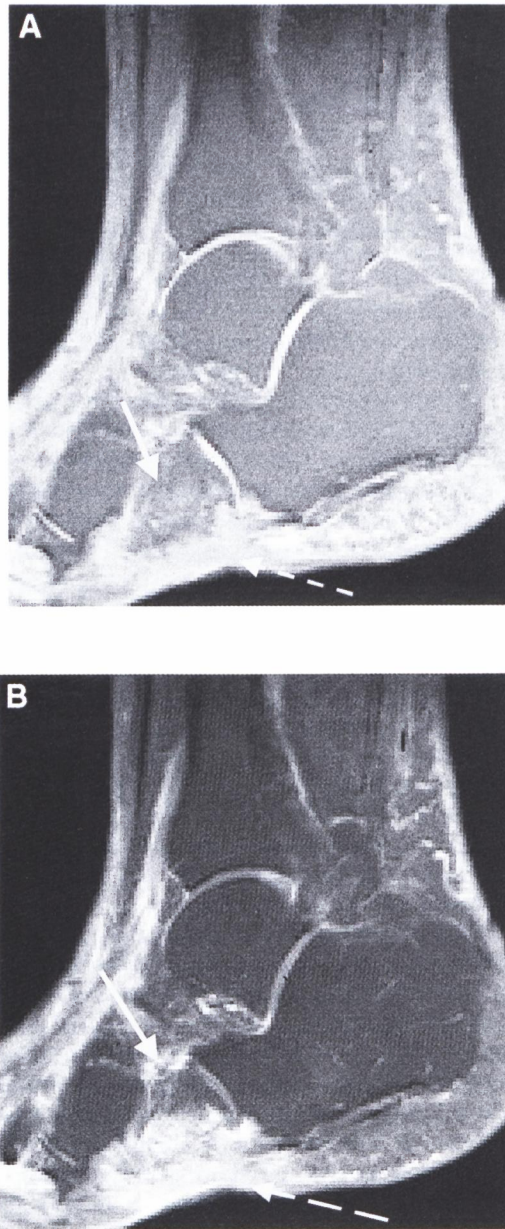
was present at the medial and lateral side two times.

The results of the gold standard are listed in Table 1. When evaluating results from a bone biopsy or bone culture and/or preset clinical criteria, without detailed knowledge of the MRI results, the diagnosis of osteomyelitis was made in 16 of 18 events (88.9%).

Diagnostic findings (MRI). In 18 events of suspected osteomyelitis we encountered 17 MRI examinations which were positive for primary MRI signs of osteomyelitis (94.4%), decreased signal on T1 in and out of phase on 16 MRIs (88.9%), increased signal on T2 on 13 MRIs (72.2%), fast SE STIR on 13 MRIs (72.2%), and focalized marrow enhancement after gadolinium-enhanced, fat-suppressed T1 on 17 MRI (94.4%) (Table 2).

The secondary signs were positive in all MRI examinations (100%). Cellulitis was present in all cases (100%). A cutaneous ulcer in the region of the suspected osteomyelitis was also present in all cases (100%). Cortical interruption was found in 16 investigations (88.9%). A sinus tract was present in 5 cases (27.7%). A soft tissue abscess was present in 3 cases (16.6%). A soft tissue mass was found on two occasions (11.1%) (Table 3). An example of positive primary signs and secondary signs at the lateral side of the foot is shown in The Figure.

The sites of involvement (MRI). The medial-central-lateral sites of involvement were also analyzed. The areas of osteomyelitis were located at the medial site (MTP1 joint, os metatarsal 1, cuneiform 1, navicular bone) in 3 events, the medial/central in 2 events, the central (MTP 2–3, os metatarsal 2–4) in 3 events, and the lateral (MTP 4–5 joint, os metatarsal 4–5, cuboid, calcaneus) in 9 events. In one patient all three areas were involved.



THE FIGURE. **A** = Two point Dixon fat suppression image of the right foot of a 79-year-old female patient. Note the degradation of the plantar fat with the presence of soft tissue edema (interrupted arrow) and the high signal intensity in the partly destroyed cuboid bone (non-interrupted arrow). **B** = Same patient after intravenous gadolinium chelate administration. Note the marked enhancement at the lateral side of the foot both in the soft tissue (cellulitis) (interrupted arrow) and in the cuboid bone (osteomyelitis) (non-interrupted arrow).

Follow up (MRI). Six follow-up MRIs were made after antibiotic treatment. The mean time of follow up was five months. A complete healing of the ulcer occurred in two patients with a normal follow-up MRI. Two patients had an improved but still abnormal MRI. The MRI changes that were seen were a reduction, but still present zone of enhancement of the bone marrow. Both patients eventually showed a complete clinical remission. The foot of the patient that showed an unchanged follow-up MRI despite continued antibiotics eventually was amputated.

DISCUSSION

Osteomyelitis is a well-known complication in patients with neuropathic foot pathology^(4, 13, 16, 19, 20, 24, 26, 28, 30). These patients may develop ulcers that persist over a long period of time. In this way spread of infection *per continuitatem* can cause an infection of the osseous structures in the foot. Clinical examination lacks specificity in this patient group, since by clinical examination alone it is difficult to differentiate between cellulitis, osteomyelitis and neuro-osteoarthropathy^(22, 26). MR imaging is a potentially powerful tool in the evaluation of the neuropathic foot. It is useful for the evaluation of the presence and the extent of osteomyelitis, as well as for the identification of the presence and the extent of associated soft tissue abnormalities that may have clinical importance, such as cellulitis, abscess, and sinus tract^(4, 16, 18, 19, 20, 21, 27, 30). Nearly all data available on MRI and neuropathic feet concern patients suffering from diabetes. As far as we know, this is the first report on the use of MRI as a diagnostic procedure in neuropathic leprosy feet suspected of having osteomyelitis.

When analyzing the primary MRI signs for osteomyelitis, we found that in our population that in 17 out of 18 events (94.4%) primary MRI signs were positive. A decreased signal intensity on in and out of phase T1-weighted images and the marrow enhancement after gadolinium administration on fat-suppressed T1 were the most frequently encountered abnormalities. In our retrospective analysis (gold standard and/or clinical outcome), 16 out of 18 events were diagnosed as positive for osteomyelitis. Comparing this evaluation with

the primary MRI signs, there was agreement in 17 out of 18 events. The disagreement found in one patient was caused by the primary MRI sign of focal marrow enhancement after contrast administration. Therefore, we conclude that these primary signs, used in evaluating MRI examinations in diabetics, can adequately be used to analyze MRI examinations in leprosy patients with long-standing complicated neuropathic feet.

Of the secondary MRI signs, ulcer and cellulitis were present in all cases. The areas on each MRI suspected of osteomyelitis were in continuity with the ulcer. The relation between ulcer and osteomyelitis has also been described in diabetes (⁵). In contrast to diabetic feet only a minority of examinations revealed a sinus tract or soft tissue abscess in our population (²¹). It seems that these latter secondary signs are infrequently found in leprosy. However, the presence of an ulcer and cellulitis is common in leprosy patients with long-standing neuropathic feet suspected of having osteomyelitis. Contrary to diabetic foot literature, the secondary MRI signs seem to have no additional value in diagnosing osteomyelitis in a population of leprosy patients with long-standing neuropathic foot disease. However, the value of these findings in a patient population of leprosy patients with neuropathy and clinical suspicion of inflammation, without long-standing disease, was not evaluated in this study. For this purpose a study is currently being conducted.

The present study demonstrates in 9 events MRI changes suspected of having osteomyelitis were seen on the lateral side only (50%). In a minority of events these changes were found on the medial side only (16.7%). This is in contrast to the results found in a recent study of asymptomatic neuropathic feet in leprosy patients in which 90 percent of the MRI changes were located on the medial side of the foot (¹⁵). Most likely the biomechanics in the two patient groups (clinically-unsuspected versus clinically-suspected in long-standing neuropathic foot disease) are different. Biomechanical analysis in early tarsal disintegration shows the highest stress to occur during the push-off phase in the bones of the lateral foot arch (¹²). Perhaps this is caused by inversion due to paralysis of the lateral

musculature. An analysis of the walking cycle in two groups of leprosy patients with neuropathic feet, with and without clinical abnormalities, may be of additional value in order to analyze the stress distribution.

When a leprosy patient with long-standing neuropathic foot disease is suspected of osteomyelitis, clinical examination lacks specificity. Contrast-enhanced MRI with the use of Two Point Dixon Chemical Shift Imaging, as a fat-suppression technique, is a valuable technique to detect osteomyelitis. The primary MRI signs known from literature concerning the diabetic neuropathic foot can adequately be assessed. MRI can serve as a one-step diagnostic strategy to diagnose osteomyelitis in leprosy patients with a long-standing neuropathic foot problem.

SUMMARY

This study was undertaken to analyze MRI findings in leprosy patients with neuropathic feet, which are suspected of having osteomyelitis. As far as we know, there is no literature concerning osteomyelitis and MRI in neuropathic leprosy feet at present. Therefore, we have included MRI examination of 18 events of suspected osteomyelitis in 12 leprosy patients. All patients with long-standing neuropathic foot problems were clinically suspected of having osteomyelitis. All patients underwent the MRI protocol with the inclusion of Two Point Dixon Chemical Shift Imaging as a fat-suppression sequence. For the MRI evaluation, we used signs that are described in literature for detecting osteomyelitis in diabetic feet. The primary MRI signs were positive in 17 of 18 patients. The secondary MRI signs were positive in 100% of the patients.

Our results show that MRI with the use of Two Point Dixon Chemical Shift Imaging is a promising diagnostic modality to detect osteomyelitis in the presence of neuroarthropathic changes in patients with leprosy. Whenever available, MRI could play an important role in detecting osteomyelitis in leprosy patients with long-standing neuropathic feet.

RESUMEN

Este estudio se realizó con el fin de analizar los hallazgos por MRI en los pacientes con lepra y pie neurítico, sospechosos de tener osteomielitis. Hasta donde sabemos, actualmente no hay datos en la literatura

relacionados con la osteomielitis y MRI en el pie neuropático de la lepra. Por lo tanto, incluimos el examen por MRI de 18 eventos sospechosos de osteomielitis en 12 pacientes con lepra. Todos los pacientes con problemas neuropáticos del pie de larga duración se consideraron como candidatos de tener osteomielitis. Todos los pacientes se sometieron al protocolo MRI con la inclusión del análisis de Dixon de dos puntos ("Two Point Dixon Chemical Shift Imaging") como una secuencia de supresión de grasa. Para evaluar los resultados del estudio por MRI usamos los signos descritos en la literatura para detectar la osteomielitis en el pie diabético. Los signos MRI primarios fueron positivos en 17 de 18 pacientes. Los signos MRI secundarios fueron positivos en el 100% de los pacientes.

Nuestros resultados muestran que el MRI aunado al uso del análisis de Dixon de dos puntos es una modalidad diagnóstica promisoría para detectar osteomielitis cuando hay cambios neuro-osteopáticos en los pacientes con lepra. La aplicación de esta metodología, siempre que sea posible, puede jugar un papel importante en la detección de osteomielitis en los pacientes con lepra y pie neuropático de larga duración.

RÉSUMÉ

Cette étude fut entreprise dans le but d'analyser les données d'IRM obtenues chez les patients lépreux atteints de neuropathies des pieds et suspectés de souffrir d'ostéomyélite. A notre connaissance, il n'existe pas actuellement de littérature rapportant des données d'IRM sur les ostéomyélites, comme complication de neuropathies des pieds dans la lèpre. C'est pourquoi nous avons inclus un examen IRM lors de la caractérisation de 18 suspicion d'ostéomyélite concernant 12 patients hanséniens. Tous les patients souffrant de problèmes de neuropathie podale de longue durée firent l'objet d'une suspicion d'ostéomyélite. Tous les patients furent soumis à un protocole IRM, incluant une imagerie de type déplacement chimique en deux points selon Dixon ("Two Point Dixon Chemical Shift Imaging"), comme séquence de suppression du tissu adipeux. Pour l'évaluation IRM, nous avons utilisé les signes décrits dans la littérature pour détecter les ostéomyélites des pieds diabétiques. Les signes IRM principaux étaient détectés chez 17 des 18 patients étudiés. Les signes IRM secondaires étaient présents chez 100% des patients.

Nos résultats démontrent que L'IRM, avec l'utilisation de l'imagerie de type déplacement chimique de Dixon en deux points, est un outils diagnostic prometteur pour détecter une ostéomyélite en présence de signes neuro-arthrosiques chez les patients lépreux. L'application de la technologie IRM, lorsque disponible, pourrait jouer un rôle important pour détecter une ostéomyélite chez les patients atteint de la lèpre, qui souffrent depuis longtemps de neuropathies des pieds.

REFERENCES

- BRANDSMA, J. W., MACDONALD, M. R. C., WARREN, A. G., CROSS, H., SCHWARTZ, R. J., SOLOMON, S., KAZEN, R., GRAVEM, P. E. and SHRINIVASAN, H. Assessment and examination of the neurologically impaired foot. *Lepr. Rev.* **72** (2001) 263–275.
- BRASH, P. D., FOSTER, J. E., ANTHONY, P. and TOOKE, J. E. Magnetic resonance imaging techniques demonstrates soft tissue damage in the diabetic foot. *Diabet. Med.* **16** (1999) 55–61.
- BRASH, P. D., FOSTER, J. E., VENNART, W., DAW, J. and TOOKE, J. E. Magnetic resonance imaging reveals Micro-haemorrhage in the feet of diabetic patients with a history of ulceration. *Diabet. Med.* **13** (1996) 973–978.
- CRAIG, J. G., AMIN, M. B., WU, K., EYLER, W. R., VAN HOLSBEECK, M. T., BOUFFARD, J. A. and SHIRAZI, K. Osteomyelitis of the diabetic foot: MR imaging-pathologic correlation. *Radiology* **203** (1997) 849–855.
- CRIM, J. R. and SEEGER, L. I. Imaging evaluation of osteomyelitis. *Crit. Rev. Diagn. Imaging* **35** (1994) 201.
- DIXON, W. T. Simple proton spectroscopic imaging. *Radiology* **153** (1984) 189–194.
- FABER, W. R., HOEKSMAN, A. F., VAN DER KLEIJ, A. J., MAAS, M. and DIJKSTRA, P. F. Diagnostic procedures for suspected osteomyelitis in neuropathic feet of leprosy patients. *Int. J. Lepr.* **66** (1998) 29A.
- GOODWIN, D. W., SALONEN, D. C., YU, J. S., BROCHMANN, J., TRUDELL, D. J. and RESNICK, D. L. Plantar compartments of the foot: MR appearance in cadavers and diabetic patients. *Radiology* **196** (1995) 623–630.
- GUOCHENG, Z., WENZHONG, L., LIANGBIN, Y., ZHONGMIN, Y., XIANGSHENG, C., TISHENG, Z. and GANYUN, Y. An epidemiological survey of deformities and disabilities among 14,257 cases of leprosy in 11 countries. *Lepr. Rev.* **64** (1993) 143–149.
- HOEKSMAN, A. F. and FABER, W. R. Assessment of skin temperature via palpation of the neuropathic foot. 1st World Congress of International Society of Physical and Rehabilitative Medicine (ISPRM) Amsterdam, The Netherlands (2001).
- JACOB, S. and PATIL, M. K. Stress analyses in three-dimensional foot models of normal and diabetic neuropathy. *Front. Med. Biol. Eng.* **9** (1999) 211–227.
- JACOB, S. and PATIL, M. K. Three-dimensional foot modelling and analysis of stresses in normal and early stage Hansen's disease with muscle paralysis. *J. Rehabil. Res. Dev.* **36** (1999) 252–263.
- LIPMAN, B. T., COLLIER, B. D., CARRERA, G. F., TIMMINS, M. E., ERICKSON, S. J., JOHNSON, J. E., MITCHELL, J. R., HOFFMAN, R. G., FINGER, W. A., KRASNOW, A. Z. and HELLMAN, R. S. Detection of osteomyelitis in the neuropathic foot: nuclear medicine, MRI and conventional radiography. *Clin. Nucl. Med.* **23** (1998) 77–82.
- MAAS, M., DIJKSTRA, P. F. and AKKERMAN, E. M. Uniform fat suppression in hands and feet through the use of two-point Dixon chemical shift MR imaging. *Radiology* **210** (1999) 189–193.

15. MAAS, M., SLIM, E. J., AKKERMAN, E. M. and FABER, W. R. MRI in clinically asymptomatic neuropathic leprosy feet: a baseline study. *Int. J. Lepr.* **69** (2001) 219–224.
16. MARCUS, C. D., LADAM-MARCUS, V. J., LEONE, J., MALGRANGE, D., BONNET-GRAUSSERAND, F. M. and MENTANEAU, B. P. MR imaging of osteomyelitis and neuropathic osteoarthropathy in the feet of diabetics. *Radiographics* **16** (1996) 1337–1348.
17. MOORE, T. E., YUH, W. T. C., KATHOL, M. H., EL-KHOURY, G. Y. and CORSON, J. D. Abnormalities of the foot in patients with diabetes mellitus: findings on MR imaging. *AJR. Am. J. Roentgenol.* **157** (1991) 813–816.
18. MORRISON, W. B., LEDERMANN, H. P. and SCHWEITZER, M. E. MR imaging of the diabetic foot. *Magn. Reson. Imaging Clin. N. Am.* **9** (2001) 606–613.
19. MORRISON, W. B., LEDERMANN, H. P. and SCHWEITZER, M. E. MR imaging of inflammatory conditions of the ankle and foot. *Magn. Reson. Imaging Clin. N. Am.* **9** (2001) 615–637.
20. MORRISON, W. B., SCHWEITZER, M. E., BOCK, G. W., MITCHELL, D. G., HUME, E. L., PATHRIA, M. N. and RESNICK, D. Diagnosis of osteomyelitis: utility of fat-suppressed contrast-enhanced MR imaging. *Radiology* **189** (1993) 251–257.
21. MORRISON, W. B., SCHWEITZER, M. E., GRANVILLE BATTE, W., RADACK, D. P. and RUSSEL, K. M. Osteomyelitis of the foot: relative importance of primary and secondary MR imaging signs. *Radiology* **207** (1998) 625–632.
22. ONVLEE, G. J. The Charcot Foot: a critical review and observational study of a group of 60 patients, thesis 1998.
23. PETERFY, C. G., LINARES, R. and STEINBACH, L. S. Recent advances in magnetic resonance imaging of the musculoskeletal system. *Radiol. Clin. North Am.* **32** (1994) 291–311 .
24. RESNICK, D. and NIWAYAMA, G. Osteomyelitis, septic arthritis and soft tissue infection: Organisms. In: *Diagnosis of bone and joint disorders*. 3rd ed. Philadelphia: W. B. Saunders Company, 1995, pp. 2486–2492.
25. RIDLEY, D. S. and JOPLING, W. H. Classification of leprosy according to immunity. A five-group system. *Int. J. Lepr.* **34** (1966) 255–273.
26. SCHON, L. C., EASLEY, M. E. and WEINFELD, S. B. Charcot neuroarthropathy of the foot and ankle. *Clin. Orthop.* **349** (1998) 116–131.
27. TEHRANZADEH, J., WONG, E., WANG, F. and SADIGHPOUR, M. Imaging of osteomyelitis in the mature skeleton. *Magn. Reson. Imaging Clin. N. Am.* **39** (2001) 240–250.
28. TOMAS, M. B., PATEL, M., MARWIN, S. E. and PALESTRO, C. J. The diabetic foot. *Brit. J. Radiol.* **73** (2000) 443–450.
29. WORLD HEALTH ORGANIZATION. Weekly Epidemiological Record (WER), **77**(1) (2002) 1–8. <http://www.who.int/wer>
30. YU, J. S. Diabetic foot and neuroarthropathy magnetic resonance imaging evaluation. *Top. Magn. Reson. Imaging* **9** (1998) 295–230.